



PATIENT

Noodles Kirby

SPECIES

Canine

BREED

Pug x

SEX

Spayed Female

AGE

14 Years

WEIGHT

6.6 kg

INTERPRETED BY

Kathleen Sennello DVM,
 MS, Diplomate ACVIM
 (Small Animal Internal
 Medicine)

IMAGING PERFORMED BY

Kelly Reschny

HOSPITAL NAME

Downtown Animal
 Hospital

REFERRING VET

Dr. Ahn

INVOICE

73086

DATE

2/19/26

PRESENTING CLINICAL SIGNS

This ultrasound is to monitor for ongoing GI issues: chronic pancreatitis, chronic intermittent vomiting. Previous ultrasound in Sept 2025, ongoing monitoring recommended for: a hypoechoic nodule in liver, moderate gallbladder debris, age related changes to kidneys, pancreatic changes consistent with mild pancreatitis, mild thickening of small intestines, prominent/mildly inflamed area of colon

Current Medications: Cerenia 6mg PO q24h; probiotic powder

Abnormal PE/Chem/CBC/UA Results: Last blood work was done in March 2025 - all results wnl prev US report attached

ULTRASONOGRAPHIC EXAMINATION OF THE ABDOMEN

Urinary System

The urinary bladder is moderately distended with anechoic urine. The Bladder wall largely appears of normal thickness with a smooth mucosal surface. The apical region appears somewhat prominent and more thickened, measuring at 0.64 cm. The region of the trigone, ureteral papillae and proximal urethra appear free of any mass lesions or calculi.

The left kidney has a normal shape and size (4.41 cm). Overall echogenicity is slightly hyperechoic with mildly corticomedullary distinction and a typical 1:3 cortex:medulla ratio. There is no evidence of focal perinephric inflammation or effusion. There is no evidence of pyelectasia, nephroliths, infarcts or hydroureter. Renal vasculature is normal.

The right kidney has a normal shape and size (3.88 cm). Overall echogenicity is slightly hyperechoic with mildly reduced corticomedullary distinction and a typical 1:3 cortex:medulla ratio. There is no evidence of focal perinephric inflammation or effusion. There is no evidence of pyelectasia, nephroliths, infarcts or hydroureter. Renal vasculature is normal.

Adrenal Glands

The left adrenal gland is normal in size measuring 0.48 cm at the cranial pole and 0.49 cm at the caudal pole. It is observed in its normal position cranial to the left renal artery. It is normal in appearance (uniformly hypoechoic) and shape with no evidence of a mass effect.

The right adrenal gland is normal in size measuring 1.05 cm at the cranial pole and 0.77 cm at the caudal pole. It is observed in its normal position between the cranial aspect of the right kidney and the caudal vena cava. It is normal in appearance (uniformly hypoechoic) and shape with no evidence of a mass effect.

Spleen

The spleen is subjectively normal in size (1.19 cm), echotexture is homogenous, and the splenic capsule is smooth with no irregularities. The blood flow through the hilus and splenic parenchyma appears normal. No focal parenchymal abnormalities are visualized.



PATIENT

Noodles Kirby

SPECIES

Canine

BREED

Pug x

SEX

Spayed Female

AGE

14 Years

WEIGHT

6.6 kg

INTERPRETED BY

Kathleen Sennello DVM,
 MS, Diplomate ACVIM
 (Small Animal Internal
 Medicine)

IMAGING PERFORMED BY

Kelly Reschny

HOSPITAL NAME

Downtown Animal
 Hospital

REFERRING VET

Dr. Ahn

INVOICE

73086

DATE

2/19/26

Liver

The liver is subjectively normal in size, and echogenicity with smooth peripheral margins. The parenchyma is homogenous echotexture. The visible portions of the vasculature and biliary tract appear normal. The previously described hypoechoic nodule is visualized measuring .69X 1.1cm-previous measurement .7 X1.01cm. This appears stable.

The gall bladder lumen is moderately distended. The wall of the gall bladder is not thickened and has a smooth mucosal surface. There is a moderate amount of non-organized echogenic debris. The cystic and common bile ducts are normal/not visible.

Gastrointestinal

The stomach contains mild fluid/gas. It measures at a normal thickness of <0.7cm with some variability due to the presence of rugal folds. The distinction of the gastric wall layers is adequate and there is no impression of reduced peristaltic activity. On one view of the stomach the gastric wall appears irregular/prominent measuring 1.38cm-this is not repeatable on following views.

The visualized areas of duodenum, jejunum and ileum have a uniform diameter with minimal fluid distension. Wall appears subjectively, mildly increased. Bowel loops follow a typical curvilinear path with distinct wall layering. Duodenum wall measures 0.50 cm. Jejunum wall measures 0.37 cm. Visualized peristalsis appears appropriate. The duodenum appears segmentally corrugated and thickened.

Sections of colon are visualized with formed fecal material and gas shadowing distally. There is no observed focal or generalized colon wall thickening or loss of layering.

Pancreas

The pancreas is prominent and mottled compared to the surrounding isoechoic mesentery. There is no evidence of nodules or cystic lesions. There is no evidence of regional mesenteric inflammation or fluid.

Free Abdomen

Evaluation of the peritoneal cavity did not reveal any evidence of effusion, or subjective lymphadenomegaly. The Medial iliac nodes appear normal and there was no evidence of a caudal aortic thrombus at the bifurcation. The omentum is of normal uniform echogenicity.

PRIMARY FINDINGS

- Visible/mildly mottled pancreas – Findings are most consistent with chronic pancreatic remodeling +/- mild pancreatitis.
- Moderate gallbladder debris – The significance of the aggregated gallbladder debris is unclear. This could represent an early mucocele, cholestasis, or may be secondary to fasting but seems unlikely to be causing a current issue. Recommend continued monitoring.
- Thickened small intestine with some areas exhibiting mild fluid/gas distention/corrugation – The small intestinal wall changes are most consistent with an inflammatory process (e.g., inflammatory bowel disease). An early neoplastic process is less likely.
- Stable hypoechoic liver nodule- lack of rapid growth favors a benign/less aggressive process.



PATIENT

Sampling or continued monitoring is recommended

Noodles Kirby

- Thickened area of gastric wall-this is not repeatable on all views- differentials include imaging artifact, focal gastritis or an early neoplastic lesion.

SPECIES

Canine

SECONDARY FINDINGS

BREED

Pug x

- Mildly thickened apical wall of the urinary bladder – The bladder mucosal changes could be consistent with cystitis or artifactual due to lack of adequate luminal distension. Bladder neoplasia cannot be ruled out but is considered unlikely in this patient.

SEX

Spayed Female

- Age related changes visualized associated with both kidneys.

INTERPRETATION OF THE FINDINGS & FURTHER RECOMMENDATIONS

AGE

14 Years

The pancreas is mildly prominent and mottled. Findings could be consistent with mild pancreatic remodeling +/- mild pancreatitis. Consider measuring PLI level and empirical treatment for pancreatitis.

WEIGHT

6.6 kg

The small intestine appears prominent/thickened, and there is some fluid and gas in the stomach and questionable focal gastric wall thickening. Initial evaluation/empirical therapy could include the following:

INTERPRETED BY

Kathleen Sennello DVM,
 MS, Diplomate ACVIM
 (Small Animal Internal
 Medicine)

- Consider a novel protein/hydrolyzed protein diet (exclusively at least 4-6 weeks)
- Consider a GI panel to Texas A&M for evaluation of B12 levels, folate, PLI/TLI etc.. to further evaluate for pancreatic/small intestinal disease.
- Recommend chronic probiotic therapy.

IMAGING PERFORMED BY

Kelly Reschny

If these steps have been taken and symptoms are persistent biopsies of the GI tract and stomach may be of benefit for further evaluation. If this is not pursued re-evaluation with ultrasound in 3-4 months (sooner if concerned) could be considered.

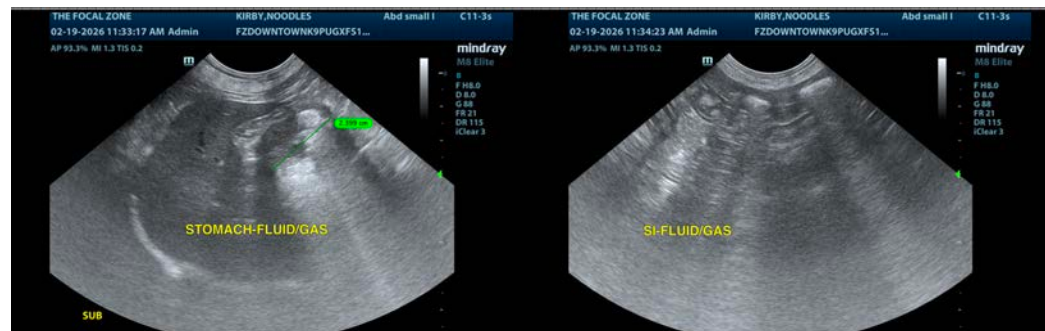
HOSPITAL NAME

Downtown Animal
 Hospital

The hypochoic nodule in the liver is persistent but stable. Options include a fine needle aspirate or continued monitoring.

REFERRING VET

Dr. Ahn



INVOICE

73086

DATE

2/19/26



PATIENT

Noodles Kirby

SPECIES

Canine

BREED

Pug x

SEX

Spayed Female

AGE

14 Years

WEIGHT

6.6 kg

INTERPRETED BY

Kathleen Sennello DVM,
 MS, Diplomate ACVIM
 (Small Animal Internal
 Medicine)

**IMAGING
 PERFORMED BY**

Kelly Reschny

HOSPITAL NAME

Downtown Animal
 Hospital

REFERRING VET

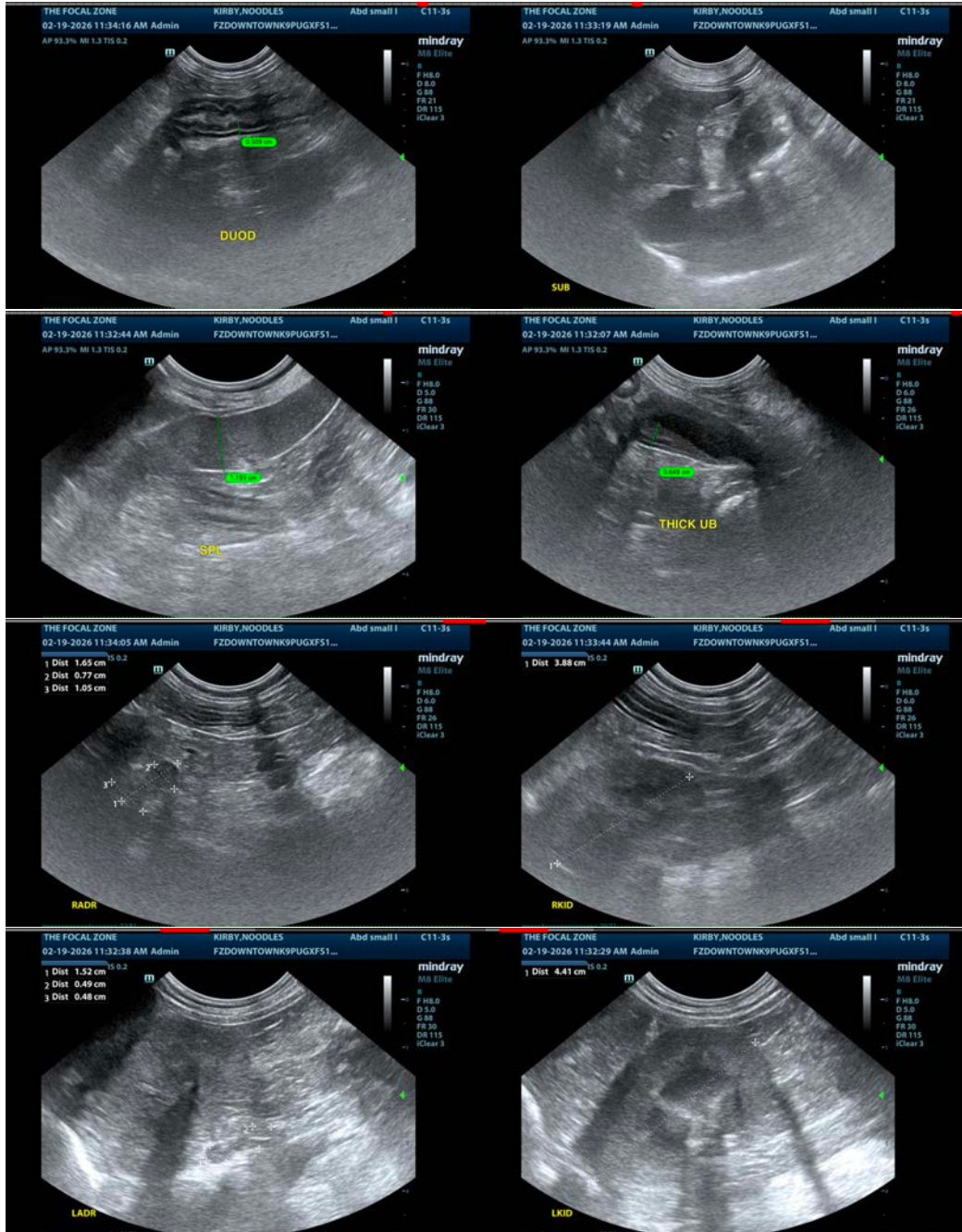
Dr. Ahn

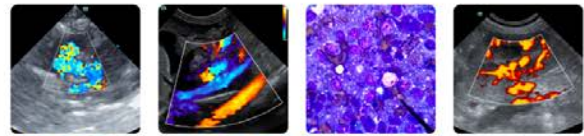
INVOICE

73086

DATE

2/19/26





PATIENT

Noodles Kirby

SPECIES

Canine

BREED

Pug x

SEX

Spayed Female

AGE

14 Years

WEIGHT

6.6 kg

INTERPRETED BY

Kathleen Sennello DVM,
 MS, Diplomate ACVIM
 (Small Animal Internal
 Medicine)

**IMAGING
 PERFORMED BY**

Kelly Reschny

HOSPITAL NAME

Downtown Animal
 Hospital

REFERRING VET

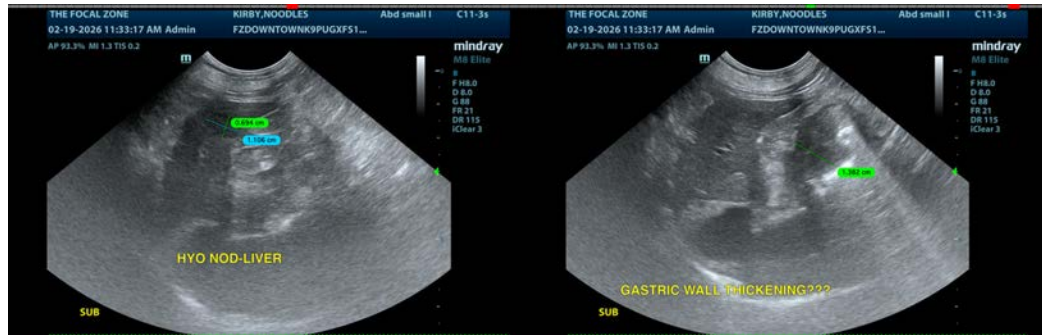
Dr. Ahn

INVOICE

73086

DATE

2/19/26



The information and recommendations provided are based on the images presented by the referring veterinarian/sonographer. No evaluation can be communicated regarding pathology that was not visible in the image/video clips provided.

Thank you for this referral. If the clinical or image interpretation does not parallel your findings or if I can be of any further assistance please contact me.

Kathleen Sennello DVM,MS, Diplomate ACVIM (Small animal Internal Medicine)

info@sonopath.com