



**PATIENT**

Roscoe Ledford

**SPECIES**

Canine

**BREED**

Pomeranian x

**SEX**

Neutered Male

**AGE**

16 Years

**WEIGHT**

23.8 lbs

**INTERPRETED BY**

Kathleen Sennello DVM,  
 MS, Diplomate ACVIM  
 (Small Animal Internal  
 Medicine)

**IMAGING PERFORMED BY**

Kathleen Byrnes

**HOSPITAL NAME**

Stewart's Mountain  
 Animal Hospital

**REFERRING VET**

Dr. Stewart

**INVOICE**

73038

**DATE**

2/18/26

**PRESENTING CLINICAL SIGNS**

P presented for ultrasound due to chronic elevation in liver enzymes. No improvement on Denamarin. P is not clinical and doing well.

Abnormal PE/Chem/CBC/UA Results: ALT 154, ALKP 1139, usg 1.033

**ULTRASONOGRAPHIC EXAMINATION OF THE ABDOMEN**

**Urinary System**

The urinary bladder is moderately distended with anechoic urine. The Bladder wall appears of normal thickness with a smooth mucosal surface. In the dependent portion of the urinary bladder there is focal shadowing debris most consistent with dependent sandy/mineralized debris.

The prostate is normal in size (0.94 cm) and shape for this neutered male dog. The parenchyma is homogenous and the external margins are smooth. The prostatic urethra appears normal with no evidence of irregularity, invasion, mass effect or calculi.

The left kidney has a normal shape and size (4.61 cm) with pinpoint non-obstructive cortical mineralizations. Overall echogenicity is slightly hyperechoic with poor corticomedullary distinction and a typical 1:3 cortex:medulla ratio. There is no evidence of focal perinephric inflammation or effusion. There is no evidence of pyelectasia, infarcts or hydroureter. Renal vasculature is normal.

The right kidney has a normal shape and size (5.43 cm) with pinpoint non-obstructive cortical mineralizations. Overall echogenicity is slightly hyperechoic with poor corticomedullary distinction and a typical 1:3 cortex:medulla ratio. There is no evidence of focal perinephric inflammation or effusion. There is no evidence of pyelectasia, infarcts or hydroureter. Renal vasculature is normal.

**Adrenal Glands**

The left adrenal gland is normal in size measuring 0.53 cm at the cranial pole and 0.54 cm at the caudal pole. It is observed in its normal position cranial to the left renal artery. It is normal in appearance (uniformly hypoechoic) and shape with no evidence of a mass effect.

The right adrenal gland is normal in size measuring 0.55 cm at the cranial pole and 0.62 cm at the caudal pole. It is observed in its normal position between the cranial aspect of the right kidney and the caudal vena cava. It is normal in appearance (uniformly hypoechoic) and shape with no evidence of a mass effect.

**Spleen**

The spleen is subjectively normal in size (1.34 cm), echotexture is homogenous, and the splenic capsule is smooth with no irregularities. The blood flow through the hilus and splenic parenchyma appears normal. No focal parenchymal abnormalities are visualized.

**Liver**

The liver is large in size, and normal in echogenicity with smooth peripheral margins. The parenchyma is heterogenous in echotexture with subtle, indistinct focal mottling. The visible portions of the vasculature and biliary tract appear normal. No focal nodules or cystic lesions are observed.



**PATIENT**

Roscoe Ledford

The gall bladder lumen is moderately distended. The wall of the gall bladder is not thickened and has a smooth mucosal surface. There is a moderate amount of non-organized echogenic debris. The cystic and common bile ducts are normal/not visible.

**SPECIES**

Canine

**Gastrointestinal**

The stomach contains mild fluid and shadowing ingesta. It measures at a normal thickness of <0.7cm with some variability due to the presence of rugal folds. The distinction of the gastric wall layers is adequate and there is no impression of reduced peristaltic activity. No masses or focal lesions were observed.

**BREED**

Pomeranian x

The visualized areas of duodenum, jejunum and ileum have a relatively uniform diameter with minimal fluid distension. Wall thickness is normal. Bowel loops follow a curvilinear path with distinct wall layering maintaining the typical 1:3 muscularis:mucosa layer ratio. Duodenum wall measures 0.42 cm. Jejunum wall measures 0.31 cm. Visualized peristalsis appears appropriate. There were no focal lesions consistent with obstruction or a mass effect observed.

**SEX**

Neutered Male

**AGE**

16 Years

Sections of colon are visualized with formed fecal material and gas shadowing distally. There is no observed focal or generalized colon wall thickening or loss of layering.

**WEIGHT**

23.8 lbs

**Pancreas**

The pancreas is visible/mildly mottled in the right limb. There is no evidence of nodules or cystic lesions. There is no evidence of regional mesenteric inflammation or fluid.

**INTERPRETED BY**

Kathleen Sennello DVM,  
 MS, Diplomate ACVIM  
 (Small Animal Internal  
 Medicine)

**Free Abdomen**

Evaluation of the peritoneal cavity did not reveal any evidence of effusion, or subjective lymphadenomegaly. The Medial iliac nodes appear normal and there was no evidence of a caudal aortic thrombus at the bifurcation. The omentum is of normal uniform echogenicity.

**IMAGING PERFORMED BY**

Kathleen Byrnes

**PRIMARY FINDINGS**

- Dependent mineralized/sandy debris visualized in the urinary bladder – Recommend urinalysis +/- culture and radiographs.
- Large, heterogeneous liver – The diffuse hepatic changes are non-specific and could be consistent with vacuolar hepatopathy, nodular hyperplasia, inflammatory/immune-mediated disease, fibrosis, extramedullary hematopoiesis, toxic hepatopathy (e.g., copper), infiltrative neoplasia (less likely) or other hepatopathy.
- Moderate gallbladder debris – The significance of the aggregated gallbladder debris is unclear. This could represent an early mucocele, cholestasis, or may be secondary to fasting but seems unlikely to be causing a current issue. Recommend continued monitoring.

**HOSPITAL NAME**

Stewart's Mountain  
 Animal Hospital

**SECONDARY FINDINGS**

- Age related changes visualized associated with both kidneys.
- Pancreatic changes most consistent with chronic pancreatic remodeling.

**REFERRING VET**

Dr. Stewart

**INVOICE**

73038

**DATE**

2/18/26



**PATIENT**

Roscoe Ledford

**SPECIES**

Canine

**BREED**

Pomeranian x

**SEX**

Neutered Male

**AGE**

16 Years

**WEIGHT**

23.8 lbs

**INTERPRETED BY**

Kathleen Sennello DVM,  
 MS, Diplomate ACVIM  
 (Small Animal Internal  
 Medicine)

**IMAGING  
 PERFORMED BY**

Kathleen Byrnes

**HOSPITAL NAME**

Stewart's Mountain  
 Animal Hospital

**REFERRING VET**

Dr. Stewart

**INVOICE**

73038

**DATE**

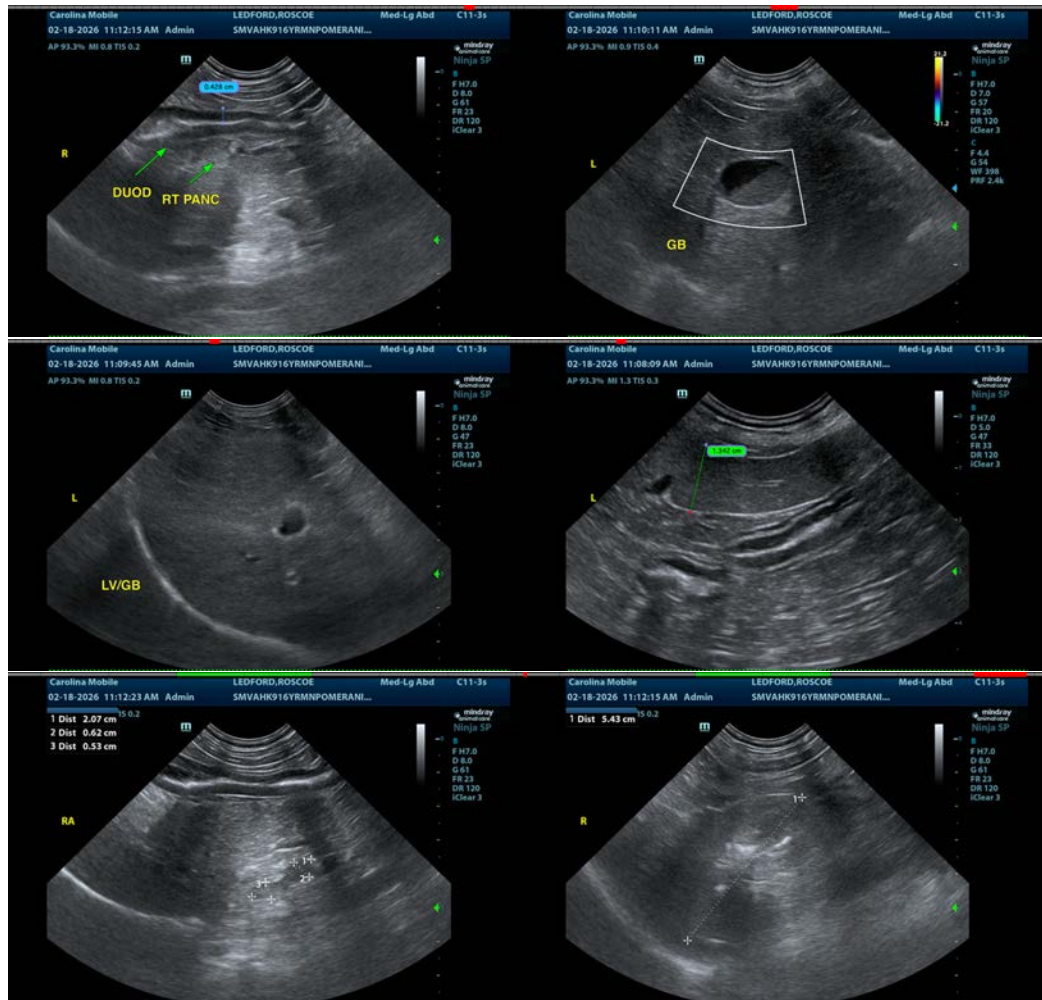
2/18/26

**INTERPRETATION OF THE FINDINGS & FURTHER RECOMMENDATIONS**

The liver is large and heterogeneous. No focal lesions were visualized. These findings in combination with elevation in ALP are most consistent with a vacuolar hepatopathy, although other hepatopathies are possible. If further evaluation is desired, you could consider a liver function test (pre- and post-prandial bile acids) and a fine needle aspirate of the liver for cytologic evaluation.

There is a moderate amount of debris visualized in the gallbladder, but no evidence of associated inflammation. Options would include continued monitoring or initiation of chronic Ursodiol therapy and continued monitoring of the gallbladder.

Both adrenals are normal in size. This does not rule out the possibility of underlying Cushing's disease but makes it somewhat less likely. If symptoms classic for Cushing's are present, you could consider adrenal function testing.





**PATIENT**

Roscoe Ledford

**SPECIES**

Canine

**BREED**

Pomeranian x

**SEX**

Neutered Male

**AGE**

16 Years

**WEIGHT**

23.8 lbs

**INTERPRETED BY**

Kathleen Sennello DVM,  
 MS, Diplomate ACVIM  
 (Small Animal Internal  
 Medicine)

**IMAGING  
 PERFORMED BY**

Kathleen Byrnes

**HOSPITAL NAME**

Stewart's Mountain  
 Animal Hospital

**REFERRING VET**

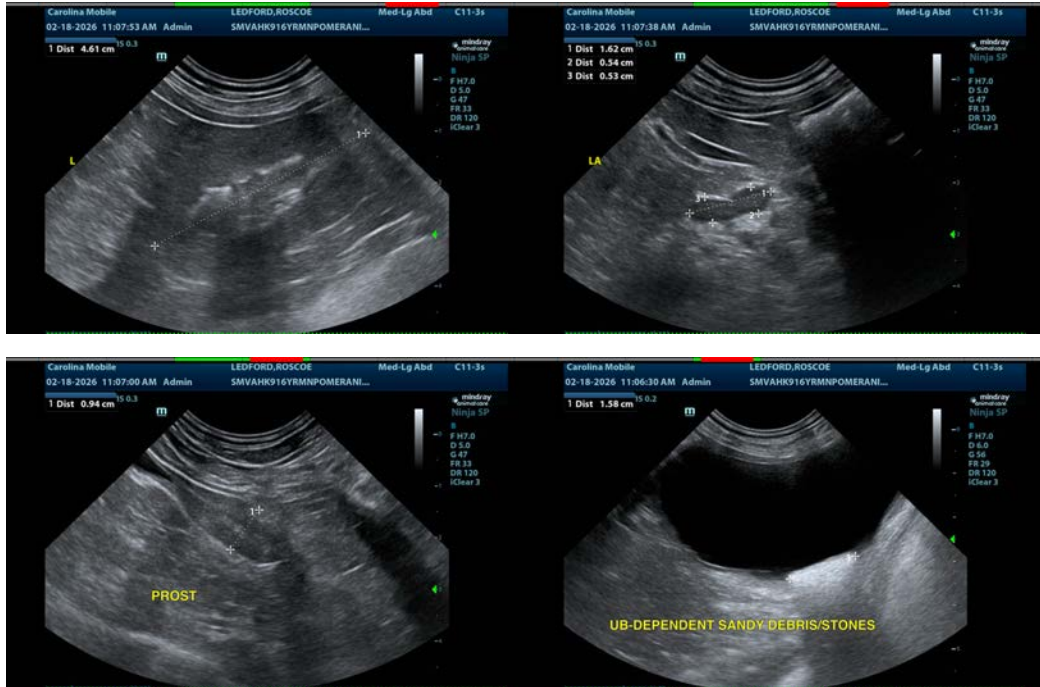
Dr. Stewart

**INVOICE**

73038

**DATE**

2/18/26



The information and recommendations provided are based on the images presented by the referring veterinarian/sonographer. No evaluation can be communicated regarding pathology that was not visible in the image/video clips provided.

Thank you for this referral. If the clinical or image interpretation does not parallel your findings or if I can be of any further assistance please contact me.

Kathleen Sennello DVM,MS, Diplomate ACVIM (Small animal Internal Medicine)

info@sonopath.com