



PATIENT

Ginsburg Pauls

SPECIES

Feline

BREED

DSH

SEX

Spayed Female

AGE

8 Years 10 Months

WEIGHT

8.1 lbs

INTERPRETED BY

Kathleen Sennello DVM,
MS, Diplomate ACVIM
(Small Animal Internal
Medicine)

IMAGING PERFORMED BY

Heather Platzer

HOSPITAL NAME

Hershire Animal
Hospital

REFERRING VET

Lindsay Bohling, DVM

INVOICE

73055

DATE

2/18/26

PRESENTING CLINICAL SIGNS

Patient has had a history of urinary issues. In December patient starting with urinary issues - going in and out of the litterbox with drops of blood in the urine. Patient was sent home on Clavamox and Buprenex. Bloodwork revealed - mild basophilia and creatinine at 2.1. Once off antibiotics -- patient relapsed: hematuria, pollakiuria, and inappropriate urination. Patient cries out in pain and hides. Transitioned to Hil's C/D -- sent home Gabapentin and Buprenorphine. Patient did well for about 1 month - then started squatting and urinating on owner's bed. On February 9 -- urinalysis SG 1.008, pH 6.0, 0-2 WBC, no bacteria seen. Patient went to ER that following day - for straining to urinate and vocalizing. Radiographs taken - no urinary or kidney stones. Diagnosed with UTI on urinalysis- sent home with Buprenex and 5 days of Clavamox. Patient did well on medications -- but started with inappropriate urination, vocalizing in pain, hiding from client - and blood tinge in urine. Patient is on Hydracare and C/D stress

ULTRASONOGRAPHIC EXAMINATION OF THE ABDOMEN

Urinary System

The urinary bladder is moderately distended with anechoic urine. The Bladder wall, trigone, ureteral papillae and visible urethra (to a depth of 2cm) appear normal with no evidence of wall thickening, mucosal irregularities, masses or cystic calculi.

The left kidney has a normal shape and size (3.23 cm). Overall echogenicity is normal with adequate corticomedullary distinction and a typical 1:3 cortex:medulla ratio. There is no evidence of focal perinephric inflammation or effusion. There is no evidence of pyelectasia, nephroliths, infarcts or hydroureter. Renal vasculature is normal.

The right kidney has a normal shape and size (3.34 cm). Overall echogenicity is normal with adequate corticomedullary distinction and a typical 1:3 cortex:medulla ratio. There is no evidence of focal perinephric inflammation or effusion. There is no evidence of pyelectasia, nephroliths, infarcts or hydroureter. Renal vasculature is normal.

Adrenal Glands

The left adrenal gland is normal in size measuring 0.39 cm at the caudal pole. It is observed in its normal position cranial to the left renal artery. It is normal in appearance (uniformly hypoechoic) and shape with no evidence of a mass effect.

The right adrenal gland is normal in size measuring 0.37 cm at the caudal pole. It is observed in its normal position between the cranial aspect of the right kidney and the caudal vena cava. It is normal in appearance (uniformly hypoechoic) and shape with no evidence of a mass effect.

Spleen

The spleen is subjectively normal in size (0.80 cm), echotexture is homogenous, and the splenic capsule is smooth with no irregularities. The blood flow through the hilus and splenic parenchyma appears normal. No focal parenchymal abnormalities are visualized.

Liver

The liver is subjectively normal in size, and echogenicity with smooth peripheral margins. The parenchyma is subjectively mildly heterogenous in echotexture with subtle, indistinct focal mottling.



PATIENT

Ginsburg Pauls

SPECIES

Feline

BREED

DSH

SEX

Spayed Female

AGE

8 Years 10 Months

WEIGHT

8.1 lbs

INTERPRETED BY

Kathleen Sennello DVM,
MS, Diplomate ACVIM
(Small Animal Internal
Medicine)

IMAGING PERFORMED BY

Heather Platzer

HOSPITAL NAME

Hershire Animal
Hospital

REFERRING VET

Lindsay Bohling, DVM

INVOICE

73055

DATE

2/18/26

The visible portions of the vasculature and biliary tract appear normal. No focal nodules or cystic lesions are observed.

The gall bladder lumen is moderately distended. The wall of the gall bladder is not thickened and has a smooth mucosal surface. Luminal contents are mild and likely incidental at this time. The bile duct appears mildly tortuous but not significantly dilated, measuring at 1.7 cm.

Gastrointestinal

The stomach contains mild fluid. It measures at a normal thickness of <0.36cm with some variability due to the presence of rugal folds. The distinction of the gastric wall layers is adequate and there is no impression of reduced peristaltic activity. No masses or focal lesions were observed.

The visualized areas of duodenum, jejunum and ileum have a uniform diameter with minimal fluid distension. Wall thickness is normal to slightly increased. Bowel loops follow a typical curvilinear path with distinct wall layering, but some areas display a prominent muscularis layer which does not display the typical 1:3 muscularis:mucosa layer ratio. Duodenum wall measures 0.31 cm. Jejunum wall measures 0.28 cm. Visualized peristalsis appears appropriate. There were no focal lesions consistent with obstruction or a mass effect observed.

The ileocecal junction was visualized and exhibited normal intact wall layering and is subjectively of normal thickness. Sections of colon are visualized with formed fecal material and gas shadowing distally. There is no observed focal or generalized colon wall thickening or loss of layering.

Pancreas

The pancreas is visible/mildly mottled in the left limb. There is no evidence of nodules or cystic lesions. There is no evidence of regional mesenteric inflammation or fluid.

Free Abdomen

Evaluation of the peritoneal cavity did not reveal any evidence of effusion, or subjective lymphadenomegaly. The Medial iliac nodes appear normal and there was no evidence of a caudal aortic thrombus at the bifurcation. The omentum is of normal uniform echogenicity.

PRIMARY FINDINGS

- Mildly heterogeneous liver – The significance of this is uncertain in the absence of liver enzyme elevations. If not already done, recommend current lab work.
- Prominent muscularis layer of the small intestine – The small intestinal wall changes could be consistent with an underlying inflammatory process. These types of changes can sometimes be seen in normal older cats. Correlate with clinical signs.

SECONDARY FINDINGS

- Pancreatic changes consistent with mild pancreatic remodeling.

INTERPRETATION OF THE FINDINGS & FURTHER RECOMMENDATIONS

No lesions are visualized associated with the urinary tract to explain the lower urinary tract symptoms described. Unfortunately, this does not rule out lower urinary tract disease, as mobile mineralizations, strictures, intramural inflammation, etc. are all still possible. Recommend the following:



PATIENT

Ginsburg Pauls

SPECIES

Feline

BREED

DSH

SEX

Spayed Female

AGE

8 Years 10 Months

WEIGHT

8.1 lbs

INTERPRETED BY

Kathleen Sennello DVM,
MS, Diplomate ACVIM
(Small Animal Internal
Medicine)

IMAGING PERFORMED BY

Heather Platzer

HOSPITAL NAME

Hershire Animal
Hospital

REFERRING VET

Lindsay Bohling, DVM

INVOICE

73055

DATE

2/18/26

- Recommend a urine culture when the patient has been off antibiotics for at least 5 days.

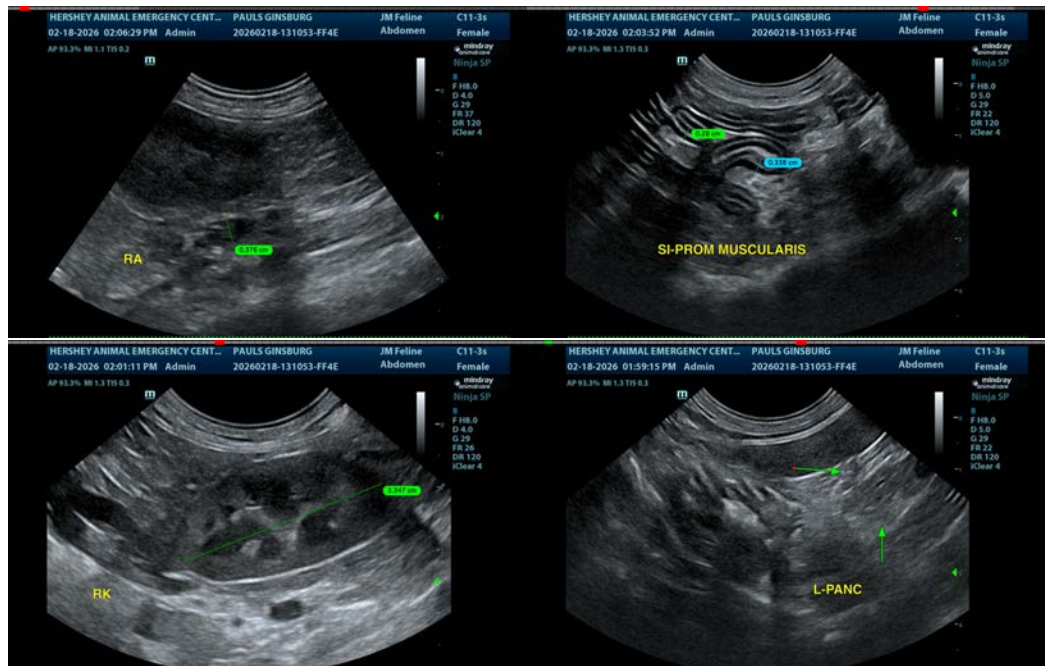
- A urethral lesion is less likely in a female, but if there is concern, cystoscopy and/or an anesthetized vaginal exam may be of benefit.

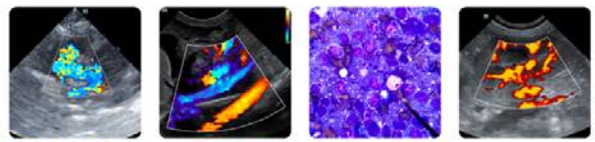
If the urine culture is negative and interstitial cystitis is suspected, consider the following:

- Treatment of FIC can be frustrating as it is a waxing and waning disease. Treatment strategies vary and there is no "one fits all" approach. There is currently no cure for FIC. Goals of therapy include reduction of severity and duration of clinical signs during an acute episode; increasing the interval between episodes; and decreasing severity of signs in cats with persistent FIC. Approximately 85% of cats will experience clinical improvement with or without therapy.
- Numerous therapies can be considered including: diet, multimodal environmental modification, analgesics, anti-inflammatories, anti-anxiety medications etc..
- Close observation is warranted as some cats do experience life-threatening urinary obstruction.
- If symptoms are worsening re-evaluation with ultrasound should be considered.

Subjectively, the liver appears mildly heterogeneous, and the bile duct is slightly tortuous. These might represent anatomic variation. If current lab work has not been performed, recommend obtaining a baseline.

The muscularis layer of the small intestine is somewhat prominent. In the absence of gastrointestinal symptoms, continued monitoring is warranted.





PATIENT

Ginsburg Pauls

SPECIES

Feline

BREED

DSH

SEX

Spayed Female

AGE

8 Years 10 Months

WEIGHT

8.1 lbs

INTERPRETED BY

Kathleen Sennello DVM,
MS, Diplomate ACVIM
(Small Animal Internal
Medicine)

**IMAGING
PERFORMED BY**

Heather Platzer

HOSPITAL NAME

Hershire Animal
Hospital

REFERRING VET

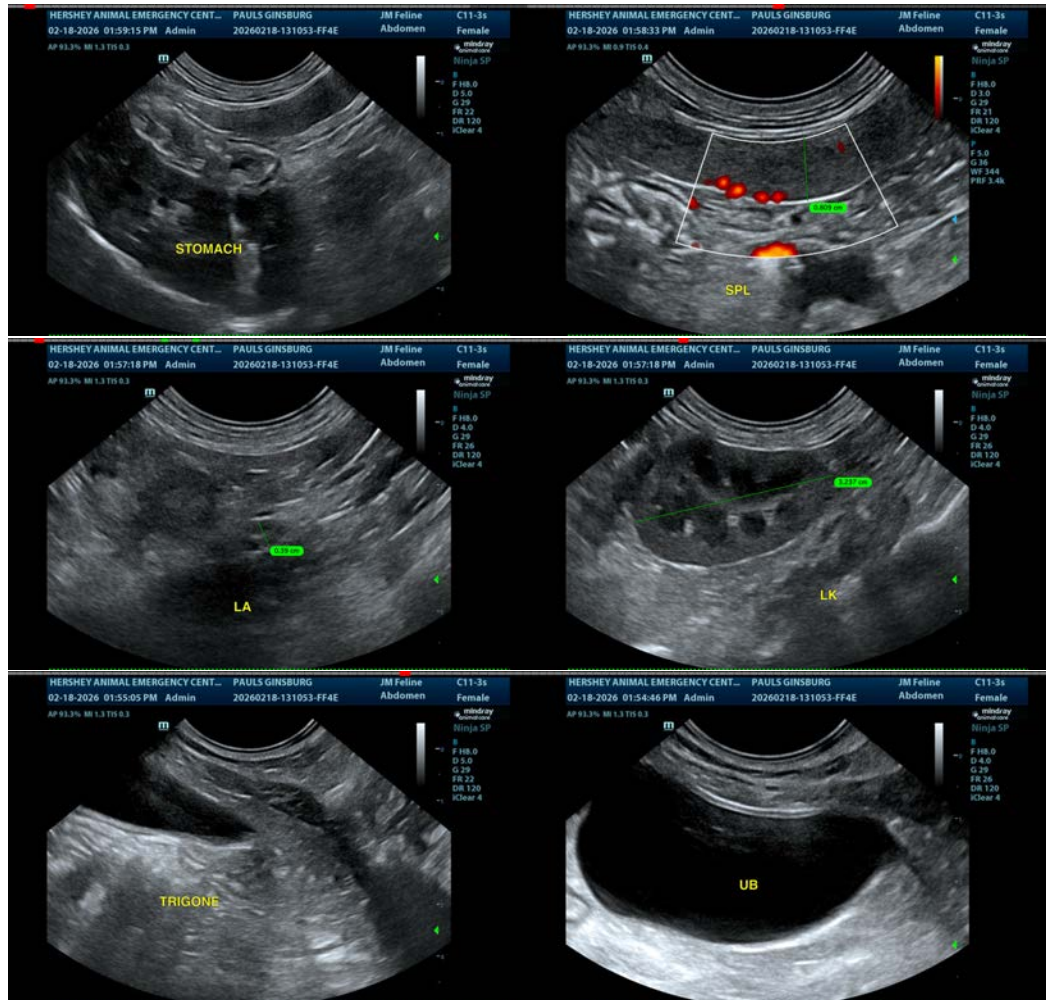
Lindsay Bohling, DVM

INVOICE

73055

DATE

2/18/26



The information and recommendations provided are based on the images presented by the referring veterinarian/sonographer. No evaluation can be communicated regarding pathology that was not visible in the image/video clips provided.

Thank you for this referral. If the clinical or image interpretation does not parallel your findings or if I can be of any further assistance please contact me.

Kathleen Sennello DVM,MS, Diplomate ACVIM (Small animal Internal Medicine)

info@sonopath.com