



PATIENT

Tui Hanson

SPECIES

Feline

BREED

DSH

SEX

Neutered Male

AGE

1 Years 11 Months

WEIGHT

7.06 Pounds

INTERPRETED BY

Kathleen Sennello DVM,
MS, Diplomate ACVIM
(Small Animal Internal
Medicine)

**IMAGING
PERFORMED BY**

Michaleen

HOSPITAL NAME

DPC Vet Hospital

REFERRING VET

Dr. Feldt

INVOICE

35737

DATE

2/18/22

PRESENTING CLINICAL SIGNS

Rechecking: vomiting/lethargy History: Approx 2yr old neutered dsh presented for still not eating/lethargic and vomited today. Pet was here 3 days ago for not eating for 4 days, possibly ate foam from a chair, but was actually vomiting before that. Pet did seem to improve a little with no more vomiting and eating some treats. Owner was unable to give the cerenia until today but he did vomit approx 30 min later.

Abnormal PE/Chem/CBC/UA Results: Exam Notes: QAR, mm pink slightly tacky, slight skin tent. Ab Palp - focal area of intestinal thickening, approx 1.5cm somewhat square firm non-compressible ? FB in intestine CBC/CHEM/LYTES/FPL - WNL Testing Performed: Radiographs Results: Empty GI tract. Suspect mild hypermotility of the small intestinal tract.

ULTRASONOGRAPHIC EXAMINATION OF THE ABDOMEN

Urinary System

The urinary bladder is moderately distended with anechoic urine. The Bladder wall, trigone, ureteral papillae and visible urethra (to a depth of 2cm) appear normal with no evidence of wall thickening, mucosal irregularities, masses or cystic calculi.

The left kidney has a normal shape and size (2.7 cm). Overall echogenicity is normal with adequate corticomedullary distinction and a typical 1:3 cortex:medulla ratio. There is no evidence of perinephric inflammation or effusion. There is no evidence of pyelectasia, nephroliths, infarcts or hydroureter. Renal vasculature is normal.

The right kidney has a normal shape and size (3.3 cm). Overall echogenicity is normal with adequate corticomedullary distinction and a typical 1:3 cortex:medulla ratio. There is no evidence of perinephric inflammation or effusion. There is no evidence of pyelectasia, nephroliths, infarcts or hydroureter. Renal vasculature is normal.

Adrenal Glands

The region of left adrenal (Cranial to left renal artery) is unremarkable but the adrenal is not distinctly visualized. No evidence of a mass effect.

The region of the right adrenal (between right cranial kidney and vena cava) is unremarkable, but the adrenal is not distinctly visualized. No evidence of a mass effect.

Spleen

The spleen is subjectively normal in size, echotexture is homogenous, and the splenic capsule is smooth with no irregularities. The blood flow through the hilus and splenic parenchyma appears normal. No focal parenchymal abnormalities are visualized.

Liver

The liver is subjectively normal in size, and echogenicity with smooth peripheral margins. The parenchyma is homogenous echotexture. The visible portions of the vasculature and biliary tract appear normal. No focal nodules or cystic lesions are observed.

The gallbladder lumen is moderately distended. The wall of the gall bladder is not thickened and has a smooth mucosal surface. Luminal contents are primarily anechoic. The cystic and common bile ducts are normal/not visible.



PATIENT

Gastrointestinal

Tui Hanson

The stomach is moderately dilated with fluid and irregular shadowing material. There is a structure visualized measuring 2.9 cm x 2.2 cm that is hyperechoic possibly associated with the wall of the stomach. This could be consistent with intraluminal foreign material or abnormal tissue. Color flow in the area would be helpful along with greater resolution to determine wall layering, etc.

SPECIES

Feline

Most of the small intestine visualized appears to be relatively normal with a lack of fluid distention, etc. There is a portion of bowel imaged that appears to have a prominent, hypoechoic wall at 0.53 cm, labeled as mid abdomen on the images. Layering is difficult to discern, which could be either due to lack of image resolution or true loss of layering. In other images, is shadowing material within a section of bowel. I am unable to follow this lesion to determine if it is foreign material or stool in the colon no obstructive dilation is observed associated with this lesion.

BREED

DSH

SEX

Neutered Male

The ileocecal junction was visualized and exhibited normal intact wall layering and is subjectively of normal thickness. Sections of colon are visualized with formed fecal material and gas shadowing distally. There is no observed focal or generalized colon wall thickening or loss of layering.

AGE

1 Years 11 Months

Pancreas

The pancreas is normal and isoechoic to surrounding mesentery. There is no evidence of nodules or cystic lesions. There is no evidence of regional mesenteric inflammation or fluid.

WEIGHT

7.06 Pounds

Free Abdomen

Evaluation of the peritoneal cavity did not reveal any evidence of effusion. There is a prominent mesenteric lymph node visualized at 0.58 cm. The omentum is of normal echogenicity.

ULTRASONOGRAPHIC FINDINGS

INTERPRETED BY

Kathleen Sennello DVM,
MS, Diplomate ACVIM
(Small Animal Internal
Medicine)

- Moderately fluid dilated stomach with intraluminal shadowing material – The nature of this shadowing material is unclear. It could be consistent with ingesta, soft tissue, or foreign material.
- Areas of thickened small intestine with possible reduced detail and layering – Differentials for intestinal wall thickening include inflammation or infiltrative disease.
- Shadowing material visualized within the bowel – It is unclear if this is a section of small or large bowel. No obstructive pattern is visualized in this area.
- Mild mesenteric lymphadenopathy – The prominent abdominal lymph nodes are most consistent with reactive lymphadenitis or lymphoid hyperplasia. Neoplastic infiltration is considered less likely. This could be a normal finding in a young cat.

IMAGING PERFORMED BY

Michaleen

HOSPITAL NAME

DPC Vet Hospital

INTERPRETATION OF THE FINDINGS & FURTHER RECOMMENDATIONS

REFERRING VET

Dr. Feldt

Visualization of some of the critical points of the abdomen was difficult due to lack of resolution and dark images. The general impression is a somewhat fluid dilated stomach with some irregular intraluminal material. This could represent foreign material or ingesta, or even gastric wall tissue.

INVOICE

35737

Additionally, there is a section of small intestine that appeared to have thickened prominent wall. A mass effect would be atypical in a cat this young, but not impossible. Correlate these findings with abdominal radiographs and your clinical picture. A foreign body nor mass effect cannot be ruled out based on today's ultrasound. If clinical signs persist, exploratory surgery may need to be considered.

DATE

2/18/22



PATIENT

Tui Hanson

SPECIES

Feline

BREED

DSH

SEX

Neutered Male

AGE

1 Years 11 Months

WEIGHT

7.06 Pounds

INTERPRETED BY

Kathleen Sennello DVM,
MS, Diplomate ACVIM
(Small Animal Internal
Medicine)

**IMAGING
PERFORMED BY**

Michaleen

HOSPITAL NAME

DPC Vet Hospital

REFERRING VET

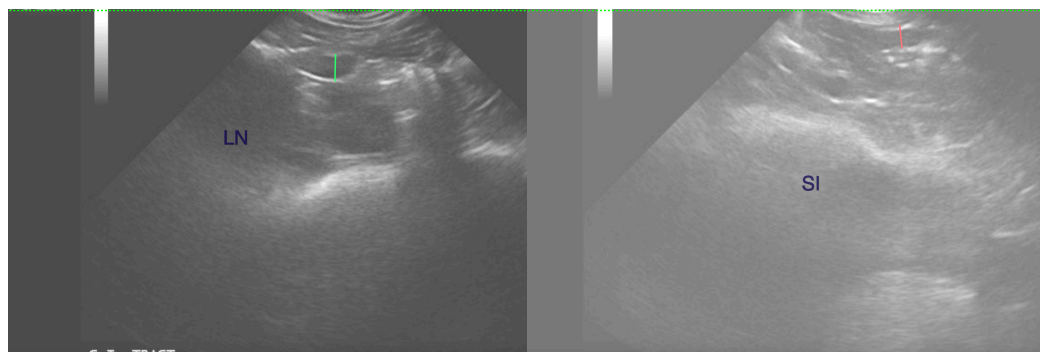
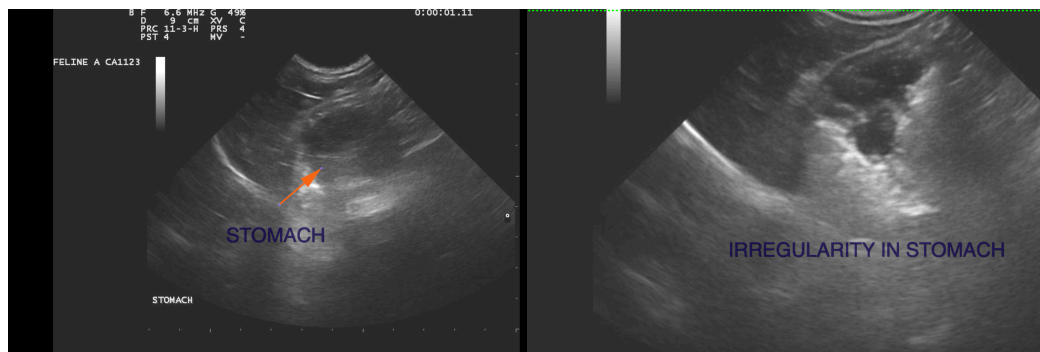
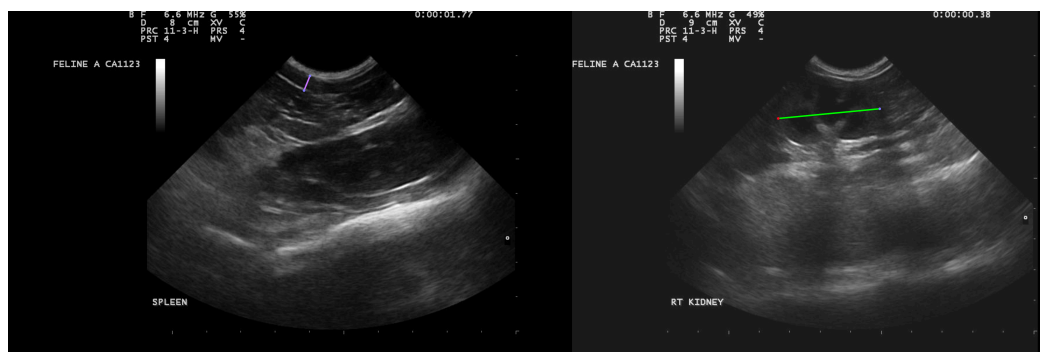
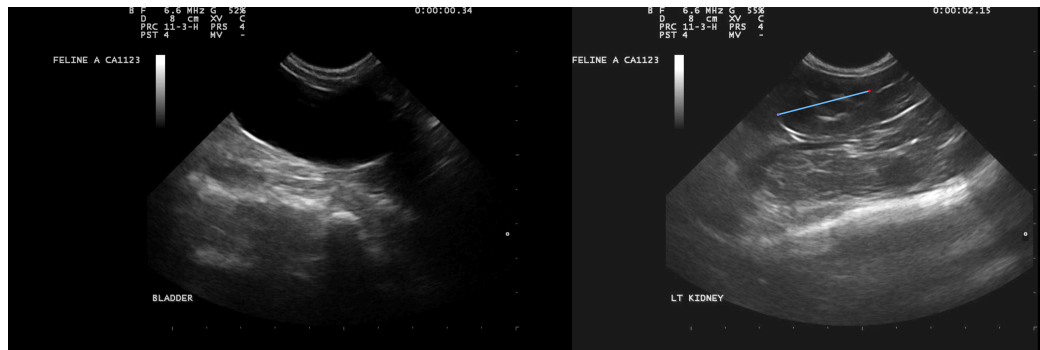
Dr. Feldt

INVOICE

35737

DATE

2/18/22





PATIENT

Tui Hanson

SPECIES

Feline

BREED

DSH

SEX

Neutered Male

AGE

1 Years 11 Months

WEIGHT

7.06 Pounds

INTERPRETED BY

Kathleen Sennello DVM,
MS, Diplomate ACVIM
(Small Animal Internal
Medicine)

**IMAGING
PERFORMED BY**

Michaleen

HOSPITAL NAME

DPC Vet Hospital

REFERRING VET

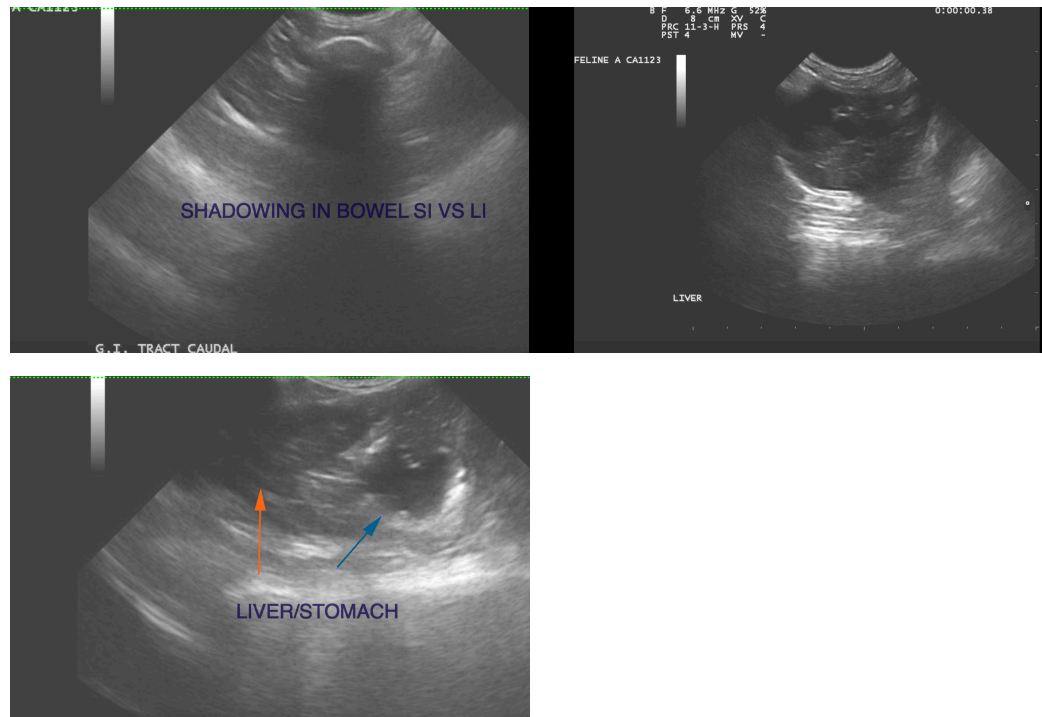
Dr. Feldt

INVOICE

35737

DATE

2/18/22



The information and recommendations provided are based on the images presented by the referring veterinarian/sonographer. No evaluation can be communicated regarding pathology that was not visible in the image/video clips provided.

Thank you for this referral. If the clinical or image interpretation does not parallel your findings or if I can be of any further assistance please contact me.

Kathleen Sennello DVM,MS, Diplomate ACVIM (Small animal Internal Medicine)

kathleen.sennello@sonopath.com