

PATIENT

Star Loewen-Parker

SPECIES

Canine

BREED

Mix

SEX

FS

AGE

12 Years

WEIGHT

51 lbs

INTERPRETED BY

Kathleen Sennello DVM,
MS, Diplomate ACVIM
(Small Animal Internal
Medicine)

**IMAGING
PERFORMED BY**

Hannah Fearing

HOSPITAL NAME

Lanier Animal Hospital

REFERRING VET

Hannah Fearing

INVOICE

50367

DATE

2-18-22

PRESENTING CLINICAL SIGNS

Not eating and drinking well since 2/11-12, started vomiting around 2/13. Lethargic. Tx with Cerenia and SQ fluids on 2/14 - vomiting controlled but still not eating normally and lethargic. Abnormal PE/Chem/CBC/UA Results: 2/14 - SDMA 21; alk phos 472; rest of CBC/Chem/T4 WNL, cPL normal 2/14 - normal thoracic and abdominal radiographs

ULTRASONOGRAPHIC EXAMINATION OF THE ABDOMEN

Urinary System

The urinary bladder is minimally distended with anechoic urine. No lesions are noted but evaluation of the bladder is hindered by lack of urine distension.

The left kidney has a normal shape and size (6.3cm). Overall echogenicity is normal with adequate corticomedullary distinction and a typical 1:3 cortex:medulla ratio. There is no evidence of perinephric inflammation or effusion. There is no evidence of pyelectasia, nephroliths, infarcts or hydroureter. Renal vasculature is normal.

The right kidney has a normal shape and size (6.4cm). Overall echogenicity is normal with adequate corticomedullary distinction and a typical 1:3 cortex:medulla ratio. There is no evidence of perinephric inflammation or effusion. There is no evidence of pyelectasia, nephroliths, infarcts or hydroureter. Renal vasculature is normal.

Adrenal Glands

The left adrenal gland is normal in size measuring 0.7cm at the caudal pole. It is observed in its normal position cranial to the left renal artery. It is normal in appearance (uniformly hypoechoic) and shape with no evidence of a mass effect.

The region of the right adrenal (between right cranial kidney and vena cava) is unremarkable, but the adrenal is not distinctly visualized. No evidence of a mass effect.

Spleen

The spleen is subjectively normal in size, echotexture is homogenous, and the splenic capsule is smooth with no irregularities. The blood flow through the hilus and splenic parenchyma appears normal. No focal parenchymal abnormalities are visualized.

Liver

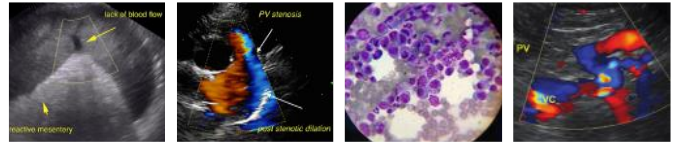
The liver is subjectively normal in size, and echogenicity with smooth peripheral margins. The parenchyma is heterogenous in echotexture with subtle, indistinct focal mottling. The visible portions of the vasculature and biliary tract appear normal. No focal nodules or cystic lesions are observed.

The gallbladder lumen is moderately distended. The wall of the gall bladder is not thickened and has a smooth mucosal surface. Luminal contents are primarily anechoic. The cystic and common bile ducts are normal/not visible.

Gastrointestinal

The stomach contains minimal luminal contents. It measures at a normal thickness of <0.7cm with some variability due to the presence of rugal folds. The distinction of the gastric wall layers is adequate and there is no impression of reduced peristaltic activity. No masses or focal lesions were observed.

The visualized areas of duodenum, jejunum and ileum have a relatively uniform diameter with minimal fluid distension. Wall thickness is normal. Bowel loops follow a curvilinear path with distinct wall



PATIENT

Star Loewen-Parker

layering maintaining the typical 1:3 muscularis:mucosa layer ratio. The duodenum measured as normal (0.46cm in wall thickness) and the jejunum measured as normal (0.37cm.) Visualized peristalsis appears appropriate. There were no focal lesions consistent with obstruction or a mass effect observed.

SPECIES

Canine

The ileocecal junction was visualized and exhibited normal intact wall layering and is subjectively of normal thickness. Sections of colon are visualized with formed fecal material and gas shadowing distally. There is no observed focal or generalized colon wall thickening or loss of layering.

Pancreas

BREED

Mix

The pancreas is normal and isoechoic to surrounding mesentery. There is no evidence of nodules or cystic lesions. There is no evidence of regional mesenteric inflammation or fluid.

Free Abdomen

SEX

FS

Evaluation of the peritoneal cavity did not reveal any evidence of effusion, or subjective lymphadenomegaly. The Medial iliac nodes appear normal and there was no evidence of a caudal aortic thrombus at the bifurcation. The omentum is of normal uniform echogenicity.

AGE

12 Years

ULTRASONOGRAPHIC FINDINGS

Primary

- The diffuse hepatic changes are non-specific and could be consistent with vacuolar hepatopathy, nodular hyperplasia, inflammatory/immune-mediated disease, fibrosis, extramedullary hematopoiesis, toxic hepatopathy (e.g., copper), infiltrative neoplasia (less likely) or other hepatopathy.

WEIGHT

51 lbs

INTERPRETATION OF THE FINDINGS & FURTHER RECOMMENDATIONS

No focal lesions were visualized on today's scan.

The liver was subjectively heterogeneous which is a nonspecific finding. The liver enzyme elevations could represent a primary hepatopathy or this could be incidental and secondary to a primary gastrointestinal problem, etc.

INTERPRETED BY

Kathleen Sennello DVM,
MS, Diplomate ACVIM
(Small Animal Internal
Medicine)

IMAGING PERFORMED BY

Hannah Fearing

HOSPITAL NAME

Lanier Animal Hospital

REFERRING VET

Hannah Fearing

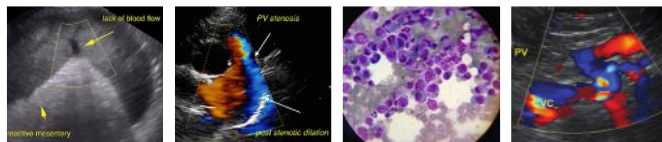
- Consider metabolic causes for vomiting. Recommend a liver function test and consider a GI panel to Texas A&M for qualitative TLI/PLI, cobalamin, and folate to look for evidence of pancreatic or small intestinal disease.
- If metabolic disease is thought unlikely, consider primary GI causes such as dietary indiscretion, dietary intolerance, GI parasites, dysbiosis, IBD, and less likely gastrointestinal neoplasia.
- Recommend symptomatic treatment for gastroenteritis/pancreatitis while diagnostics are pending. Consider novel protein or hydrolyzed protein prescription diet. Consider chronic probiotic therapy. If symptoms persist, consider reimaging. If primary gastrointestinal disease is thought likely, could consider obtaining GI biopsies.

INVOICE

50367

DATE

2-18-22



PATIENT

Star Loewen-Parker

SPECIES

Canine

BREED

Mix

SEX

FS

AGE

12 Years

WEIGHT

51 lbs

INTERPRETED BY

Kathleen Sennello DVM,
MS, Diplomate ACVIM
(Small Animal Internal
Medicine)

**IMAGING
PERFORMED BY**

Hannah Fearing

HOSPITAL NAME

Lanier Animal Hospital

REFERRING VET

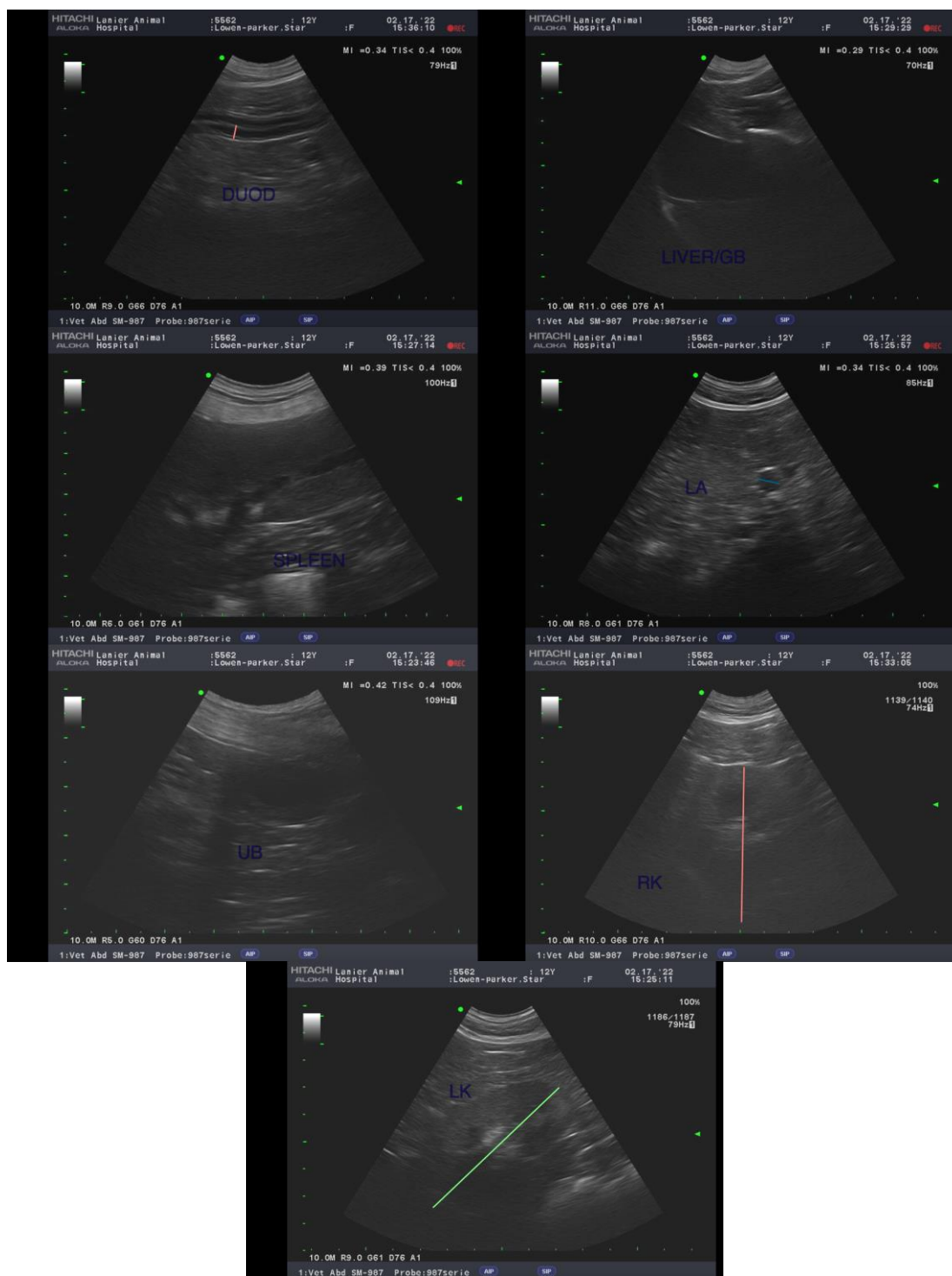
Hannah Fearing

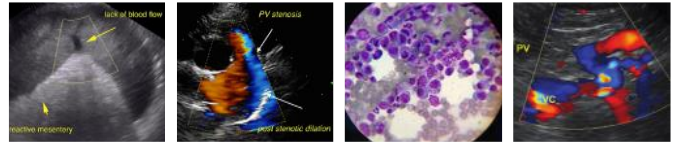
INVOICE

50367

DATE

2-18-22





PATIENT

Star Loewen-Parker

The information and recommendations provided are based on the images presented by the referring veterinarian/sonographer. No evaluation can be communicated regarding pathology that was not visible in the image/video clips provided.

SPECIES

Canine

Thank you for this referral. If the clinical or image interpretation does not parallel your findings or if I can be of any further assistance please contact me.

BREED

Mix

Kathleen Sennello DVM,MS, Diplomate ACVIM (Small animal Internal Medicine)
kathleen.sennello@sonopath.com

SEX

FS

AGE

12 Years

WEIGHT

51 lbs

INTERPRETED BY

Kathleen Sennello DVM,
MS, Diplomate ACVIM
(Small Animal Internal
Medicine)

**IMAGING
PERFORMED BY**

Hannah Fearing

HOSPITAL NAME

Lanier Animal Hospital

REFERRING VET

Hannah Fearing

INVOICE

50367

DATE

2-18-22