

**DATE PRESENTING CLINICAL SIGNS**

2/18/22

History: Chronic diarrhea (5 years). Strains to defecate & also leaks diarrhea. Has been on prednisone 2.5mg daily for a long time-stool has applesauce consistency on pred-liquid consistency off pred. Also, B-12 injections (frequency unknown). Many diet trials. Abd scan done by radiologist w/mobile practice in 2020- "increased colonic wall thickness" "mild medial iliac In enlargement" "decreased length of colon" "mild increased muscularis layer thickening within small intestines". My first eval of Squeak- 1/19/22: Increased prednisolone to 5mg sid. Added Fortiflora. Started Royal Canin Ultamino dry & royal canin gastrointestinal canned-he will eat both. 3 weeks later-stool still applesauce consistency-but no more "urgent explosions"

PATIENT

Squeak Akin

SPECIES

Feline

Current Medications: Past 3 weeks-prednisolone 5mg SID
Fortiflora daily.

BREED

DSH

Lab Results: 1/19/22: Chem/T4/UA - wnl. CBC-elevated monocytes 896, rest normal. Other vet at prev hospital ran a maldigestion profile 1/19/22: Cobalamin > 1000, Folate 16.5, TLI 62.2 (12-82), PLI 31.3 (HIGH). 0.1-3.5

SEX

Neutered Male

Date of Previous IntraPet Ultrasound: No previous IntraPet scans.
Sedation: Not required to complete full diagnostic ultrasound.
Stat Report: Not requested.

ULTRASONOGRAPHIC EXAMINATION OF THE ABDOMEN**AGE**

3/17/06

Urinary System

The urinary bladder is moderately distended with anechoic urine. The Bladder wall, trigone, ureteral papillae and visible urethra (to a depth of 2cm) appear normal with no evidence of wall thickening, mucosal irregularities, masses or cystic calculi.

WEIGHT

7.9 Pounds

The left kidney has a normal shape and size (3.51 cm). Overall echogenicity is normal with adequate corticomedullary distinction and a typical 1:3 cortex:medulla ratio. There is no evidence of perinephric inflammation or effusion. There is no evidence of pyelectasia, nephroliths, infarcts or hydroureter. Renal vasculature is normal.

INTERPRETED BY

Kathleen Sennello DVM,
MS, Diplomate ACVIM
(Small Animal Internal
Medicine)

The right kidney has a normal shape and size (3.66 cm). Overall echogenicity is normal with adequate corticomedullary distinction and a typical 1:3 cortex:medulla ratio. There is no evidence of perinephric inflammation or effusion. There is no evidence of pyelectasia, nephroliths, infarcts or hydroureter. Renal vasculature is normal.

IMAGING PERFORMED BY

Andi Parkinson RDMS

Adrenal Glands

The region of left adrenal (Cranial to left renal artery) is unremarkable but the adrenal is not distinctly visualized. No evidence of a mass effect.

HOSPITAL NAME

Timonium AH

The right adrenal gland is normal in size measuring 0.48 cm at the caudal pole. It is observed in its normal position between the cranial aspect of the right kidney and the caudal vena cava. It is normal in appearance (uniformly hypoechoic) and shape with no evidence of a mass effect.

REFERRING VET

Dr. Kauder

Spleen

The spleen is subjectively normal in size, echotexture is homogenous, and the splenic capsule is smooth with no irregularities. The blood flow through the hilus and splenic parenchyma appears normal. No focal parenchymal abnormalities are visualized.

INVOICE

35765

Liver

The liver is subjectively normal in size, and echogenicity with smooth peripheral margins. The parenchyma is homogenous echotexture. The visible portions of the vasculature and biliary tract appear normal. There are

at least two somewhat ill-defined, hyperechoic nodules visualized within the parenchyma, measuring 0.88 cm and 0.85.

The gallbladder lumen is moderately distended. The wall of the gall bladder is not thickened and has a smooth mucosal surface. Luminal contents are primarily anechoic. The cystic and common bile ducts are normal/not visible.

Gastrointestinal

The stomach is moderately dilated with fluid and irregular shadowing material most consistent with normal ingesta and gas. It measures at a normal thickness of <0.36cm with some variability due to the presence of rugal folds. The distinction of the gastric wall layering is adequate and there is no impression of reduced peristaltic activity. No masses or focal lesions were observed.

The visualized areas of duodenum, jejunum and ileum have a relatively uniform diameter with moderate fluid distension. Wall thickness is normal. Bowel loops follow a curvilinear path with distinct wall layering maintaining the typical 1:3 muscularis:mucosa layer ratio. The duodenum measured as normal (between 0.13-0.38cm in wall thickness) and the jejunum measured as normal (between 0.15-0.36cm.) Visualized peristalsis appears appropriate. There were no focal lesions consistent with obstruction or a mass effect observed.

The ileocecal junction was visualized and exhibited normal intact wall layering. It is located distally in the abdomen, creating the appearance of a short colon. Some of the areas of colon exhibit increased wall thickness, measuring 0.31 cm with intact wall layering. Findings are suggestive of short bowel syndrome.

Pancreas

The pancreas is prominent and hypoechoic as compared to the surrounding isoechoic mesentery. There is no evidence of nodules or cystic lesions. There is no evidence of regional mesenteric inflammation or fluid. Prominent pancreatic duct noted.

Free Abdomen

Evaluation of the peritoneal cavity did not reveal any evidence of effusion, or subjective lymphadenomegaly. The Medial iliac nodes appear normal and there was no evidence of a caudal aortic thrombus at the bifurcation. The omentum is of normal uniform echogenicity.

ULTRASONOGRAPHIC FINDINGS

- Prominent, hypoechoic pancreas with prominent pancreatic duct – The pancreatic changes are most consistent with mild pancreatitis or a recent episode of pancreatic inflammation.
- Hyperechoic liver nodules – These nodules could represent either a benign or neoplastic process. In general, hyperechoic nodules trend towards a more benign behavior, but in a cat all hepatic nodules are concerning.
- Large stomach dilated with ingesta – Per the history, this patient was adequately fasted. Possible differentials include delayed gastric emptying, or a partial gastric outflow obstruction (none visualized).
- Short colon with increased wall thickness and intact layering – Findings are most consistent with colitis (inflammatory/infectious), but an underlying neoplastic etiology cannot be ruled out.

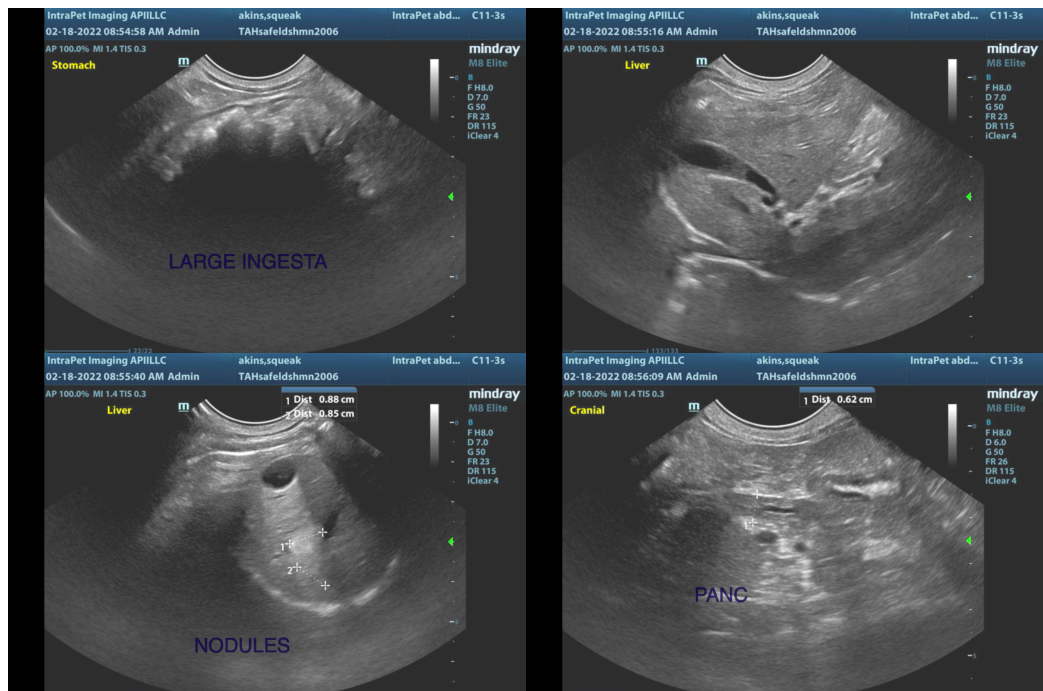
INTERPRETATION OF THE FINDINGS & FURTHER RECOMMENDATIONS

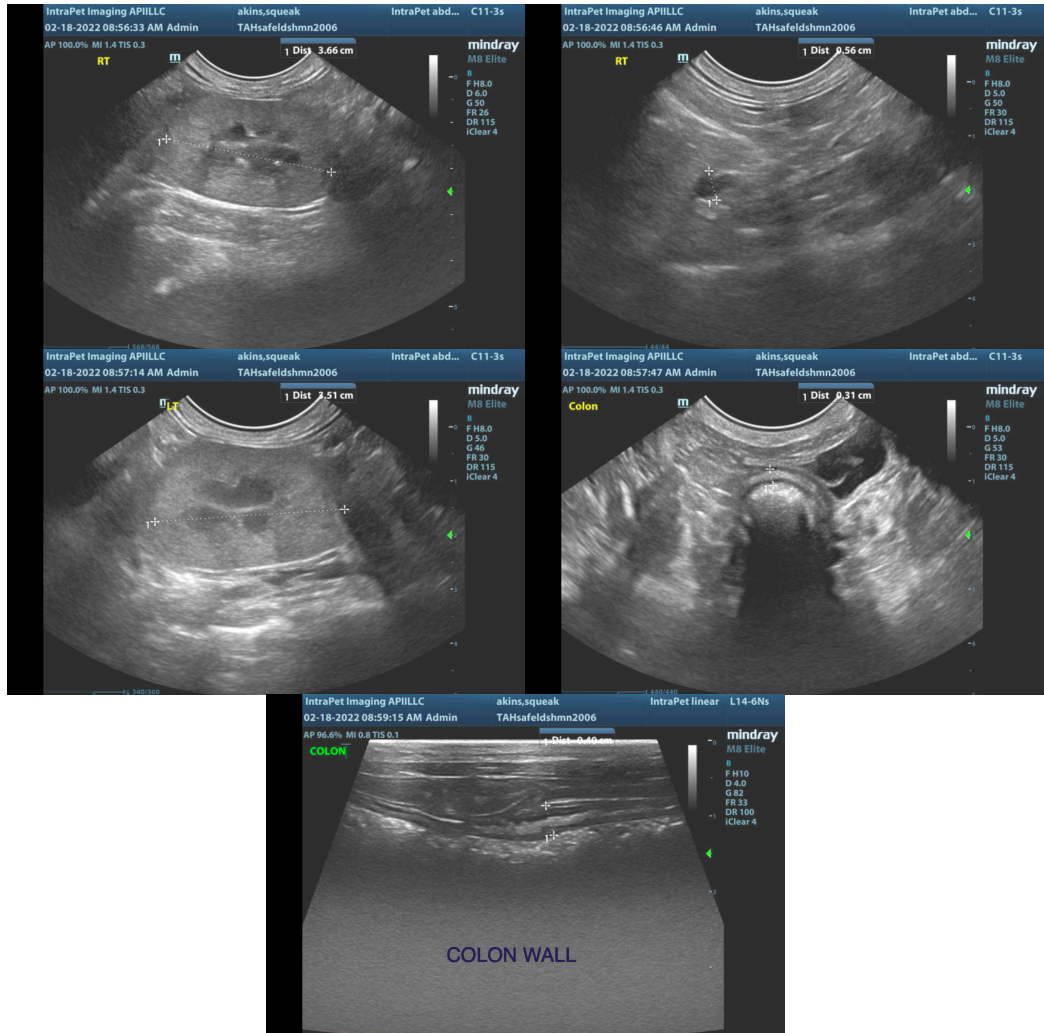
It is likely that this cat has both large and small bowel GI disease, based on the history of chronic Prednisone use and B12 supplementation. Additionally, the colon does appear somewhat thickened on today's scan. You've done a good job with initial workup, and differentials such as exocrine pancreatic insufficiency, etc. are unlikely. Unfortunately, at this point, you are mostly left with experimentation as far as diet. You could consider options such as novel protein, hydrolyzed protein, high fiber, low fiber, low-fat, etc. Ideally, I would consider trying to obtain endoscopic biopsies of the colon and small bowel to try to confirm there is not an evolving neoplastic process present. If you decide to obtain biopsies, try to taper to at least a lower dose of Prednisone.

Additionally, the stomach is very distended. I suspect this is secondary to ileus and underlying gastrointestinal disease, but a partial obstruction is always possible. Consider a low-dose motility medication, but watch for the possibility of worsening diarrhea.

There are hyperechoic nodules visualized within the liver. These could represent benign changes or even metastatic disease. Consider fine needle aspirate of the liver and 3-view thoracic radiographs.

I suspect there are many cats with short bowel syndrome that do not have underlying GI disease, but without an effective redundancy of colon, GI symptoms are worse and become apparent sooner, as the colon's ability to absorb fluids diminishes. I would treat this cat similarly to a normal cat with chronic mixed bowel diarrhea and gastric distention with the knowledge that it may be more challenging to treat.





The information and recommendations provided are based on the images presented by the referring veterinarian/sonographer. No evaluation can be communicated regarding pathology that was not visible in the image/video clips provided.

Thank you for this referral. If the clinical or image interpretation does not parallel your findings or if I can be of any further assistance please contact me.

Kathleen Sennello DVM,MS, Diplomate ACVIM (Small animal Internal Medicine)
kathleen.sennello@sonopath.com