

**DATE PRESENTING CLINICAL SIGNS**

2/18/22

History: 2/10/22: Weight loss and diarrhea since mid-December. PE: slightly pale mucous membranes. Mild tartar. ~5% dehydrated. BCS 4/9. Dried liquid stool over tail and rear. Administered LRS 100ml SC at exam.

PATIENT

Sam Roche

Current Medications: Metronidazole (100mg/ml): Give 0.4ml PO BID x 7 days since 2/10/22.

Lab Results: Bloodwork 2/10/22 - CBC: Mild normocytic, normochromic, non-regenerative anemia (HCT 25.5%). Moderate leukocytosis 32.3K/uL Ddx: inflammation, infection, neoplasia, stress. Moderate neutrophilia 26.163K/uL Ddx: infection, inflammation, neoplasia, stress. Moderate monocytosis 2.5K/uL Ddx: infection, inflammation, neoplasia stress. Chemistry: Mild hypoalbuminemia 2.4g/dL Ddx: liver disease, maldigestion, inflammation, PLE. ALKP 342U/L Ddx: liver disease, biliary disease. UA (cysto): USG 1.052, pH 6.5, 2+ protein, inactive sediment. T4: 1.9ug/dL.

SPECIES

Feline

BREED

DSH

Date of Previous IntraPet Ultrasound: No previous IntraPet scans.

Sedation: Not required to complete full diagnostic ultrasound.

Stat Report: Not requested.

SEX

Neutered Male

ULTRASONOGRAPHIC EXAMINATION OF THE ABDOMEN**Urinary System**

The urinary bladder is moderately distended with anechoic urine. The Bladder wall, trigone, ureteral papillae and visible urethra (to a depth of 2cm) appear normal with no evidence of wall thickening, mucosal irregularities, masses or cystic calculi.

AGE

3/13/10

The left kidney has a normal shape and size (3.53 cm). Overall echogenicity is normal with adequate corticomedullary distinction and a typical 1:3 cortex:medulla ratio. There is no evidence of perinephric inflammation or effusion. There is no evidence of pyelectasia, nephroliths, infarcts or hydroureter. Renal vasculature is normal.

WEIGHT

9 Pounds

The right kidney has a normal shape and size (3.63 cm). Overall echogenicity is normal with adequate corticomedullary distinction and a typical 1:3 cortex:medulla ratio. There is no evidence of perinephric inflammation or effusion. There is no evidence of pyelectasia, nephroliths, infarcts or hydroureter. Renal vasculature is normal.

INTERPRETED BY

Kathleen Sennello DVM,
MS, Diplomate ACVIM
(Small Animal Internal
Medicine)

Adrenal Glands

The left adrenal gland is normal in size measuring 0.31 cm at the caudal pole. It is observed in its normal position cranial to the left renal artery. It is normal in appearance (uniformly hypoechoic) and shape with no evidence of a mass effect.

IMAGING PERFORMED BY

Andi Parkinson RDMS

The right adrenal gland is normal in size measuring 0.45 cm at the caudal pole. It is observed in its normal position between the cranial aspect of the right kidney and the caudal vena cava. It is normal in appearance (uniformly hypoechoic) and shape with no evidence of a mass effect.

HOSPITAL NAME

Timonium AH

REFERRING VET

Dr. Falkowski

Spleen

The spleen is subjectively normal in size, echotexture is homogenous, and the splenic capsule is smooth with no irregularities. The blood flow through the hilus and splenic parenchyma appears normal. No focal parenchymal abnormalities are visualized.

INVOICE

35764

Liver

The liver is subjectively normal in size, and echogenicity with smooth peripheral margins. The parenchyma is mildly heterogenous in echotexture with subtle, indistinct focal mottling. The visible portions of the vasculature and biliary tract appear normal. There is an irregular hypoechoic cystic structure visualized on the right side of the liver, measuring 2.3 cm x 1.17 cm. Additionally, there are mixed echogenicity hyperechoic mass lesions measuring 0.95 cm and 1.62 cm.

The gallbladder lumen is moderately distended. The wall of the gall bladder is not thickened and has a smooth mucosal surface. Luminal contents are primarily anechoic. The cystic and common bile ducts are normal/not visible.

Gastrointestinal

The stomach contains minimal luminal contents. It measures at a normal thickness of <0.36cm with some variability due to the presence of rugal folds. The distinction of the gastric wall layers is adequate and there is no impression of reduced peristaltic activity. No masses or focal lesions were observed.

The visualized areas of duodenum, jejunum and ileum have a relatively uniform diameter with minimal fluid distension. Wall thickness is normal. Bowel loops follow a curvilinear path with distinct wall layering maintaining the typical 1:3 muscularis:mucosa layer ratio. The duodenum measured as normal (between 0.13-0.38cm in wall thickness) and the jejunum measured as normal (between 0.15-0.36cm.) Visualized peristalsis appears appropriate. There were no focal lesions consistent with obstruction or a mass effect observed.

The ileocecal junction was visualized and appears relatively normal. Other sections of colon are visualized, particularly the mid descending and distal colon where there is severe wall thickening and irregularity with complete loss of layering, creating a mass effect. In these areas, the colon wall measures approximately 1.03 cm in thickness with colon diameter of over 2.05 cm. Mesentery is hyperechoic around these abnormal areas of colon.

Pancreas

The pancreas is normal and isoechoic to surrounding mesentery. There is no evidence of nodules or cystic lesions. There is no evidence of regional mesenteric inflammation or fluid.

Free Abdomen

There is a small volume of free abdominal fluid. There are occasional prominent mesenteric lymph nodes visualized. The omentum is of increased echogenicity, particularly around the abnormal areas of colon.

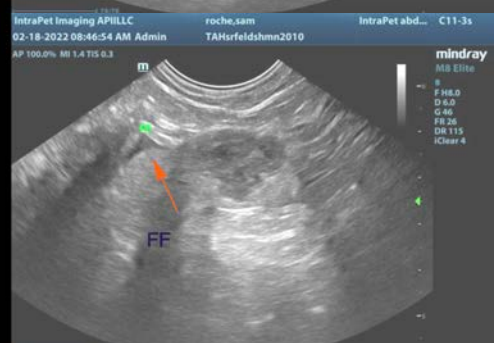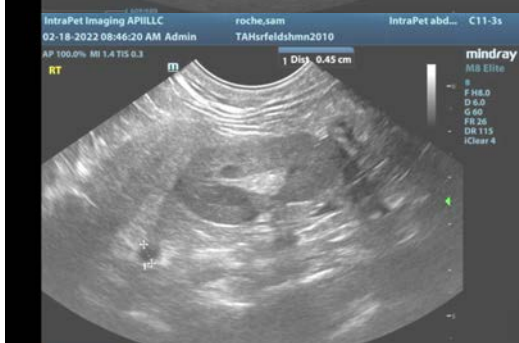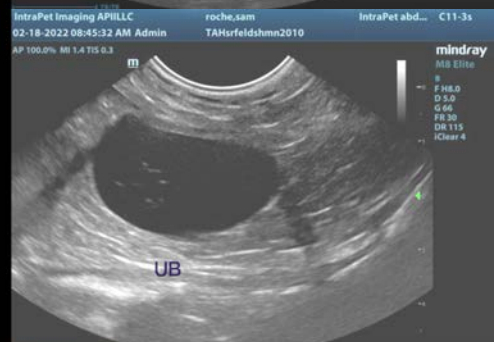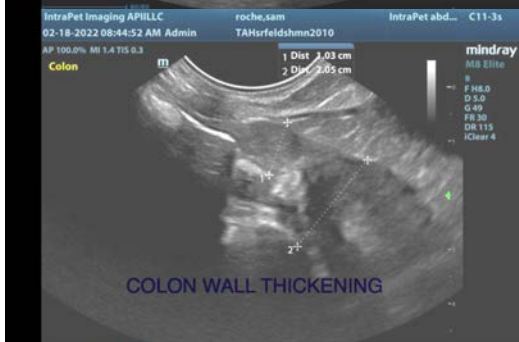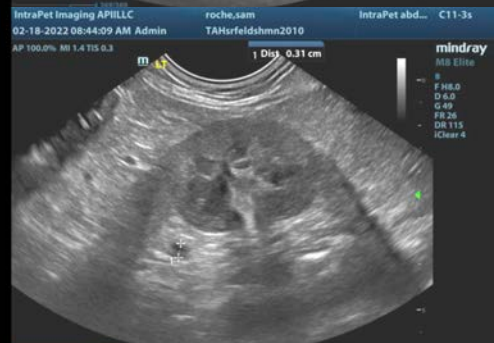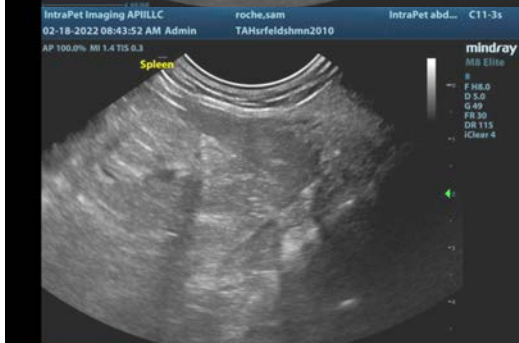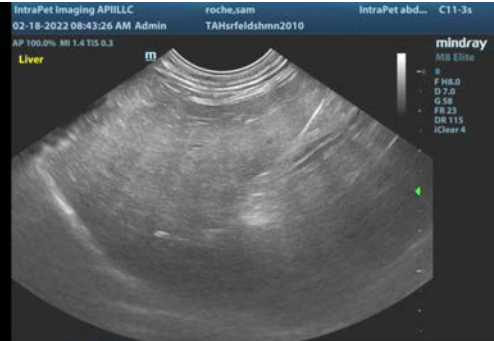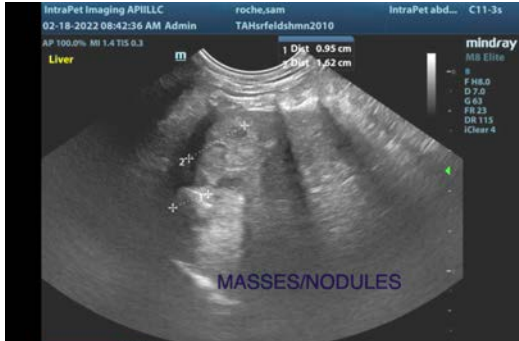ULTRASONOGRAPHIC FINDINGS

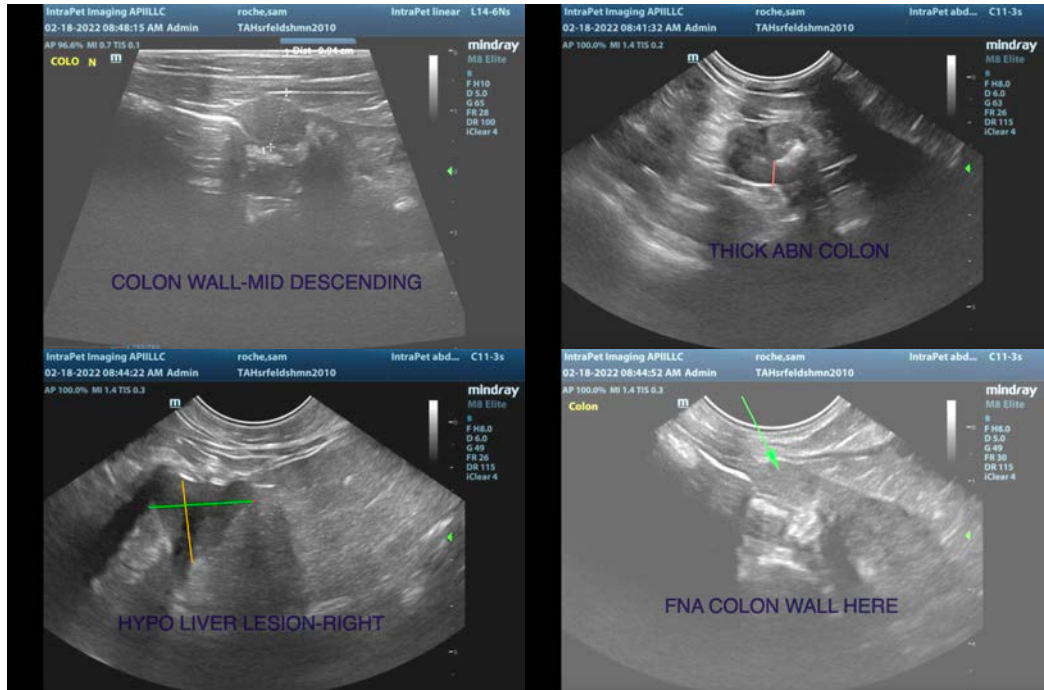
- Heterogeneous liver with cystic area and hyperechoic mixed echogenicity mass lesions – Hepatic changes are non-specific and could be consistent with inflammation/infection (cholangiohepatitis), infiltrative neoplasia, lipidosis or other hepatopathy. The mass lesions could represent either benign or neoplastic change. The possibility of a metastatic lesion exists.
- Focal wall thickening and loss of layering in the distal and descending colon – Findings are most consistent with infiltrative disease to the colon wall. Primary differential would be neoplasia. Other possibilities include FIP, granulomatous disease, severe inflammation, etc.

INTERPRETATION OF THE FINDINGS & FURTHER RECOMMENDATIONS

There is severe colon wall thickening involving an extensive portion of the colon. In these areas, the wall is irregular with complete loss of layering, creating a mass effect. Additionally, there are mass lesion within the liver. These could represent metastatic lesions or be non-related. Consider a fine needle aspirate of the colon wall and possibly liver nodules.

Consider three view thoracic radiographs to rule out concurrent thoracic disease/involvement.





The information and recommendations provided are based on the images presented by the referring veterinarian/sonographer. No evaluation can be communicated regarding pathology that was not visible in the image/video clips provided.

Thank you for this referral. If the clinical or image interpretation does not parallel your findings or if I can be of any further assistance please contact me.

Kathleen Sennello DVM,MS, Diplomate ACVIM (Small animal Internal Medicine)
kathleen.sennello@sonopath.com