



PATIENT

Oscar Anderson

SPECIES

Feline

BREED

DSH

SEX

Neutered Male

AGE

2 Years

WEIGHT

5 kg

INTERPRETED BY

Kathleen Sennello DVM,
MS, Diplomate ACVIM
(Small Animal Internal
Medicine)

**IMAGING
PERFORMED BY**

Dr. Callihan

HOSPITAL NAME

Pacific Crest Mobile

REFERRING VET

Dr. Sanders - Skagit AC

INVOICE

35751

DATE

2/18/22

PRESENTING CLINICAL SIGNS

On yearly exam 1/6/22, pt had small palpable soft tissue mass mid to caudal abd that was about 2 cm diam; on recheck 2/16 mass was much larger and pt had become much quieter, sleeping a lot, not sure about appetite, but 1 kg weight loss in past 5 weeks;

Abnormal PE/Chem/CBC/UA Results: Radiographs: -ill-defined lobular soft tissue mass mis abd with regional peritonitis/effusion. Suspected to be intestinal in origin -possible sternal lymphadenopathy
Labs 2/14/22 -CBC normal other than elev PLT -chems w mild elev SDMA -hypoproteinemia TP 4.9, ALb 2.1, glob 2.8 -urine is concentrated 1.044, prot 2+ with UPC 0.7 (ref <0.4) -FeLV/FIV neg, coronavirus ab by IFA is pending

ULTRASONOGRAPHIC EXAMINATION OF THE ABDOMEN

Urinary System

The urinary bladder is moderately distended with mild primarily suspended echogenic debris present. The Bladder wall, trigone, ureteral papillae and visible urethra (to a depth of 2cm) appear normal with no evidence of wall thickening, mucosal irregularities, masses or calculi. Echogenic debris of this type can be associated with small crystals, cellular debris and proteinaceous debris.

The left kidney is somewhat irregular in shape and borderline large in size at 4.72 cm. Overall, echogenicity is increased with slightly reduced corticomedullary distinction. There is a subtle 1.3 cm x 1.5 cm isoechoic nodule visualized within the cortex on the cross sectional view. There is no evidence of pyelectasia, nephroliths, infarcts or hydroureter. Renal vasculature is normal.

The right kidney is somewhat irregular in shape and borderline large in size at 4.97 cm. Overall, echogenicity is increased with slightly reduced corticomedullary distinction. There is no evidence of pyelectasia, nephroliths, infarcts or hydroureter. Renal vasculature is normal.

Adrenal Glands

The region of left adrenal (Cranial to left renal artery) is unremarkable but the adrenal is not distinctly visualized. No evidence of a mass effect.

The region of the right adrenal (between right cranial kidney and vena cava) is unremarkable, but the adrenal is not distinctly visualized. No evidence of a mass effect.

Spleen

The spleen is subjectively normal in size. The spleen echotexture is heterogenous and mildly mottled, the splenic capsule is smooth with no irregularities. The blood flow through the hilus and splenic parenchyma appears normal. No focal parenchymal abnormalities are visualized.

Liver

The liver is subjectively normal in size, and hypoechoic with smooth peripheral margins. The parenchyma is heterogenous in echotexture with subtle, indistinct focal mottling. The visible portions of the vasculature and biliary tract appear normal. No focal nodules or cystic lesions are observed.

The gallbladder lumen is moderately distended. The wall of the gall bladder is not thickened and has a smooth mucosal surface. Luminal contents are primarily anechoic. The cystic and common bile ducts are normal/not visible.



PATIENT

Gastrointestinal

Oscar Anderson

The stomach contains minimal luminal contents. It measures at a normal thickness of <0.36cm with some variability due to the presence of rugal folds. The distinction of the gastric wall layers is adequate and there is no impression of reduced peristaltic activity. No masses or focal lesions were observed.

SPECIES

Feline

The visualized areas of duodenum, jejunum and ileum have a uniform diameter with minimal fluid distension. Wall thickness is normal to slightly increased. Bowel loops follow a typical curvilinear path with distinct wall layering, but some areas display a prominent muscularis layer which does not display the typical 1:3 muscularis:mucosa layer ratio. Jejunum wall measured 0.26 cm. Visualized peristalsis appears appropriate. There is a very large, irregular, hypoechoic bowel mass visualized in the cranial to mid abdomen. This mass effect is greater than 7.6 cm x 5.1 cm and it is expansile. In the areas involving bowel directly, wall thickness is approximately 1.8 cm with the diameter of the bowel measuring at 3.4 cm with a complete loss of layering and hypoechoic wall.

BREED

DSH

SEX

Neutered Male

The ileocecal junction was visualized and exhibited normal intact wall layering and is subjectively of normal thickness. Sections of colon are visualized with formed fecal material and gas shadowing distally. There is no observed focal or generalized colon wall thickening or loss of layering.

AGE

2 Years

Pancreas

The pancreas is normal and isoechoic to surrounding mesentery. There is no evidence of nodules or cystic lesions. There is no evidence of regional mesenteric inflammation or fluid.

WEIGHT

5 kg

Free Abdomen

Evaluation of the peritoneal cavity did not reveal any evidence of effusion, or subjective lymphadenomegaly. The Medial iliac nodes appear normal and there was no evidence of a caudal aortic thrombus at the bifurcation. The omentum is of increased echogenicity around the abdominal mass.

INTERPRETED BY

Kathleen Sennello DVM,
MS, Diplomate ACVIM
(Small Animal Internal
Medicine)

PRIMARY FINDINGS

- Isoechoic nodule in the cortex of the left kidney – This could be a neoplastic or benign lesion.
- Heterogeneous, hypoechoic liver – Hepatic changes are non-specific and could be consistent with inflammation/infection (cholangiohepatitis), infiltrative neoplasia, lipidosis or other hepatopathy. Cytology was consistent with a vacuolar hepatopathy and inflammation.
- Large, expansile bowel/abdominal mass – Visual appearance is most consistent with round cell neoplasia. FIP and carcinoma would be alternate diagnoses. Cytology is suggestive of lymphoma, but FIP cannot be excluded as a possibility.
- Mottled spleen – The diffuse splenic changes are non-specific and could be consistent with lymphoid hyperplasia, extramedullary hematopoiesis, infiltrative neoplasia, inflammation, other. Cytology or histopathology would be necessary to get a definitive diagnosis. Cytology is suggestive of lymphoma.

IMAGING PERFORMED BY

Dr. Callihan

HOSPITAL NAME

Pacific Crest Mobile

REFERRING VET

Dr. Sanders – Skagit AC

INVOICE

35751

DATE

2/18/22

SECONDARY FINDINGS

- Echogenic debris in the urinary bladder – The echogenic debris in the bladder lumen could be consistent with cells, crystals, and/or mucus.



PATIENT

Oscar Anderson

SPECIES

Feline

BREED

DSH

SEX

Neutered Male

AGE

2 Years

WEIGHT

5 kg

INTERPRETED BY

Kathleen Sennello DVM,
MS, Diplomate ACVIM
(Small Animal Internal
Medicine)

**IMAGING
PERFORMED BY**

Dr. Callihan

HOSPITAL NAME

Pacific Crest Mobile

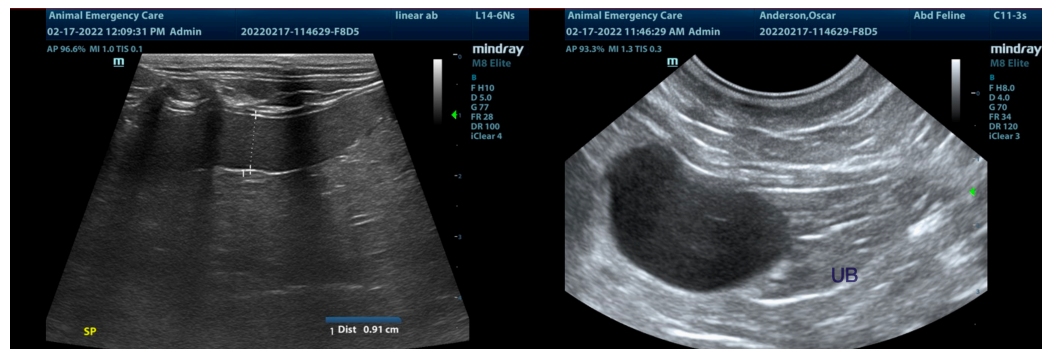
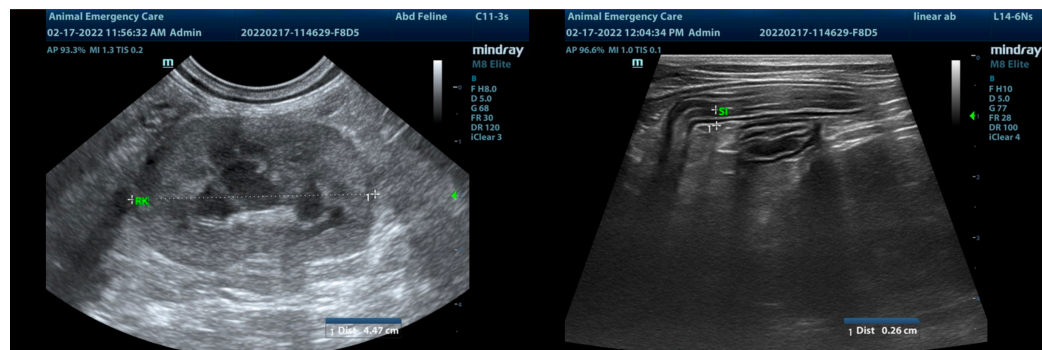
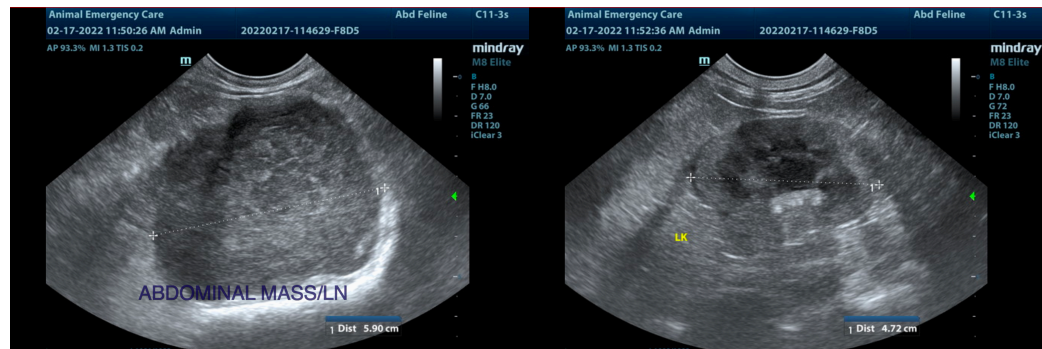
REFERRING VET

Dr. Sanders - Skagit AC

INTERPRETATION OF THE FINDINGS & FURTHER RECOMMENDATIONS

There is a large bowel mass and abdominal mass. I suspect these are coalescing into a large mass, but two separate masses is also possible. Based on cytologic findings and ultrasound findings, I feel that round cell neoplasia is the primary differential, but unfortunately FIP cannot be excluded as a differential. Recommend consultation with a veterinary oncologist regarding options for PARR testing, etc.

Consider three view thoracic radiographs to rule out concurrent thoracic disease/involvement.



INVOICE

35751

DATE

2/18/22



PATIENT

Oscar Anderson

SPECIES

Feline

BREED

DSH

SEX

Neutered Male

AGE

2 Years

WEIGHT

5 kg

INTERPRETED BY

Kathleen Sennello DVM,
MS, Diplomate ACVIM
(Small Animal Internal
Medicine)

**IMAGING
PERFORMED BY**

Dr. Callihan

HOSPITAL NAME

Pacific Crest Mobile

REFERRING VET

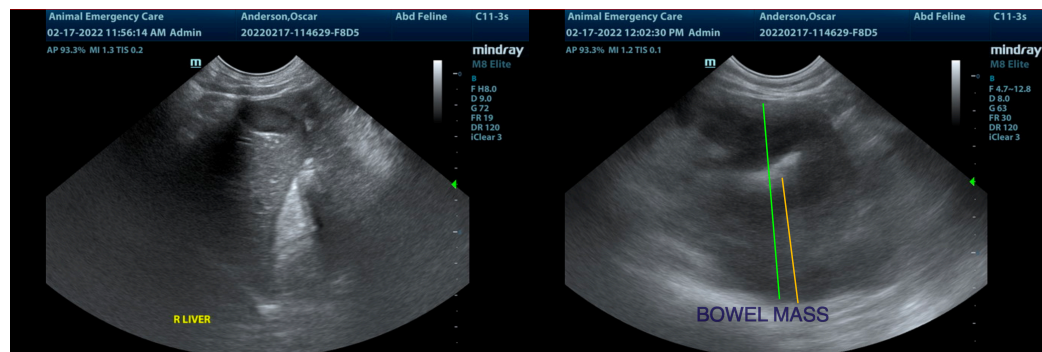
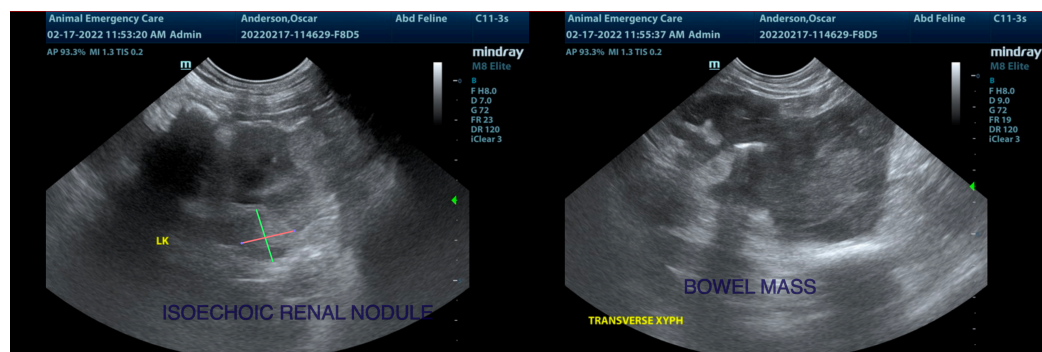
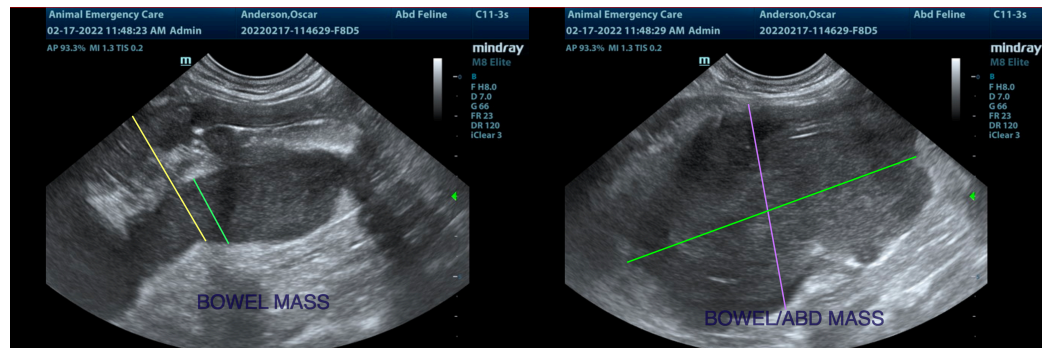
Dr. Sanders - Skagit AC

INVOICE

35751

DATE

2/18/22



The information and recommendations provided are based on the images presented by the referring veterinarian/sonographer. No evaluation can be communicated regarding pathology that was not visible in the image/video clips provided.

Thank you for this referral. If the clinical or image interpretation does not parallel your findings or if I can be of any further assistance please contact me.

Kathleen Sennello DVM,MS, Diplomate ACVIM (Small animal Internal Medicine)

kathleen.sennello@sonopath.com