

**PATIENT**

Louie Frank

**SPECIES**

Feline

**BREED**

Domestic Shorthair

**SEX**

MN

**AGE**

14 Years, 8 Months

**WEIGHT**

10.5lbs

**INTERPRETED BY**

Kathleen Sennello DVM,  
MS, Diplomate ACVIM  
(Small Animal Internal  
Medicine)

**IMAGING  
PERFORMED BY**

Carly Pate

**HOSPITAL NAME**

VCA McKenzie Animal  
Hospital

**REFERRING VET**

Dr. Arpaia

**INVOICE**

50393

**DATE**

2-18-22

**PRESENTING CLINICAL SIGNS**

Louie ingested/chewed on a peace lilly on 02/01/22. Since then we have been closely monitoring labwork and did SQF daily for 3 days. Ongoing progression of ALT elevation since lily ingestion R/O ongoing oxidative injury vs. other hepatocellular injury. Ongoing progressive elevation of BUN and SDMA R/O renal injury from lily ingestion. At home Louie has been acting normally, E/D well, no reported vomiting. No change in urinary or defecation habits. P has been started on Standard Process Hepatrophin and Hepatic Support.

Abnormal PE/Chem/CBC/UA Results: 2/8/22 labwork SDMA - 2/7/22 SDMA 22 (<15) 2/3/22 SDMA 19.6 (<15); Chemistry profile - Vetscreen: wnl except - ALT 375 (10-100) - previously 210 on in house labs on 2/3/22 - BUN 38 (14-36) 2/2/22 SDMA - SDMA 19.6 (<15) 2/1/22 CREA 1.7, BUN 33, ALT 211, AMY 1406, CBC WNL

**ULTRASONOGRAPHIC EXAMINATION OF THE ABDOMEN**

**Urinary System**

The urinary bladder is moderately distended with anechoic urine. The bladder wall, trigone, ureteral papillae and visible urethra (to a depth of 2cm) appear normal with no evidence of wall thickening, mucosal irregularities, masses or cystic calculi.

The left kidney has a normal shape and size (3.53cm). It has a significantly hyperechoic cortex with mildly reduced corticomedullary distinction and medullary rim sign. There is no evidence of perinephric inflammation or effusion. There is no evidence of pyelectasia, nephroliths, infarcts or hydronephrosis. Renal vasculature is normal.

The right kidney has a normal shape and size (3.88cm). It has a significantly hyperechoic cortex with mildly reduced corticomedullary distinction and medullary rim sign. There is no evidence of perinephric inflammation or effusion. There is no evidence of pyelectasia, nephroliths, infarcts or hydronephrosis. Renal vasculature is normal.

**Adrenal Glands**

The region of left adrenal (Cranial to left renal artery) is unremarkable, but the adrenal is not distinctly visualized. No evidence of a mass effect.

The region of the right adrenal (between right cranial kidney and vena cava) is unremarkable, but the adrenal is not distinctly visualized. No evidence of a mass effect.

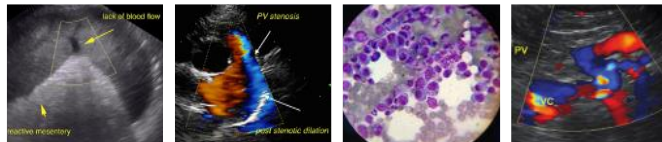
**Spleen**

The spleen is borderline enlarged measuring 1.06 cm in height at the level of the hilus. The spleen echotexture is heterogenous and mildly mottled, the splenic capsule is smooth with no irregularities. The blood flow through the hilus and splenic parenchyma appears normal. No focal parenchymal abnormalities are visualized.

**Liver**

The liver is subjectively normal in size, and echogenicity with smooth peripheral margins. The parenchyma is homogenous echotexture. The visible portions of the vasculature and biliary tract appear normal. No focal nodules or cystic lesions are observed. The gallbladder lumen is moderately distended. The wall of the gall bladder is not thickened and has a smooth mucosal surface. Luminal contents are primarily anechoic. The cystic and common bile ducts are normal/not visible.

**Gastrointestinal**



**PATIENT**

Louie Frank

The stomach contains minimal luminal contents. It measures at a normal thickness of <0.36cm with some variability due to the presence of rugal folds. The distinction of the gastric wall layers is adequate and there is no impression of reduced peristaltic activity. No masses or focal lesions were observed.

**SPECIES**

Feline

The visualized areas of duodenum, jejunum and ileum have a relatively uniform diameter with minimal fluid distension. Wall thickness is normal. Bowel loops follow a curvilinear path with distinct wall layering maintaining the typical 1:3 muscularis:mucosa layer ratio. The duodenum measured as normal (between 0.13-0.38cm in wall thickness) and the jejunum measured as normal (0.27cm.) Visualized peristalsis appears appropriate. There were no focal lesions consistent with obstruction or a mass effect observed.

**BREED**

Domestic Shorthair

The ileocecal junction was visualized and exhibited normal intact wall layering and is subjectively of normal thickness. Sections of colon are visualized with formed fecal material and gas shadowing distally. There is no observed focal or generalized colon wall thickening or loss of layering.

**SEX**

MN

***Pancreas***

The pancreas is normal and isoechoic to surrounding mesentery. There is no evidence of nodules or cystic lesions. There is no evidence of regional mesenteric inflammation or fluid.

**AGE**

14 Years, 8 Months

***Free Abdomen***

Evaluation of the peritoneal cavity did not reveal any evidence of effusion, or subjective lymphadenomegaly (list if measurements given). The Medial iliac nodes appear normal and there was no evidence of a caudal aortic thrombus at the bifurcation. The omentum is of normal uniform echogenicity.

**WEIGHT**

10.5lbs

**ULTRASONOGRAPHIC FINDINGS**

**INTERPRETED BY**

Kathleen Sennello DVM,  
MS, Diplomate ACVIM  
(Small Animal Internal  
Medicine)

**Primary**

- Hyperechoic kidneys with mildly reduced corticomedullary distinction and corticomedullary rim sign. Mild loss of corticomedullary distinction in both kidneys could be consistent with chronic degenerative disease or interstitial nephrosis. Clinical significance uncertain, can be seen in normal patients and in cases of ethylene glycol toxicity, FIP, chronic interstitial nephritis, and leptospirosis.
- Subjectively large, mottled spleen. The diffuse splenic changes are non-specific and could be consistent with lymphoid hyperplasia, extramedullary hematopoiesis, infiltrative neoplasia, inflammation, other. Cytology or histopathology would be necessary to get a definitive diagnosis. These changes are mild and could be normal for a larger cat. Consider fine needle aspirate if further evaluation is desired.

**IMAGING PERFORMED BY**

Carly Pate

**HOSPITAL NAME**

VCA McKenzie Animal  
Hospital

**REFERRING VET**

Dr. Arpaia

**INTERPRETATION OF THE FINDINGS & FURTHER RECOMMENDATIONS**

No focal lesions are observed in the liver or kidneys which is to be expected in most cases of toxicity. If not already done, consider blood pressure evaluation, urinalysis, and culture to ensure there are no concurrent issues (as well as thyroid evaluation).

**INVOICE**

50393

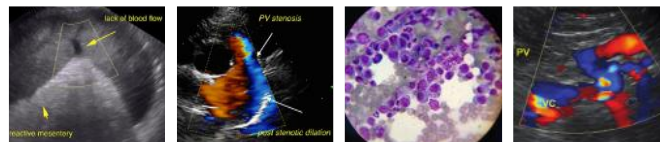
If liver values continue to rise, consider liver function test and a fine needle aspirate of the liver as long as coagulation parameters are normal.

Consider three view thoracic radiographs to rule out concurrent thoracic disease/involvement.

**DATE**

2-18-22

This cat is relatively large, so the significance of the splenic changes is uncertain. Consider a fine needle aspirate if further evaluation is desired.



**PATIENT**

Louie Frank

**SPECIES**

Feline

**BREED**

Domestic Shorthair

**SEX**

MN

**AGE**

14 Years, 8 Months

**WEIGHT**

10.5lbs

**INTERPRETED BY**

Kathleen Sennello DVM,  
MS, Diplomate ACVIM  
(Small Animal Internal  
Medicine)

**IMAGING  
PERFORMED BY**

Carly Pate

**HOSPITAL NAME**

VCA McKenzie Animal  
Hospital

**REFERRING VET**

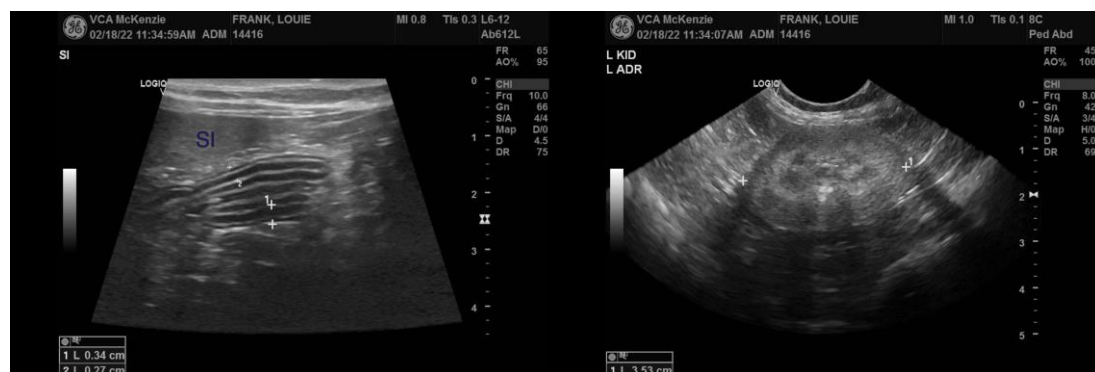
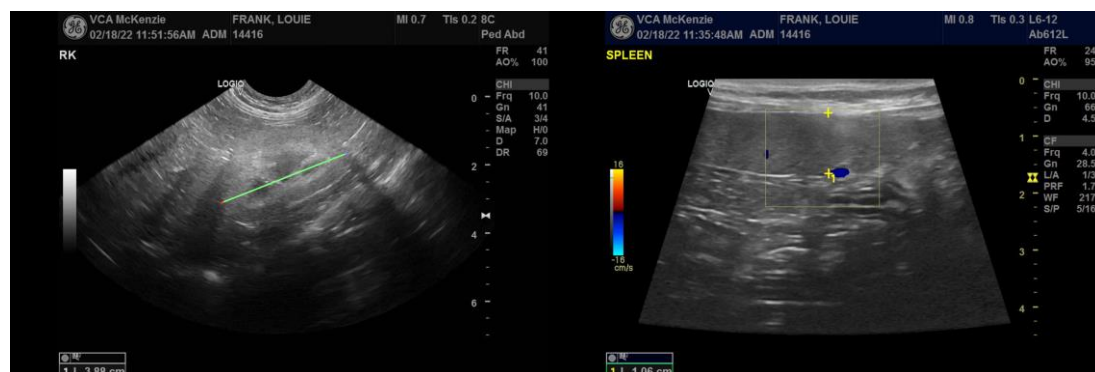
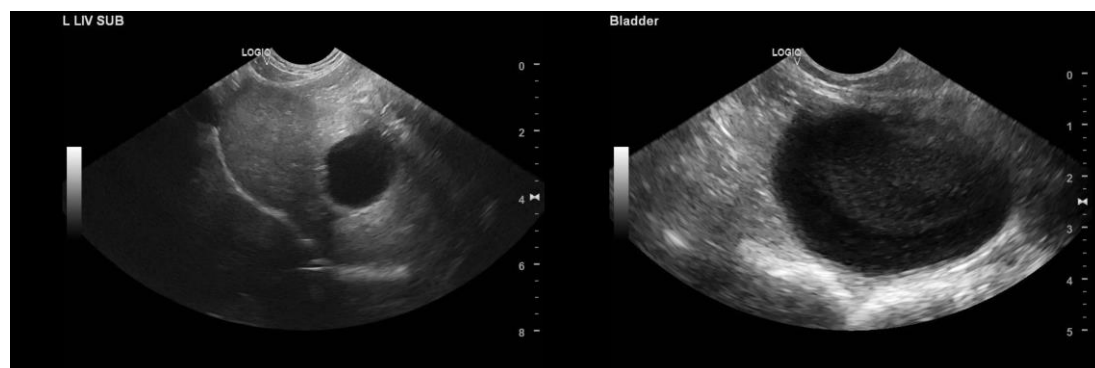
Dr. Arpaia

**INVOICE**

50393

**DATE**

2-18-22



The information and recommendations provided are based on the images presented by the referring veterinarian/sonographer. No evaluation can be communicated regarding pathology that was not visible in the image/video clips provided.

Thank you for this referral. If the clinical or image interpretation does not parallel your findings or if I can be of any further assistance please contact me.

Kathleen Sennello DVM,MS, Diplomate ACVIM (Small animal Internal Medicine)  
kathleen.sennello@sonopath.com