

**DATE PRESENTING CLINICAL SIGNS**

2/18/22 Admitted 2/17/22, acute onset anorexia. Visible icterus seems lethargic. Concern for gall bladder halo sign on in house ultrasound.

**PATIENT**

Katie Hodski

Current Medications: Ampicillin, Cerenia.  
 Lab work: Bilirubin 19, AP 1766, PCV 69, ALT 495, GGT 50  
 Date of Previous IntraPet Ultrasound: No previous  
 Sedation: Not required to complete full diagnostic ultrasound.  
 Stat Report: DVM requested stat.

**SPECIES**

Canine

**ULTRASONOGRAPHIC EXAMINATION OF THE ABDOMEN****BREED**

Shih Tzu X

**Urinary System**

The urinary bladder is moderately distended with anechoic urine. The Bladder wall, trigone, ureteral papillae and visible urethra (to a depth of 2cm) appear normal with no evidence of wall thickening, mucosal irregularities, masses or cystic calculi.

**SEX**

Spayed Female

The left kidney has a normal shape and size (5.23 cm). Overall echogenicity is normal with adequate corticomedullary distinction and a typical 1:3 cortex:medulla ratio. There is no evidence of perinephric inflammation or effusion. There is no evidence of pyelectasia, nephroliths, infarcts or hydroureter. Renal vasculature is normal.

**AGE**

12/4/12

The right kidney has a normal shape and size (5.39 cm). Overall echogenicity is normal with adequate corticomedullary distinction and a typical 1:3 cortex:medulla ratio. There is no evidence of perinephric inflammation or effusion. There is no evidence of pyelectasia, nephroliths, infarcts or hydroureter. Renal vasculature is normal.

**WEIGHT**

20.4 Pounds

**INTERPRETED BY**

Kathleen Sennello DVM,  
 MS, Diplomate ACVIM  
 (Small Animal Internal  
 Medicine)

**Adrenal Glands**

The left adrenal gland is normal/borderline large in size measuring 0.70 cm at the caudal pole. It is observed in its normal position cranial to the left renal artery. It is normal in appearance (uniformly hypoechoic) and shape with no evidence of a mass effect.

**IMAGING PERFORMED BY**

Andi Parkinson RDMS

The right adrenal gland is normal/borderline large in size measuring 0.80 cm at the caudal pole. It is observed in its normal position between the cranial aspect of the right kidney and the caudal vena cava. It is normal in appearance (uniformly hypoechoic) and shape with no evidence of a mass effect.

**HOSPITAL NAME**

Everhart Vet Hospital

**Spleen**

The spleen is subjectively normal in size and the echotexture is homogenous. The splenic capsule is smooth with no visible irregularities. Rare discrete focal hyperechoic, perivascular parenchymal abnormalities are present. The appearance of these lesions is most consistent with benign splenic myelolipomas. The blood flow through the hilus and splenic parenchyma appears normal.

**REFERRING VET****Liver**

The liver is subjectively normal in size, and is hypoechoic with smooth peripheral margins. The parenchyma is heterogenous in echotexture with subtle, indistinct focal mottling. The visible portions of the vasculature and biliary tract appear normal. No focal nodules or cystic lesions are observed.

**INVOICE**

35726

The gallbladder lumen is significantly distended. The wall is diffusely thickened with a double wall and "halo" sign, most consistent with intramural edema. There are irregular polypoid projections arising from the gallbladder wall, and a relatively mild amount of non-organized echogenic debris. The gallbladder is surrounded by free fluid and cranial abdominal inflammation.

### ***Gastrointestinal***

The stomach contains minimal luminal contents. It measures at an increased thickness of 1.48 with diffuse gastric wall mottling and irregularity. Additionally, there appears to be a focal area of hypoechoic wall, which measures 2.1 cm thick with a lack of normal gastric wall layering. This area could be consistent with a focal mass effect, ulcer, etc. The stomach is surrounded by hyperechoic mesentery and free fluid.

The visualized areas of duodenum, jejunum and ileum have a relatively uniform diameter with minimal fluid distension. Wall thickness is normal. Bowel loops follow a curvilinear path with distinct wall layering maintaining the typical 1:3 muscularis:mucosa layer ratio. The duodenum measured as normal (between 0.3-0.5cm in wall thickness) and the jejunum measured as normal (between 0.2-0.47cm.) Visualized peristalsis appears appropriate. There were no focal lesions consistent with obstruction or a mass effect observed.

The ileocecal junction was visualized and exhibited normal intact wall layering and is subjectively of normal thickness. Sections of colon are visualized with formed fecal material and gas shadowing distally. There is no observed focal or generalized colon wall thickening or loss of layering.

### ***Pancreas***

The pancreas is prominent and mottled, surrounded by hyperechoic mesentery. There is no evidence of nodules or cystic lesions. There is no evidence of regional mesenteric inflammation or fluid.

### ***Free Abdomen***

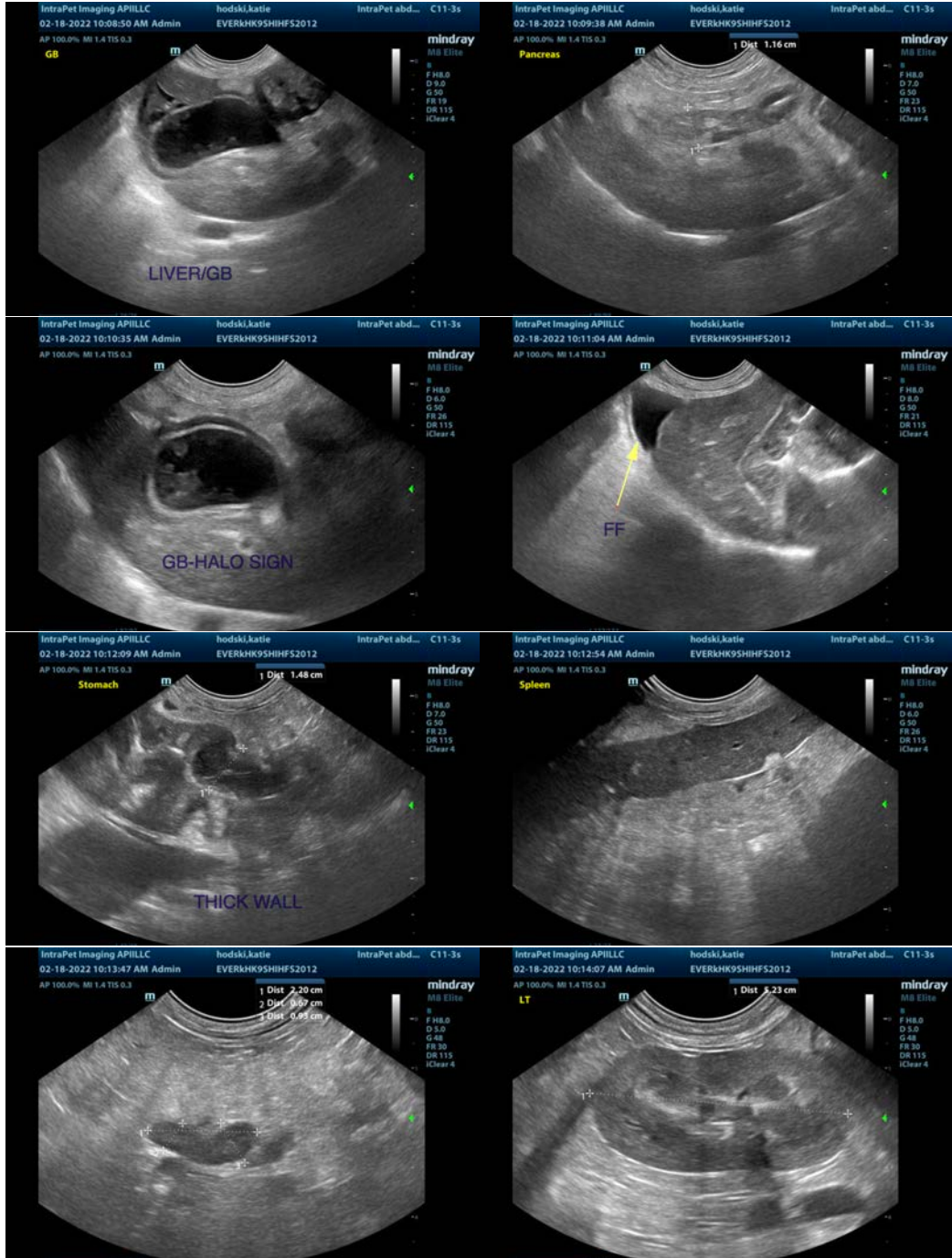
There is as large amount of free fluid, particularly in the cranial abdomen. No mesenteric lymphadenopathy is visualized, but the omentum is extremely hyperechoic, particularly in the area

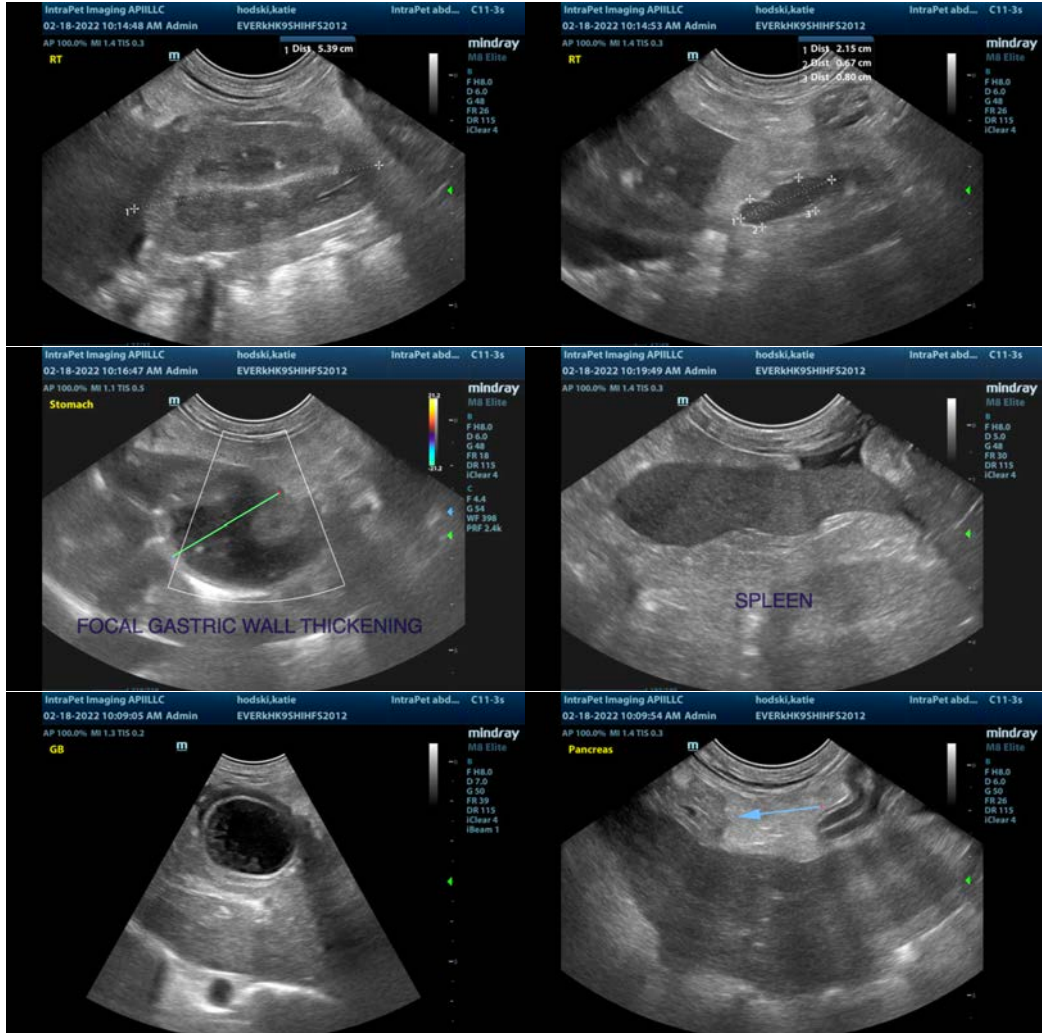
## **ULTRASONOGRAPHIC FINDINGS**

- Prominent, mottled pancreas surrounded by inflammation and free fluid – The pancreatic changes are most consistent with mild to moderate pancreatitis/pancreatic inflammation. Recommend fPLI testing and continued monitoring for improvement or possible development of a pancreatic abscess. Consider fine needle aspirate if not improving.
- Distended, thick walled gallbladder with mural edema and gallbladder polyps – Findings could be due to primary gallbladder disease, cholecystitis, etc., or could be exacerbated by systemic disease process causing edema. The surrounding free fluid and inflammation are concerning for possible rupture.
- Diffusely thickened stomach wall with focal loss of layering – Could be consistent with inflammation, edema or underlying neoplastic change. Recommend biopsies.
- Borderline bilateral adrenomegaly – The bilateral adrenomegaly could be consistent with bilateral hyperplasia (e.g., secondary to pituitary-dependent hyperadrenocorticism), bilateral infiltrative neoplasia, inflammatory adrenal disease, other. Correlation with clinical findings is recommended.
- Free abdominal fluid with hyperechoic mesentery – Most consistent with peritonitis, either sterile or infectious. Recommend fluid analysis, cytology and culture (aerobic and anaerobic).

## **INTERPRETATION OF THE FINDINGS & FURTHER RECOMMENDATIONS**

There is a large volume of fluid and inflammation in the cranial abdomen. The gallbladder is distended with a thick wall. The gastric wall is severely thickened and mottled, and the pancreas is prominent. These lesions could be a likely cause of the effusion, or a result of the effusion, but with the significant bilirubin elevation, I feel there is sufficient reason to surgically evaluate the gallbladder and biopsy the gastric wall. Recommend 3-view thoracic radiographs and coagulation testing.





The information and recommendations provided are based on the images presented by the referring veterinarian/sonographer. No evaluation can be communicated regarding pathology that was not visible in the image/video clips provided.

Thank you for this referral. If the clinical or image interpretation does not parallel your findings or if I can be of any further assistance please contact me.

Kathleen Sennello DVM,MS, Diplomate ACVIM (Small animal Internal Medicine)  
 kathleen.sennello@sonopath.com