



PATIENT

Onslow Moore

SPECIES

Canine

BREED

Golden Retriever

SEX

Neutered Male

AGE

12.5 Years

WEIGHT

78 lbs

INTERPRETED BY

Kathleen Sennello DVM,
MS, Diplomate ACVIM
(Small Animal Internal
Medicine)

IMAGING PERFORMED BY

Judy Schroeder, DVM

HOSPITAL NAME

Animal Health
Associates

REFERRING VET

Breanna Buxton, VMD

INVOICE

73026

DATE

2/17/26

PRESENTING CLINICAL SIGNS

Panting and pacing at night. Restless, anxious. Decreased ability to jump into car. O has noted that abdomen seems rounder. History of IBD. On gabapentin.

Abnormal PE/Chem/CBC/UA Results: Faint heart murmur. Doughy abdomen. Blood tests are pending. Patient did seem a little tender in dorsal cranial abdomen.

ULTRASONOGRAPHIC EXAMINATION OF THE ABDOMEN

Urinary System

The urinary bladder is moderately distended with anechoic urine. The Bladder wall, trigone, ureteral papillae and visible urethra (to a depth of 2cm) appear normal with no evidence of wall thickening, mucosal irregularities, masses or cystic calculi.

The prostate is normal in size (0.78 cm) and shape for this neutered male dog. The parenchyma is homogenous and the external margins are smooth. The prostatic urethra appears normal with no evidence of irregularity, invasion, mass effect or calculi.

The left kidney has a normal shape and size (6.92 cm). Overall echogenicity is normal with adequate corticomedullary distinction and a typical 1:3 cortex:medulla ratio. There is no evidence of focal perinephric inflammation or effusion. There is no evidence of pyelectasia, nephroliths, infarcts or hydroureter. Renal vasculature is normal.

The right kidney has a normal shape and size (6.99 cm). Overall echogenicity is normal with adequate corticomedullary distinction and a typical 1:3 cortex:medulla ratio. There is no evidence of focal perinephric inflammation or effusion. There is no evidence of pyelectasia, nephroliths, infarcts or hydroureter. Renal vasculature is normal.

Adrenal Glands

The left adrenal gland is normal in size measuring 0.76 cm at the cranial pole and 0.72 cm at the caudal pole. It is observed in its normal position cranial to the left renal artery. It is normal in appearance (uniformly hypoechoic) and shape with no evidence of a mass effect.

The right adrenal gland is normal in size measuring 0.82 cm at the caudal pole. It is observed in its normal position between the cranial aspect of the right kidney and the caudal vena cava. It is normal in appearance (uniformly hypoechoic) and shape with no evidence of a mass effect. The cranial pole is difficult to clearly visualize.

Spleen

The spleen is subjectively normal in size (2.91 cm), echotexture is homogenous, and the splenic capsule is smooth with no irregularities. The blood flow through the hilus and splenic parenchyma appears normal. No focal parenchymal abnormalities are visualized.

Liver

The liver is subjectively normal in size, and echogenicity with smooth peripheral margins. The parenchyma is homogenous echotexture. The visible portions of the vasculature and biliary tract appear normal. No focal nodules or cystic lesions are observed.



PATIENT

Onslow Moore

SPECIES

Canine

BREED

Golden Retriever

SEX

Neutered Male

AGE

12.5 Years

WEIGHT

78 lbs

INTERPRETED BY

Kathleen Sennello DVM,
MS, Diplomate ACVIM
(Small Animal Internal
Medicine)

IMAGING PERFORMED BY

Judy Schroeder, DVM

HOSPITAL NAME

Animal Health
Associates

REFERRING VET

Breanna Buxton, VMD

INVOICE

73026

DATE

2/17/26

The gall bladder lumen is moderately distended. The wall of the gall bladder is not thickened and has a smooth mucosal surface. There is a moderate amount of non-organized echogenic debris. The cystic and common bile ducts are normal/not visible.

Gastrointestinal

The stomach is minimally visualized. There is no evidence of significant fluid distention and no pathology observed. minimal luminal contents. It measures at a normal thickness of <0.7cm with some variability due to the presence of rugal folds. The distinction of the gastric wall layers is adequate and there is no impression of reduced peristaltic activity. No masses or focal lesions were observed.

The visualized areas of duodenum, jejunum and ileum have a relatively uniform diameter with minimal fluid distension. Wall thickness is normal. Bowel loops follow a curvilinear path with distinct wall layering maintaining the typical 1:3 muscularis:mucosa layer ratio. Jejunum wall measures 0.46 cm. Visualized peristalsis appears appropriate. There were no focal lesions consistent with obstruction or a mass effect observed.

Sections of colon are visualized with formed fecal material and gas shadowing distally. There is no observed focal or generalized colon wall thickening or loss of layering.

Pancreas

The area of the pancreas is normal and isoechoic to surrounding mesentery. There is no evidence of nodules or cystic lesions. There is no evidence of regional mesenteric inflammation or fluid.

Free Abdomen

Evaluation of the peritoneal cavity did not reveal any evidence of effusion, or subjective lymphadenomegaly. The Medial iliac nodes appear normal and there was no evidence of a caudal aortic thrombus at the bifurcation. The omentum is of normal uniform echogenicity.

ULTRASONOGRAPHIC FINDINGS

- Moderate gallbladder debris – The significance of the aggregated gallbladder debris is unclear. This could represent an early mucocele, cholestasis, or may be secondary to fasting but seems unlikely to be causing a current issue. Recommend continued monitoring.

INTERPRETATION OF THE FINDINGS & FURTHER RECOMMENDATIONS

No significant lesions are visualized on today's exam to explain the anxious behavior and abdominal distention described. Consider the possibility of musculoskeletal issues, cognitive issues, etc. Additionally recommend 3-view thoracic radiographs to evaluate for any evidence of thoracic or cardiac disease. If symptoms are persistent/progressive, repeat evaluation in the future could be considered, looking for the development of new lesions.

Recommend full lab work and a urinalysis.



PATIENT

Onslow Moore

SPECIES

Canine

BREED

Golden Retriever

SEX

Neutered Male

AGE

12.5 Years

WEIGHT

78 lbs

INTERPRETED BY

Kathleen Sennello DVM,
MS, Diplomate ACVIM
(Small Animal Internal
Medicine)

**IMAGING
PERFORMED BY**

Judy Schroeder, DVM

HOSPITAL NAME

Animal Health
Associates

REFERRING VET

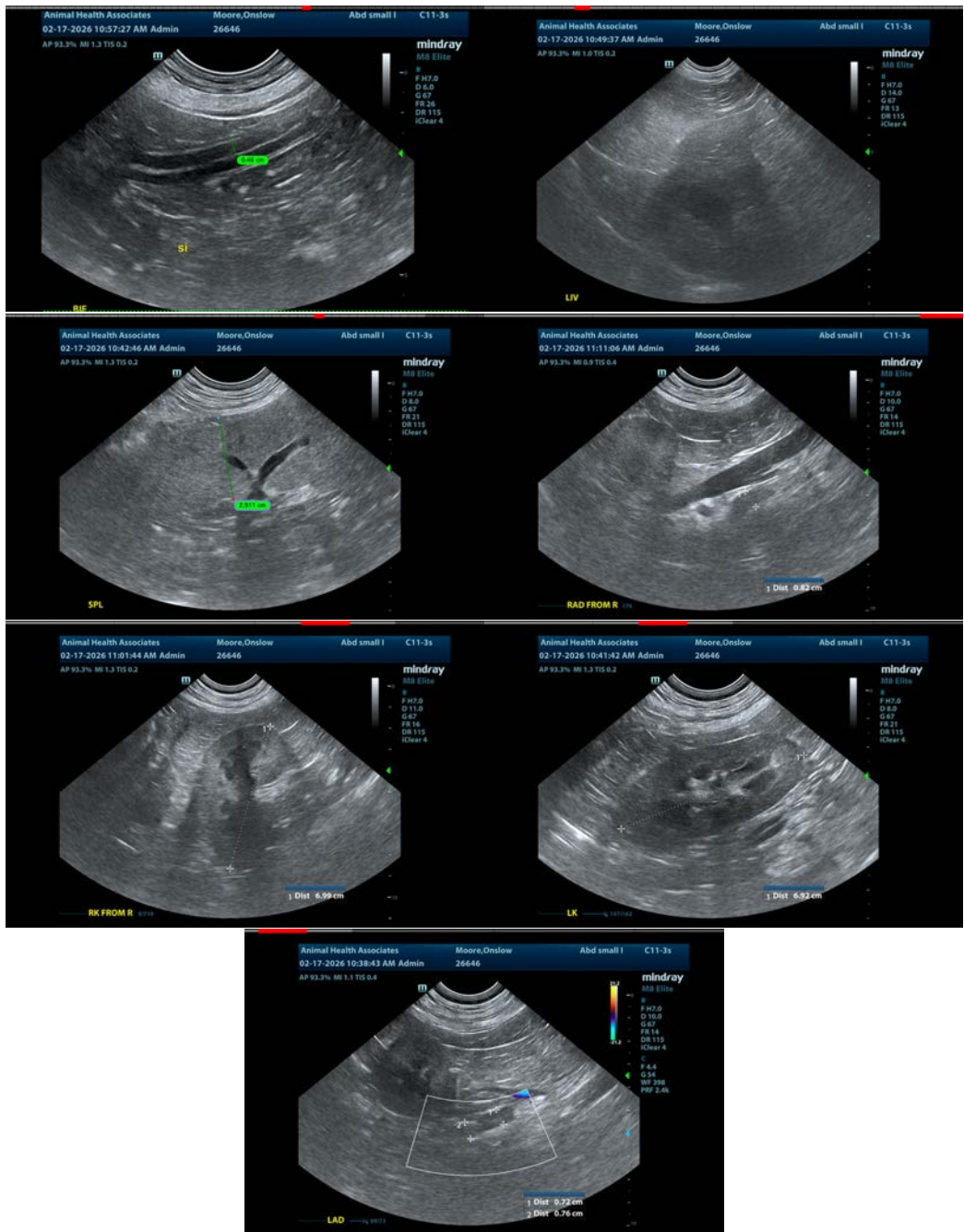
Breanna Buxton, VMD

INVOICE

73026

DATE

2/17/26



The information and recommendations provided are based on the images presented by the referring veterinarian/sonographer. No evaluation can be communicated regarding pathology that was not visible in the image/video clips provided.

Thank you for this referral. If the clinical or image interpretation does not parallel your findings or if I can be of any further assistance please contact me.

Kathleen Sennello DVM,MS, Diplomate ACVIM (Small animal Internal Medicine) info@sonopath.com