



## PATIENT

Autzen Bybee

## SPECIES

Canine

## BREED

Labrador Retriever

## SEX

Spayed Female

## AGE

10 Years 6 Months

## WEIGHT

71.8 lbs

## INTERPRETED BY

Kathleen Sennello DVM,  
MS, Diplomate ACVIM  
(Small Animal Internal  
Medicine)

## IMAGING PERFORMED BY

Dr. Lucas Budden

## HOSPITAL NAME

Frontier Veterinary  
Hospital

## REFERRING VET

Dr. Lucas Budden

## INVOICE

73029

## DATE

2/17/26

## PRESENTING CLINICAL SIGNS

Abdominal organomegaly palpated during recent exam for lameness of the left front limb. AFAST revealed splenic mass. Ultrasound today to assess for metastasis in preparation for splenectomy.

Current medications: Butorphanol to facilitate imaging, Rimadyl, gabapentin, Cosequin for intermittent/recurrent left forelimb lameness

Abnormal PE/Chem/CBC/UA Results: Physical exam: BCS 7/9, grade 3/6 left systolic HM, eupneic, no crackles or wheezes, mid abdominal organomegaly palpated, MM pk and CRT <2sec, peripheral LNs normal Lab work: Chest rads: no obvious mets, radiologist report pending Cbc/chem/pt/ptt pending

## ULTRASONOGRAPHIC EXAMINATION OF THE ABDOMEN

### Urinary System

The urinary bladder is moderately distended with anechoic urine. The Bladder wall, trigone, ureteral papillae and visible urethra (to a depth of 2cm) appear normal with no evidence of wall thickening, mucosal irregularities, masses or cystic calculi.

The left kidney has a normal shape and size (6.31 cm). Overall echogenicity is normal with adequate corticomedullary distinction and a typical 1:3 cortex:medulla ratio. There is no evidence of focal perinephric inflammation or effusion. There is no evidence of pyelectasia, nephroliths, infarcts or hydroureter. Renal vasculature is normal.

The right kidney has a normal shape and size (7.25 cm). Overall echogenicity is normal with adequate corticomedullary distinction and a typical 1:3 cortex:medulla ratio. There is no evidence of focal perinephric inflammation or effusion. There is no evidence of pyelectasia, nephroliths, infarcts or hydroureter. Renal vasculature is normal.

### Adrenal Glands

The left adrenal gland is normal in size measuring 0.57 cm at the cranial pole and 0.58 cm at the caudal pole. It is observed in its normal position cranial to the left renal artery. It is normal in appearance (uniformly hypoechoic) and shape with no evidence of a mass effect.

The right adrenal gland is normal in size measuring 0.74 cm at the caudal pole. It is observed in its normal position between the cranial aspect of the right kidney and the caudal vena cava. It is normal in appearance (uniformly hypoechoic) and shape with no evidence of a mass effect. The cranial pole of the right adrenal gland is not clearly visualized.

### Spleen

The spleen is large and irregular in shape. The blood flow through the hilus and splenic parenchyma appears normal. There is a small, hyperechoic lesion in the cranial aspect of the spleen measuring 0.90 cm x 0.36 cm, most consistent with a benign lesion such as a myelolipoma. Towards the tail of the spleen there is a large, mixed echogenicity, hypoechoic, slightly cavitated mass effect measuring 6.34 cm x 7.87 cm.



## PATIENT

Autzen Bybee

## SPECIES

Canine

## BREED

Labrador Retriever

## SEX

Spayed Female

## AGE

10 Years 6 Months

## WEIGHT

71.8 lbs

## INTERPRETED BY

Kathleen Sennello DVM,  
MS, Diplomate ACVIM  
(Small Animal Internal  
Medicine)

## IMAGING PERFORMED BY

Dr. Lucas Budden

## HOSPITAL NAME

Frontier Veterinary  
Hospital

## REFERRING VET

Dr. Lucas Budden

## INVOICE

73029

## DATE

2/17/26

## Liver

The liver is subjectively normal in size, and echogenicity with smooth peripheral margins. The parenchyma is heterogenous in echotexture with subtle, indistinct focal mottling. The visible portions of the vasculature and biliary tract appear normal. No focal nodules or cystic lesions are observed.

The gall bladder lumen is moderately distended. The wall of the gall bladder is not thickened and has a smooth mucosal surface. Luminal contents are mild and likely incidental at this time. The cystic and common bile ducts are normal/not visible.

## Gastrointestinal

The stomach contains mild gas. It measures at a normal thickness of <0.7cm with some variability due to the presence of rugal folds. The distinction of the gastric wall layers is adequate and there is no impression of reduced peristaltic activity. No masses or focal lesions were observed.

The visualized areas of duodenum, jejunum and ileum have a relatively uniform diameter with minimal fluid distension. Wall thickness is normal. Bowel loops follow a curvilinear path with distinct wall layering maintaining the typical 1:3 muscularis:mucosa layer ratio. Duodenum wall measures 0.54 cm. Jejunum wall measures 0.28 cm. Visualized peristalsis appears appropriate. There were no focal lesions consistent with obstruction or a mass effect observed.

Sections of colon are visualized with formed fecal material and gas shadowing distally. There is no observed focal or generalized colon wall thickening or loss of layering.

## Pancreas

The pancreas is normal and isoechoic to surrounding mesentery. There is no evidence of nodules or cystic lesions. There is no evidence of regional mesenteric inflammation or fluid.

## Free Abdomen

Evaluation of the peritoneal cavity did not reveal any evidence of effusion, or subjective lymphadenomegaly. The Medial iliac nodes appear normal and there was no evidence of a caudal aortic thrombus at the bifurcation. The omentum is of normal uniform echogenicity.

A still image of the heart was included. No definitive evidence of pericardial effusion or mass effect is visualized. Recommend full cardiac evaluation if this is a concern.

## ULTRASONOGRAPHIC FINDINGS

- Large, hypoechoic, slightly cavitated splenic mass lesion – A large, heterogenous mass with cavitations is present within the splenic parenchyma. The mass distorts the splenic capsule. Differentials for the mass include neoplasia (e.g., hemangiosarcoma, hemangioma), hematoma, abscess, other. A neoplastic process is favored.
- Heterogeneous liver – The diffuse hepatic changes are non-specific and could be consistent with vacuolar hepatopathy, nodular hyperplasia, inflammatory/immune-mediated disease, fibrosis, extramedullary hematopoiesis, toxic hepatopathy (e.g., copper), infiltrative neoplasia (less likely) or other hepatopathy.



## PATIENT

Autzen Bybee

## SPECIES

Canine

## BREED

Labrador Retriever

## SEX

Spayed Female

## AGE

10 Years 6 Months

## WEIGHT

71.8 lbs

## INTERPRETED BY

Kathleen Sennello DVM,  
MS, Diplomate ACVIM  
(Small Animal Internal  
Medicine)

## IMAGING PERFORMED BY

Dr. Lucas Budden

## HOSPITAL NAME

Frontier Veterinary  
Hospital

## REFERRING VET

Dr. Lucas Budden

## INVOICE

73029

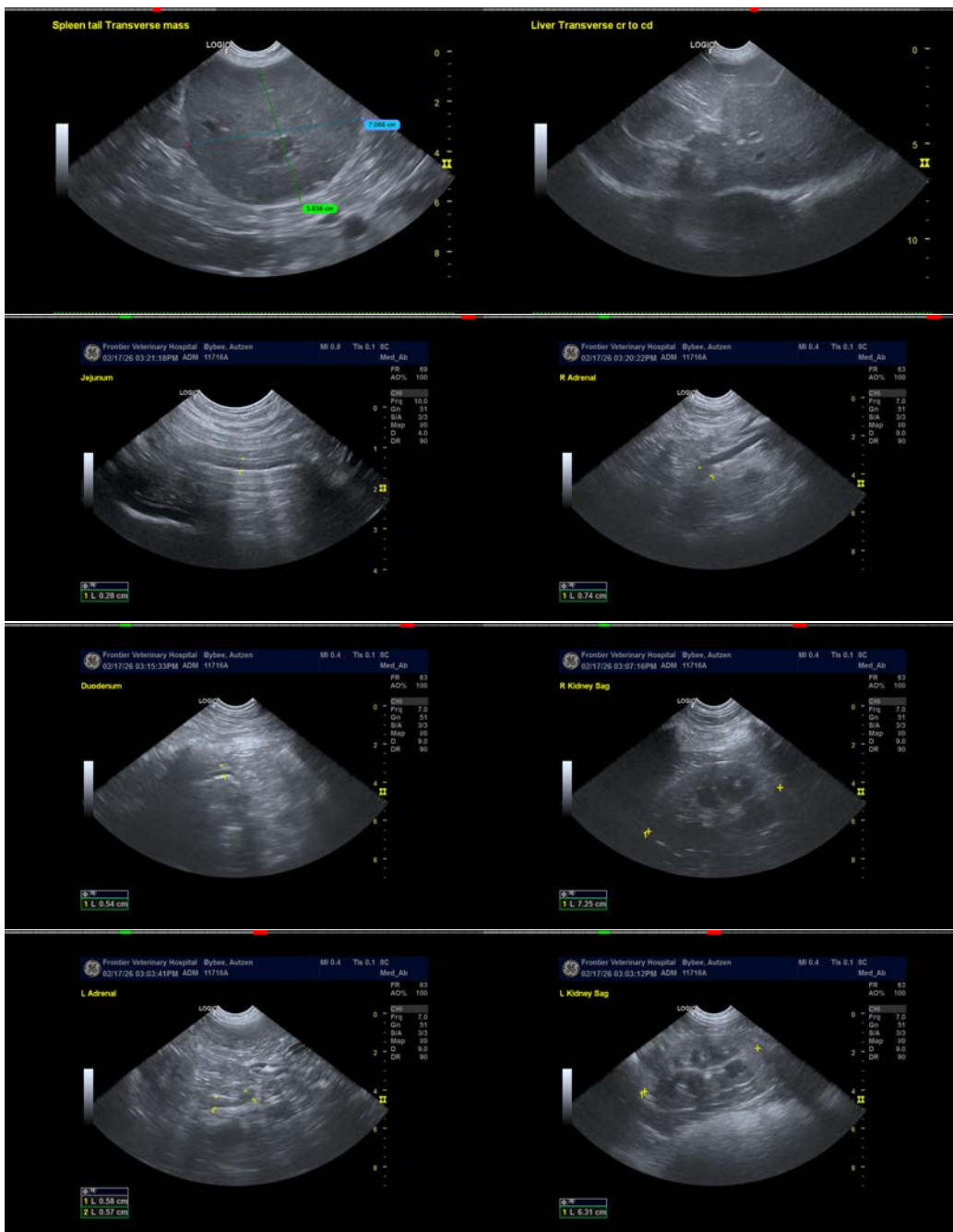
## DATE

2/17/26

## INTERPRETATION OF THE FINDINGS & FURTHER RECOMMENDATIONS

The large splenic mass described in the history is confirmed on today's exam. No definitive metastatic lesions are visualized, although the liver is slightly heterogeneous. This likely represents a mild vacuolar hepatopathy or similar, but small metastatic lesions cannot be ruled out.

Recommend splenectomy with samples submitted for histopathology. If any nodules are visualized at the time of surgery, recommend sampling and histopathology +/- liver biopsy.





## PATIENT

Autzen Bybee

## SPECIES

Canine

## BREED

Labrador Retriever

## SEX

Spayed Female

## AGE

10 Years 6 Months

## WEIGHT

71.8 lbs

## INTERPRETED BY

Kathleen Sennello DVM,  
MS, Diplomate ACVIM  
(Small Animal Internal  
Medicine)

## IMAGING PERFORMED BY

Dr. Lucas Budden

## HOSPITAL NAME

Frontier Veterinary  
Hospital

## REFERRING VET

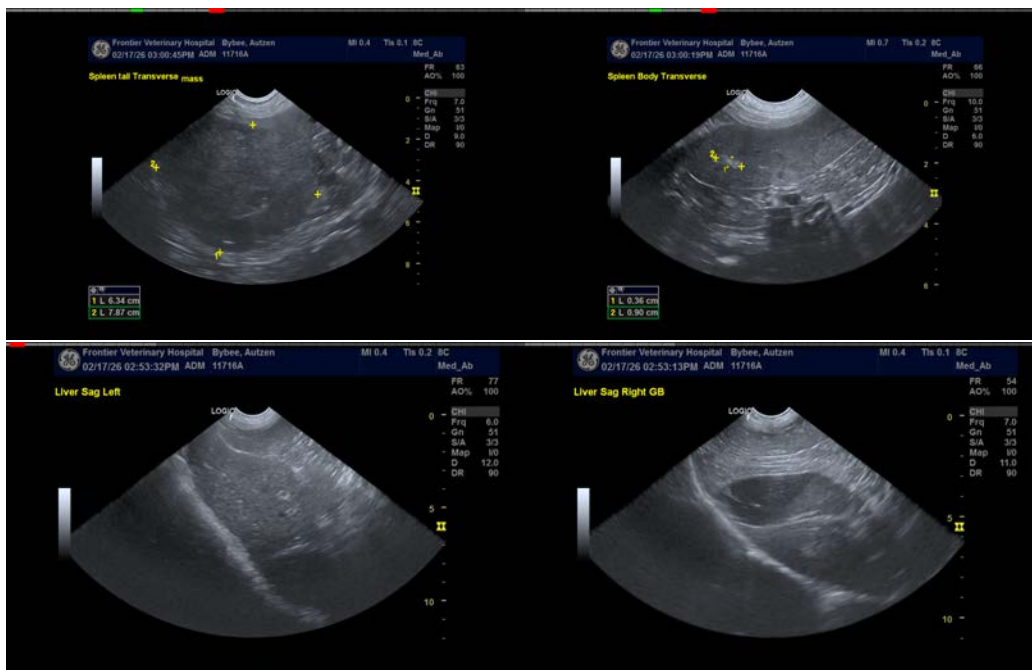
Dr. Lucas Budden

## INVOICE

73029

## DATE

2/17/26



The information and recommendations provided are based on the images presented by the referring veterinarian/sonographer. No evaluation can be communicated regarding pathology that was not visible in the image/video clips provided.

Thank you for this referral. If the clinical or image interpretation does not parallel your findings or if I can be of any further assistance please contact me.

Kathleen Sennello DVM,MS, Diplomate ACVIM (Small animal Internal Medicine)

info@sonopath.com