

**DATE PRESENTING CLINICAL SIGNS**

2/17/23 Intermittent episodes of getting stiff and vomiting.

**PATIENT**

Fresh Belle

Current Medications: Pepcid 10 mg once daily.  
 Lab Results: Chemistry/CBC/4DX all WNL, Baseline cortisol testing normal.  
 Date of Previous IntraPet Ultrasound: No previous.  
 Sedation: Not required to complete full diagnostic ultrasound.  
 Stat Report: Not requested.  
 Imaging Performed By: Andi Parkinson, BS, RDMS.

**SPECIES**

Canine

**ULTRASONOGRAPHIC EXAMINATION OF THE ABDOMEN****BREED**

Yorkie

**Urinary System**

The urinary bladder is moderately distended with anechoic urine. The Bladder wall, trigone, ureteral papillae and visible urethra (to a depth of 2cm) appear normal with no evidence of wall thickening, mucosal irregularities, masses or cystic calculi.

**SEX**

Neutered Male

The prostate is normal in size (0.78 cm) and shape for this neutered male dog. The parenchyma is homogenous and the external margins are smooth. The prostatic urethra appears normal with no evidence of irregularity, invasion, mass effect or calculi.

**AGE**

10/1/15

The left kidney has a normal shape and size (3.9 cm). Overall echogenicity is normal with adequate corticomedullary distinction and a typical 1:3 cortex:medulla ratio. There is no evidence of focal perinephric inflammation or effusion. There is no evidence of pyelectasia, nephroliths, infarcts or hydroureter. Renal vasculature is normal.

**WEIGHT**

12.8 Pounds

The right kidney has a normal shape and size (3.85 cm). Overall echogenicity is normal with adequate corticomedullary distinction and a typical 1:3 cortex:medulla ratio. There is no evidence of focal perinephric inflammation or effusion. There is no evidence of pyelectasia, nephroliths, infarcts or hydroureter. Renal vasculature is normal.

**INTERPRETED BY**

Kathleen Sennello DVM,  
 MS, Diplomate ACVIM  
 (Small Animal Internal  
 Medicine)

**Adrenal Glands**

The left adrenal gland is normal in size measuring 0.52 cm at the caudal pole. It is observed in its normal position cranial to the left renal artery. It is normal in appearance (uniformly hypoechoic) and shape with no evidence of a mass effect.

**HOSPITAL NAME**

Banfield Towson

The right adrenal gland is normal in size measuring 0.48 cm at the caudal pole. It is observed in its normal position between the cranial aspect of the right kidney and the caudal vena cava. It is normal in appearance (uniformly hypoechoic) and shape with no evidence of a mass effect.

**REFERRING VET**

Dr. Lewis

**Spleen**

The spleen is subjectively normal in size, echotexture is homogenous, and the splenic capsule is smooth with no irregularities. The blood flow through the hilus and splenic parenchyma appears normal. No focal parenchymal abnormalities are visualized.

**INVOICE**

45364

**Liver**

The liver is subjectively normal in size, and echogenicity with smooth peripheral margins. The parenchyma is homogenous echotexture. The visible portions of the vasculature and biliary tract appear normal. There is a small hypoechoic nodule visualized within the parenchyma measuring 0.59 cm.

The gallbladder lumen is moderately distended. The wall of the gall bladder is not thickened and has a smooth mucosal surface. Luminal contents are mild and primarily anechoic. The cystic and common bile ducts are normal/not visible.

### ***Gastrointestinal***

The stomach contains minimal luminal contents. It measures at a normal thickness of <0.7cm with some variability due to the presence of rugal folds. The distinction of the gastric wall layers is adequate and there is no impression of reduced peristaltic activity. No masses or focal lesions were observed.

The visualized areas of duodenum, jejunum and ileum have a relatively uniform diameter with minimal fluid distension. Wall thickness is normal. Bowel loops follow a curvilinear path with distinct wall layering maintaining the typical 1:3 muscularis:mucosa layer ratio. Jejunum wall measures 0.28 cm. Visualized peristalsis appears appropriate. There were no focal lesions consistent with obstruction or a mass effect observed.

The ileocecal junction was visualized and exhibited normal intact wall layering and is subjectively of normal thickness. Sections of colon are visualized with formed fecal material and gas shadowing distally. There is no observed focal or generalized colon wall thickening or loss of layering.

### ***Pancreas***

The right limb of the pancreas is prominent and mottled compared to the surrounding isoechoic mesentery. There is no evidence of nodules or cystic lesions. There is no evidence of regional mesenteric inflammation or fluid.

### ***Free Abdomen***

Evaluation of the peritoneal cavity did not reveal any evidence of effusion, or subjective lymphadenomegaly. The Medial iliac nodes appear normal and there was no evidence of a caudal aortic thrombus at the bifurcation. The omentum is of normal uniform echogenicity.

### ***Other***

The right auricle and pericardium were visualized and were unremarkable. No obvious pathology is visualized. If cardiac function evaluation is desired a full echocardiogram is warranted.

## **ULTRASONOGRAPHIC FINDINGS**

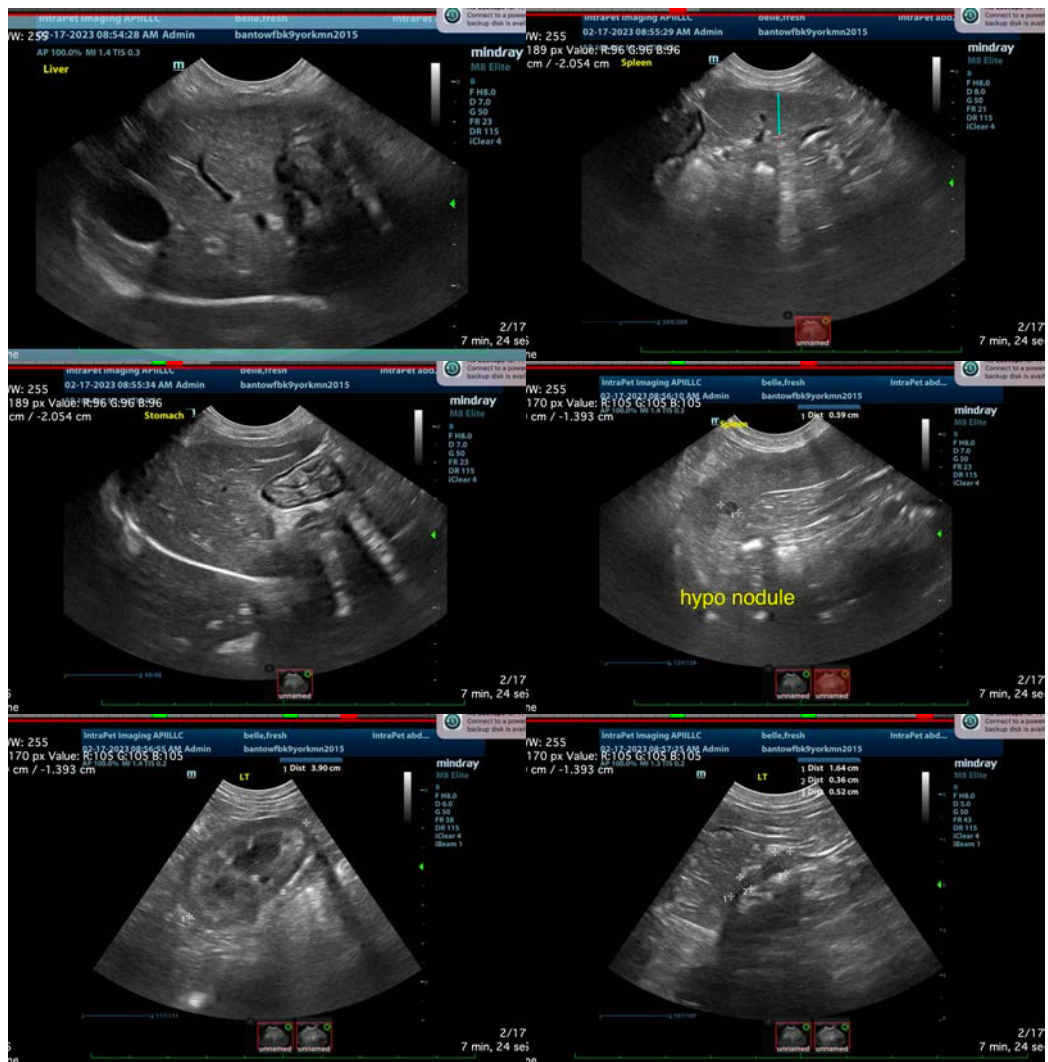
- Small hypoechoic nodule visualized in the spleen – There is a non-cavitated, hypoechoic splenic nodule visualized. Differentials include lymphoid hyperplasia, extramedullary hematopoiesis, infiltrative neoplasia, inflammation, other. Cytology or histopathology would be necessary to get a definitive diagnosis.
- Prominent, mottled right limb of the pancreas – The pancreatic changes are most consistent with mild pancreatitis or a recent episode of pancreatic inflammation.

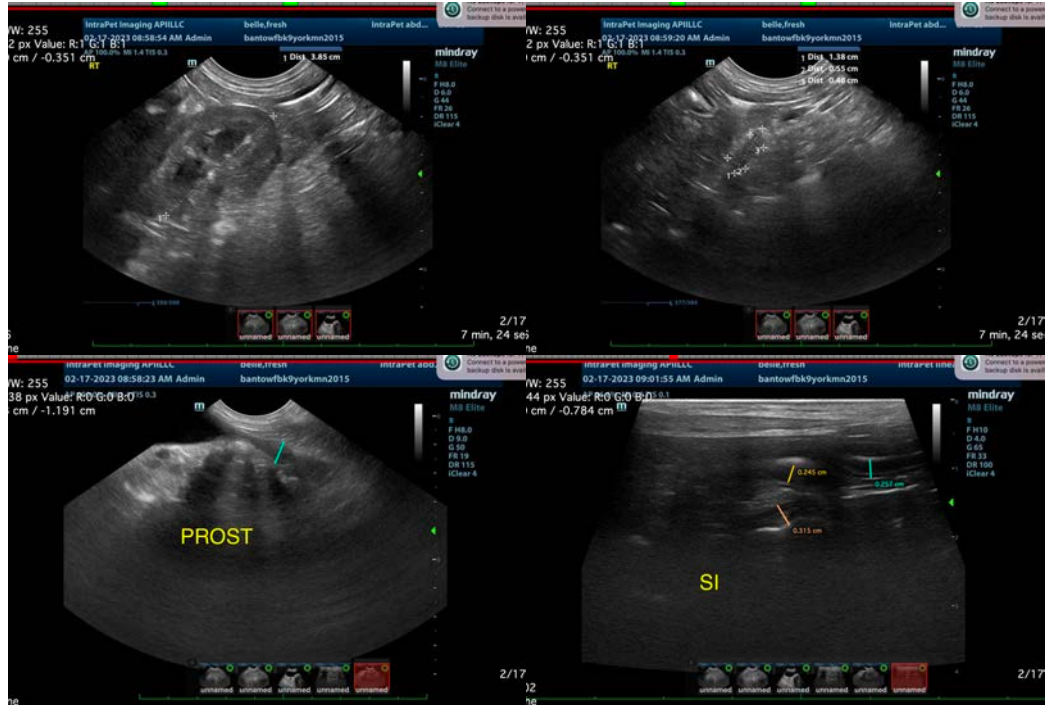
## **INTERPRETATION OF THE FINDINGS & FURTHER RECOMMENDATIONS**

The findings on today's scan are relatively mild. The pancreas appears slightly mottled. This could be consistent with mild current inflammation or previous episodes of inflammation. Correlate with quantitative cPLI level and consider symptomatic treatment for pancreatitis/gastroenteritis. Additionally, consider the possibility of underlying small intestinal disease. You could consider a GI panel to Texas A&M for a qualitative PLI, TLI, cobalamin and folate to obtain further information regarding the gastrointestinal tract to try and determine if further workup is warranted. Additionally, a novel protein/hydrolyzed protein prescription diet and probiotic therapy could be considered.

There is a small hypoechoic nodule visualized within the spleen. This could represent a benign lesion or an early neoplastic lesion. I suspect this would be challenging to sample at this time, but if an adequate window is available, consider a fine needle aspirate (provided coagulation parameters are normal). Alternately, recommend follow up ultrasound to monitor for any changes in size/appearance.

Recommend three view thoracic radiographs to evaluate for possible concurrent thoracic disease/involvement.





The information and recommendations provided are based on the images presented by the referring veterinarian/sonographer. No evaluation can be communicated regarding pathology that was not visible in the image/video clips provided.

Thank you for this referral. If the clinical or image interpretation does not parallel your findings or if I can be of any further assistance please contact me.

Kathleen Sennello DVM,MS, Diplomate ACVIM (Small animal Internal Medicine)  
 kathleen.sennello@sonopath.com