



PATIENT

Smoots Snort Rescue

PRESENTING CLINICAL SIGNS

Severe aggression PSS vs primary brain lesion increased ALT

SPECIES

Canine

ULTRASONOGRAPHIC EXAMINATION OF THE ABDOMEN

BREED

French Bulldog

Urinary System

The urinary bladder is moderately distended with anechoic urine. The Bladder wall, trigone, ureteral papillae and visible urethra (to a depth of 2cm) appear normal with no evidence of wall thickening, mucosal irregularities, masses or cystic calculi.

SEX

Neutered male

The visualized areas of prostate and surrounding tissue appear normal. Unfortunately, the prostate is not fully visualized likely due to its intrapelvic location. Correlate with rectal exam findings.

AGE

2 years

The left kidney has a normal shape and size (3.83 cm). Overall echogenicity is normal with adequate corticomedullary distinction and a typical 1:3 cortex:medulla ratio. There is no evidence of perinephric inflammation or effusion. There is no evidence of pyelectasia, nephroliths, infarcts or hydroureter. Renal vasculature is normal.

WEIGHT

29 lbs

The right kidney has a normal shape and size (4.52 cm). Overall echogenicity is normal with adequate corticomedullary distinction and a typical 1:3 cortex:medulla ratio. There is no evidence of perinephric inflammation or effusion. There is no evidence of pyelectasia, nephroliths, infarcts or hydroureter. Renal vasculature is normal.

INTERPRETED BY

Kathleen Sennello
DVM, MS, Diplomate
ACVIM (Small Animal
Internal Medicine)

Adrenal Glands

The left adrenal gland is normal in size measuring 0.52 cm at the caudal pole. It is observed in its normal position cranial to the left renal artery. It is normal in appearance (uniformly hypoechoic) and shape with no evidence of a mass effect.

IMAGING PERFORMED BY

Jen

The right adrenal gland is normal in size measuring 0.6 cm at the caudal pole. It is observed in its normal position between the cranial aspect of the right kidney and the caudal vena cava. It is normal in appearance (uniformly hypoechoic) and shape with no evidence of a mass effect.

HOSPITAL NAME

Rockaway AH

Spleen

The spleen is subjectively normal in size, echotexture is homogenous, and the splenic capsule is smooth with no irregularities. The blood flow through the hilus and splenic parenchyma appears normal. No focal parenchymal abnormalities are visualized.

REFERRING VET

Dr. Maniar

Liver

INVOICE

96107

The liver is subjectively normal in size, and echogenicity with smooth peripheral margins. The parenchyma is homogenous echotexture. The visible portions of the vasculature and biliary tract appear normal. No focal nodules or cystic lesions are observed. The gallbladder lumen is moderately distended. The wall of the gallbladder is not thickened and has a smooth mucosal surface. Luminal contents are primarily anechoic. The cystic and common bile ducts are normal/not visible.

DATE

2/17/22



PATIENT

Smoots Snort Rescue

SPECIES

Canine

BREED

French Bulldog

SEX

Neutered male

AGE

2 years

WEIGHT

29 lbs

INTERPRETED BY

Kathleen Sennello
DVM, MS, Diplomate
ACVIM (Small Animal
Internal Medicine)

IMAGING PERFORMED BY

Jen

HOSPITAL NAME

Rockaway AH

REFERRING VET

Dr. Maniar

INVOICE

96107

DATE

2/17/22

Gastrointestinal

The stomach is moderately dilated with fluid and irregular shadowing material most consistent with normal ingesta and gas. It measures at a normal thickness of <0.7cm with some variability due to the presence of rugal folds. The distinction of the gastric wall layering is adequate and there is no impression of reduced peristaltic activity. No masses or focal lesions were observed.

The visualized areas of duodenum, jejunum and ileum have a relatively uniform diameter with minimal fluid distension. Wall thickness is normal. Bowel loops follow a curvilinear path with distinct wall layering maintaining the typical 1:3 muscularis:mucosa layer ratio. The duodenum measured as normal (between 0.3-0.5cm in wall thickness) and the jejunum measured as normal (between 0.2-0.47cm.) Visualized peristalsis appears appropriate. There were no focal lesions consistent with obstruction or a mass effect observed.

The ileocecal junction was visualized and exhibited normal intact wall layering and is subjectively of normal thickness. Sections of colon are visualized with formed fecal material and gas shadowing distally. There is no observed focal or generalized colon wall thickening or loss of layering.

Pancreas

The pancreas is hypoechoic and prominent.

Free Abdomen

Evaluation of the peritoneal cavity did not reveal any evidence of effusion, or subjective lymphadenomegaly. The Medial iliac nodes appear normal and there was no evidence of a caudal aortic thrombus at the bifurcation. The omentum is of normal uniform echogenicity.

ULTRASONOGRAPHIC FINDINGS

PRIMARY FINDINGS:

- Hypoechoic, prominent pancreas. The pancreatic changes are most consistent with mild pancreatitis or a recent episode of pancreatic inflammation.
- Large ingesta within the gastric lumen. The findings are most consistent with ingesta/possible kibble. Correlate with feeding history. If the patient is adequately fasted consider such differentials as delayed gastric emptying or partial outflow tract obstruction (not observed).

INTERPRETATION OF THE FINDINGS & FURTHER RECOMMENDATIONS

Today's scan is relatively normal. The large amount of ingesta within the gastric lumen impairs evaluation of the hilus of the liver somewhat, but adequate portal branching is observed making the likelihood of a portosystemic shunt low. I recommend pre and post prandial acids. If the bile acids are elevated (typically > 80) consider a contrast CT scan to look for smaller shunting vessels.



PATIENT

Smoots Snort Rescue

SPECIES

Canine

BREED

French Bulldog

SEX

Neutered male

AGE

2 years

WEIGHT

29 lbs

INTERPRETED BY

Kathleen Sennello
DVM, MS, Diplomate
ACVIM (Small Animal
Internal Medicine)

IMAGING PERFORMED BY

Jen

HOSPITAL NAME

Rockaway AH

REFERRING VET

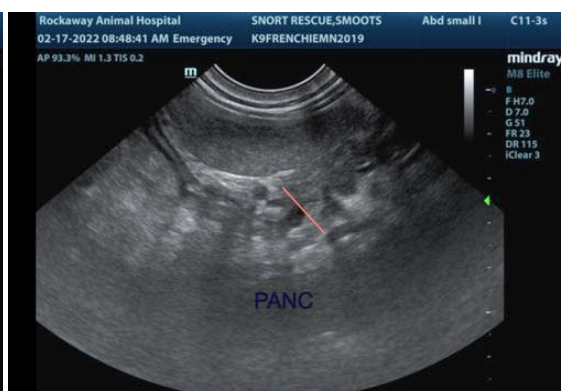
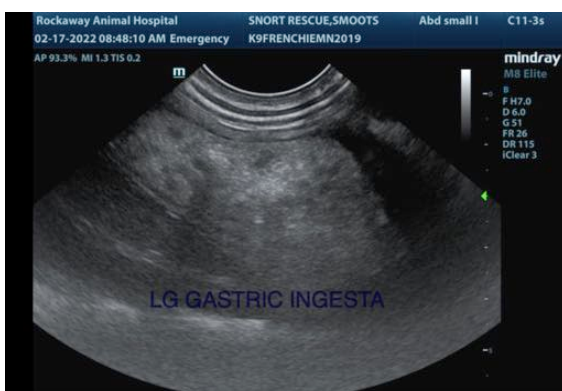
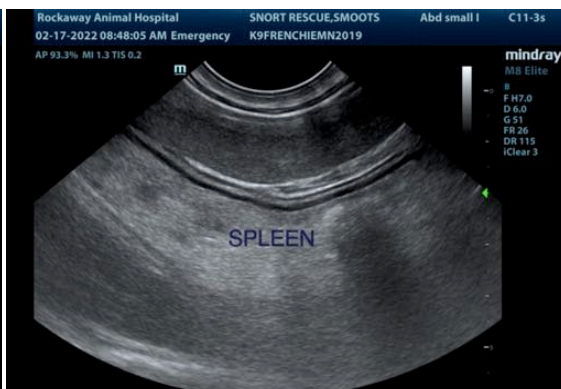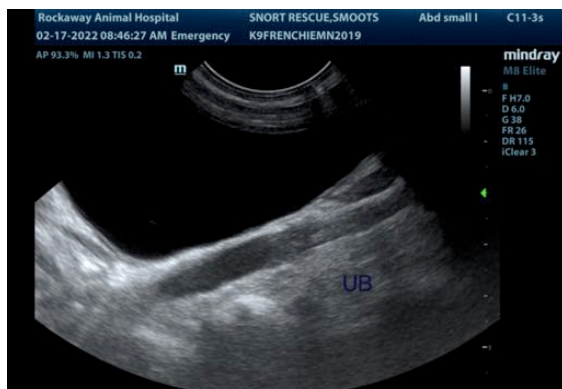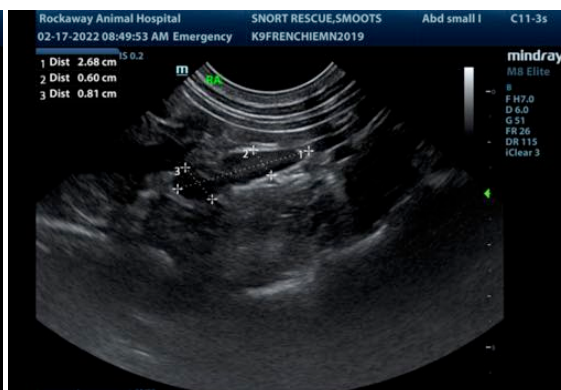
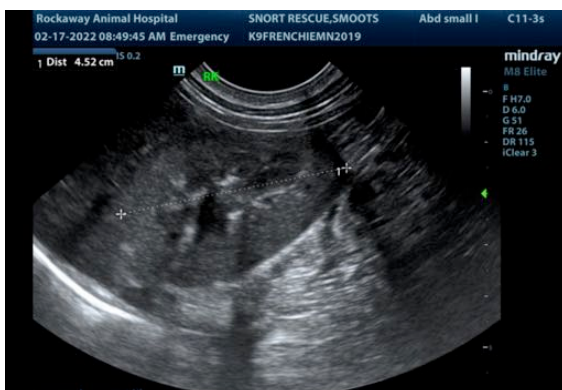
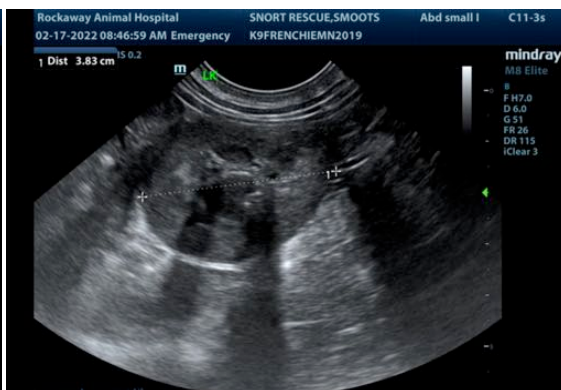
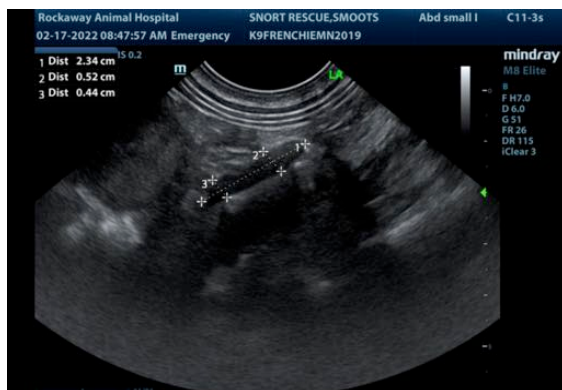
Dr. Maniar

INVOICE

96107

DATE

2/17/22





PATIENT

Smoots Snort Rescue

SPECIES

Canine

BREED

French Bulldog

SEX

Neutered male

AGE

2 years

WEIGHT

29 lbs

INTERPRETED BY

Kathleen Sennello
DVM, MS, Diplomate
ACVIM (Small Animal
Internal Medicine)

IMAGING PERFORMED BY

Jen

HOSPITAL NAME

Rockaway AH

REFERRING VET

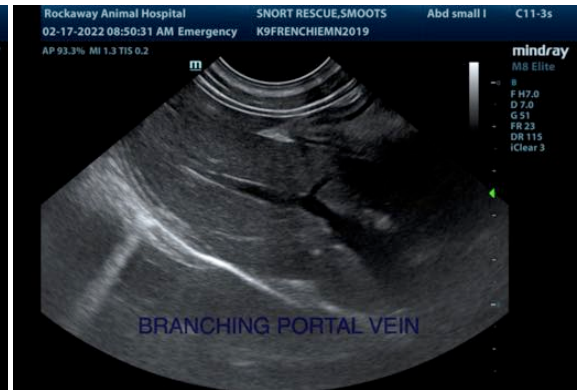
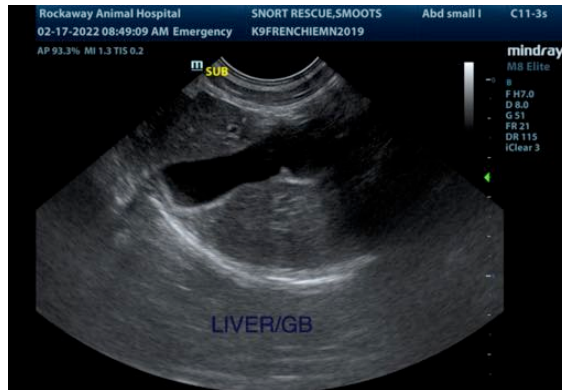
Dr. Maniar

INVOICE

96107

DATE

2/17/22



The information and recommendations provided are based on the images presented by the referring veterinarian/sonographer. No evaluation can be communicated regarding pathology that was not visible in the image/video clips provided.

Thank you for this referral. If the clinical or image interpretation does not parallel your findings or if I can be of any further assistance please contact me.

Kathleen Sennello DVM,MS, Diplomate ACVIM (Small animal Internal Medicine)
kathleen.sennello@sonopath.com