



PATIENT PRESENTING CLINICAL SIGNS

PATIENT Raisin Watson
SPECIES Feline
BREED Domestic Shorthair
SEX Spayed Female
AGE 9 years
WEIGHT 5 kg

Presented at our hospital for transfer from rDVM. 1 week history of lethargy, pu/pd, vomiting. Blood work done elevated glucose, elevated liver values. Previous Health Concerns: none Current Medications: none Appetite/When did they eat last: decreased for few days, not eating for 2 days Abnormal PE/Chem/CBC/UA Results: Temp: 103.6 Cardiovascular: no murmur heard, est 10% dehydration Abdominal: painful cranial abdomen Musculoskeletal: laterally recumbent rDVM labs: glucose 454, ALT 187, total bilirubin 2.6, cholesterol 274, amylase 396 rDVM urine: USG >1.050, urine glucose 1,000, ketone 50, bacteria cocci (suspected) EPOC: pH 7.230 L, Sodium 147 L, Ionized Ca 1.11 L, Glucose 503 H, HCT 41% N FPL: abnormal Rads: calcification mid abdomen, concern for effusion cranial abdomen, caudal calcified bates

ULTRASONOGRAPHIC EXAMINATION OF THE ABDOMEN

Urinary System

The urinary bladder is moderately distended with anechoic urine. The Bladder wall, trigone, ureteral papillae and visible urethra (to a depth of 2cm) appear normal with no evidence of wall thickening, mucosal irregularities, masses or cystic calculi.

The left kidney has a normal shape and size (4.47 cm). Overall echogenicity is normal with adequate corticomedullary distinction and a typical 1:3 cortex:medulla ratio. There is no evidence of perinephric inflammation or effusion. There is no evidence of pyelectasia, nephroliths, infarcts or hydroureter. Renal vasculature is normal.

The right kidney has a normal shape and size (4.21 cm). Overall echogenicity is normal with adequate corticomedullary distinction and a typical 1:3 cortex:medulla ratio. There is no evidence of perinephric inflammation or effusion. Mild pyelectasia measured 0.32 cm. There is no evidence of nephroliths, infarcts or hydroureter. Renal vasculature is normal.

Adrenal Glands

The left adrenal gland is normal/borderline large in size measuring 0.5 cm at the caudal pole It is observed in its normal position cranial to the left renal artery. It is normal in appearance (uniformly hypoechoic) and shape with no evidence of a mass effect.

The right adrenal gland is normal/borderline large in size measuring 0.5 cm at the caudal pole It is observed in its normal position between the cranial aspect of the right kidney and the caudal vena cava. It is normal in appearance (uniformly hypoechoic) and shape with no evidence of a mass effect.

Spleen

The spleen is subjectively normal in size, echotexture is homogenous, and the splenic capsule is smooth with no irregularities. The blood flow through the hilus and splenic parenchyma appears normal. No focal parenchymal abnormalities are visualized.

INTERPRETED BY

Kathleen Sennello
DVM, MS, Diplomate
ACVIM (Small Animal
Internal Medicine)

IMAGING PERFORMED BY

Erin Wicks

HOSPITAL NAME

Shores VEC

REFERRING VET

Dr. Miller

INVOICE

96110

DATE

2/17/22



PATIENT

Liver

Raisin Watson

The liver is subjectively large/normal in size with smooth peripheral margins. The parenchyma is hyperechoic and homogenous in echotexture. The visible portions of the vasculature and biliary tract appear normal. No focal nodules or cystic lesions are observed. The gallbladder is minimally distended with anechoic luminal contents. The wall appears somewhat thickened and collapsed measuring 0.32 cm with a lack of definition. The bile duct appears tortuous and dilated measuring approximately 0.48 cm. No point of obstruction is visualized and the wall appears thickened.

SPECIES

Feline

BREED

Domestic Shorthair

Gastrointestinal

The stomach contains moderate fluid distension. It measures at a normal thickness of <0.7cm with some variability due to the presence of rugal folds. The distinction of the gastric wall layers is adequate and there is no impression of reduced peristaltic activity. No masses or focal lesions were observed.

SEX

Spayed Female

The visualized areas of duodenum, jejunum and ileum have a relatively uniform diameter with minimal fluid distension. Wall thickness is normal. Bowel loops follow a curvilinear path with distinct wall layering maintaining the typical 1:3 muscularis:mucosa layer ratio. The duodenum measured as normal (between 0.3-0.5cm in wall thickness) and the jejunum measured as normal (between 0.2-0.47cm.)

AGE

9 years

Visualized peristalsis appears appropriate. There were no focal lesions consistent with obstruction or a mass effect observed.

WEIGHT

5 kg

The ileocecal junction was visualized and exhibited normal intact wall layering and is subjectively of normal thickness. Sections of colon are visualized with formed fecal material and gas shadowing distally. There is no observed focal or generalized colon wall thickening or loss of layering.

INTERPRETED BY

Kathleen Sennello
DVM, MS, Diplomate
ACVIM (Small Animal
Internal Medicine)

Pancreas

The pancreas appears large, irregular and undefined. The parenchyma is hypoechoic with a prominent pancreatic duct. The left limb of the pancreas cranial to the left kidney has a well-defined, hypoechoic area that is almost consistent with a mass effect. There is inflamed omentum and free fluid surrounding this area. Along the right limb of the pancreas there is generalized inflammation and swelling.

IMAGING PERFORMED BY

Erin Wicks

Free Abdomen

HOSPITAL NAME

Shores VEC

A small to moderate amount of anechoic free fluid, particularly in the cranial abdomen around the liver, gallbladder and pancreas was noted. No lymphadenopathy was noted. The omentum is of increased echogenicity.

REFERRING VET

Dr. Miller

ULTRASONOGRAPHIC FINDINGS

PRIMARY FINDINGS:

INVOICE

96110

- Large, irregular, hypoechoic pancreas with surrounding fluid and inflammation. The pancreatic changes are most consistent with severe pancreatitis/pancreatic infiltration. I recommend fPLI testing and continued monitoring for improvement or possible development of a pancreatic abscess. Consider FNA if not improving.

DATE

2/17/22

- Large, hyperechoic liver. Hepatic changes are non-specific and could be consistent with hepatic



PATIENT

lipidosis, inflammatory/infectious disease, infiltrative neoplasia, or other hepatopathy.

Raisin Watson

- Thick walled gallbladder with dilated tortuous bile duct with a thickened wall. Dilation of the common bile duct could be consistent with a functional obstruction (i.e. primary hepatic disease resulting in hepatocellular swelling) or with an extrahepatic bile duct obstruction (ie. choledocholith, bile duct tumor, pancreatic disease, other).

SPECIES

Feline

- Mild pyelectasia of the right kidney. Pyelectasia of the left/right kidney could be consistent with pyelonephritis, chronic renal disease, secondary to PU/PD or fluid therapy (if applicable), other.

BREED

Domestic Shorthair

SECONDARY FINDINGS:

SEX

- Distended stomach with fluid. The findings are most consistent with gastric ileus or less likely obstructive disease.

Spayed Female

AGE

9 years

INTERPRETATION OF THE FINDINGS & FURTHER RECOMMENDATIONS

There is severe inflammation and free fluid in the cranial abdomen dissecting between areas of what I suspect are abnormal pancreas and liver lobes. Additionally there is a more focal, hypoechoic area on the left side of the abdomen that is consistent with possible abnormal pancreatic tissue. The gallbladder and bile duct are thickened and irregular. The findings are concerning for either severe pancreatitis (possible necrotizing pancreatitis) with biliary inflammation/infection/triaditis or the possibility of infiltrative disease affecting the liver, biliary tract and pancreas. Diagnostically consider:

WEIGHT

5 kg

- A GI panel with a quantitative fPLI, TLI, cobalamin and folate to Texas A&M to further evaluate the pancreas and small intestine.
- Recommend a FNA of the pancreatic tissue on the left side (image provided for location) and of the liver to look for evidence of round cell neoplasia.
- I recommend medical therapy for cholangiohepatitis/pancreatitis with antibiotics, Ursodiol, Denamarin, pain medications, etc.
- Recommend three view thoracic radiographs
- Based on the blood work provided I suspect this patient may have diabetes. I recommend hospitalization for monitoring, support and insulin therapy if needed. A feeding tube may need to be considered.
- If the patient is declining and diagnostics are not providing more definitive diagnosis then consider obtaining biopsies of the liver, pancreas and evaluating the GI tract.

INTERPRETED BY

Kathleen Sennello
DVM, MS, Diplomate
ACVIM (Small Animal
Internal Medicine)

IMAGING PERFORMED BY

Erin Wicks

HOSPITAL NAME

Shores VEC

REFERRING VET

Dr. Miller

INVOICE

96110

DATE

2/17/22



PATIENT

Raisin Watson

SPECIES

Feline

BREED

Domestic Shorthair

SEX

Spayed Female

AGE

9 years

WEIGHT

5 kg

INTERPRETED BY

Kathleen Sennello
DVM, MS, Diplomate
ACVIM (Small Animal
Internal Medicine)

IMAGING PERFORMED BY

Erin Wicks

HOSPITAL NAME

Shores VEC

REFERRING VET

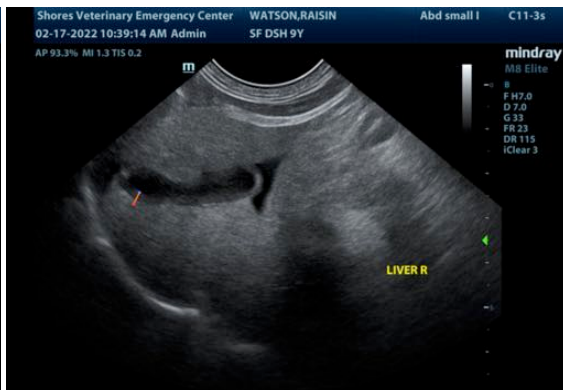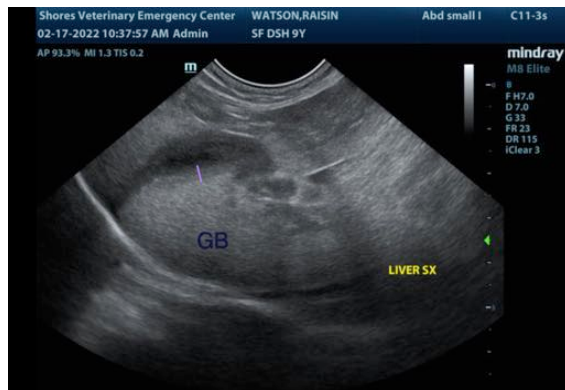
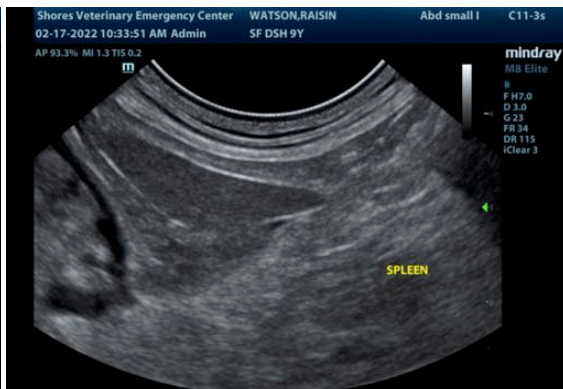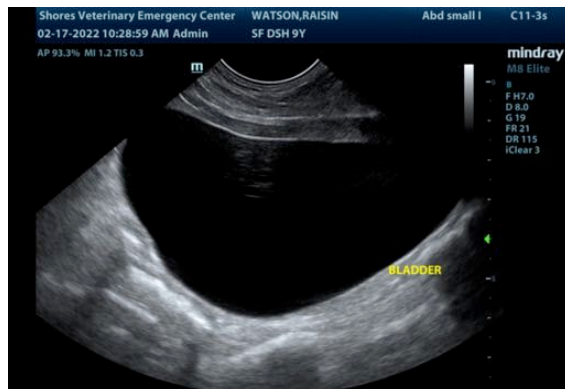
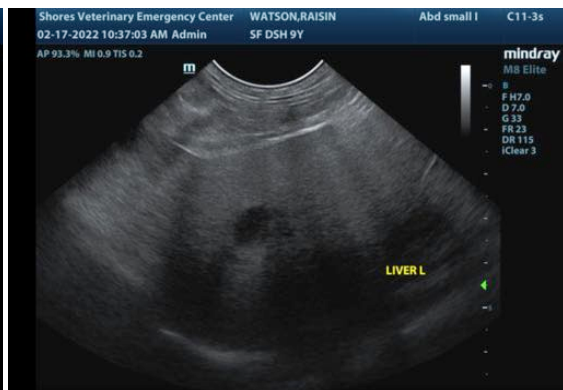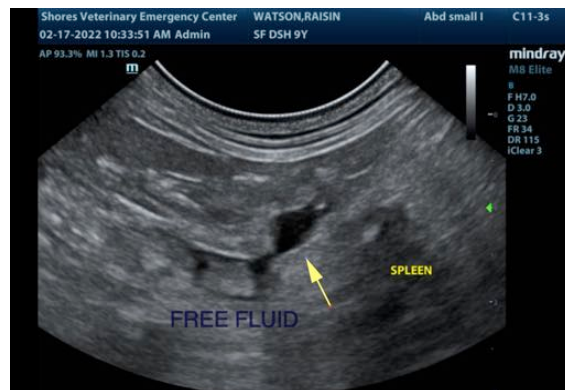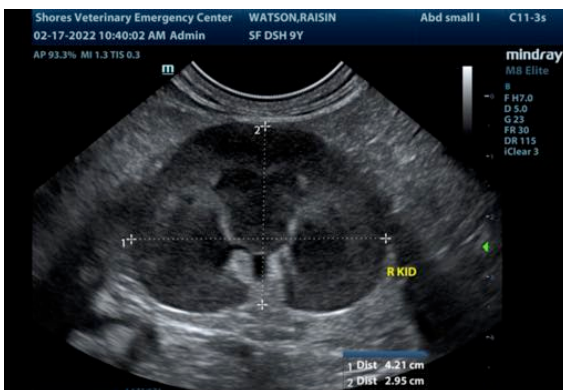
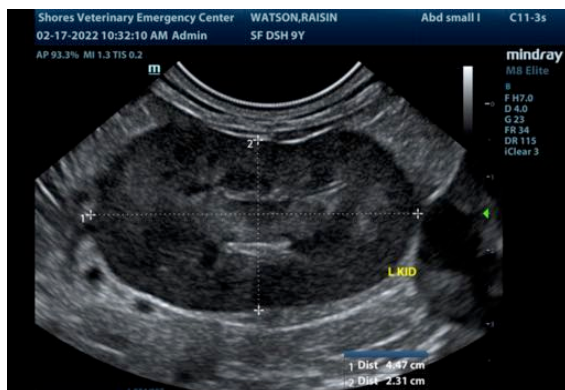
Dr. Miller

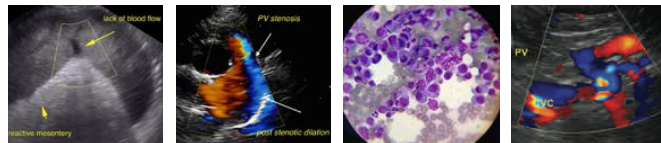
INVOICE

96110

DATE

2/17/22





PATIENT

Raisin Watson

SPECIES

Feline

BREED

Domestic Shorthair

SEX

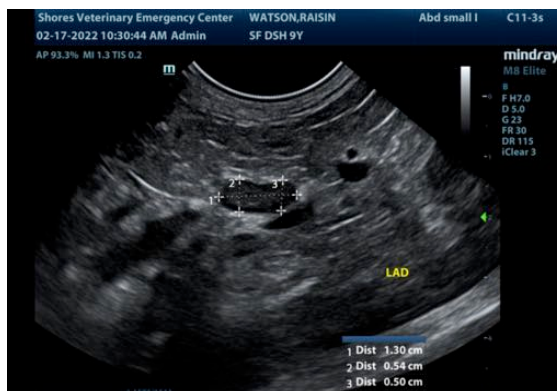
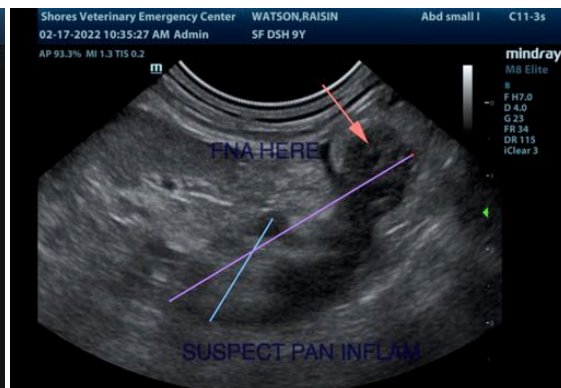
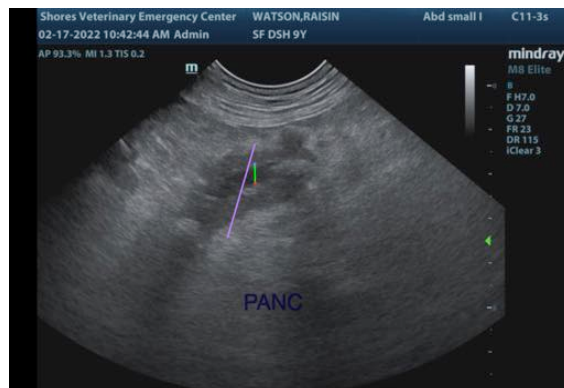
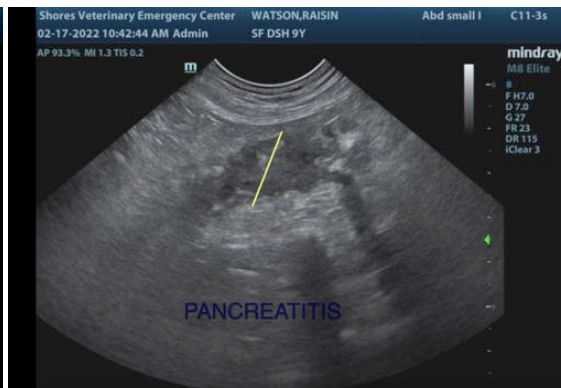
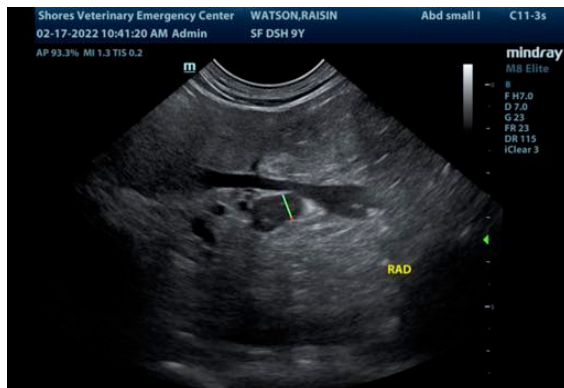
Spayed Female

AGE

9 years

WEIGHT

5 kg



INTERPRETED BY

Kathleen Sennello
DVM, MS, Diplomate
ACVIM (Small Animal
Internal Medicine)

IMAGING PERFORMED BY

Erin Wicks

HOSPITAL NAME

Shores VEC

REFERRING VET

Dr. Miller

INVOICE

96110

DATE

2/17/22

The information and recommendations provided are based on the images presented by the referring veterinarian/sonographer. No evaluation can be communicated regarding pathology that was not visible in the image/video clips provided.

Thank you for this referral. If the clinical or image interpretation does not parallel your findings or if I can be of any further assistance please contact me.

Kathleen Sennello DVM,MS, Diplomate ACVIM (Small animal Internal Medicine)
kathleen.sennello@sonopath.com