

**DATE**

2/17/22

PRESENTING CLINICAL SIGNS

History: Presented for the exam with concerns of inappropriate urination that began 1 month ago. Currently having 3-5 accidents in a week. No signs of leaking while awake or puddles after sleeping

Lab Results: UA/CX- NSF. Attached separately. When collecting urine samples bladder wall was very prominent and thickened. We will be submitting a Cadet braf Test as well.

Radiographs: Examined two view radiographs and uroliths/nephroliths- increased amounts of fecal material /ingesta present but still did not identify any in the regions of visibility. Attached separately.

Date of Previous IntraPet Ultrasound: No previous IntraPet scans.

Sedation: Not required to complete full diagnostic ultrasound.

Stat Report: Not requested.

Imaging Performed By: Rachel Brillhart, RDMS.

PATIENT

Bella Hilbert

SPECIES

Canine

BREED

Mix

SEX

Spayed Female

AGE

6/24/19

WEIGHT

69.6 lbs

ULTRASONOGRAPHIC EXAMINATION OF THE ABDOMEN**Urinary System**

The urinary bladder is moderately distended with anechoic urine. The bladder largely has a smooth mucosal surface. In some areas it can appear slightly prominent at 0.32 cm. These findings can be seen with diffuse cystitis, but are more likely consistent with lack of urine distension. I recommend urinalysis and culture.

The left kidney has a normal shape and size (6.89 cm). Overall echogenicity is normal with adequate corticomedullary distinction and a typical 1:3 cortex:medulla ratio. There is no evidence of perinephric inflammation or effusion. Mild pyelectasia was noted and measured 0.21 cm. There is no evidence of nephroliths, infarcts or hydronephrosis. Renal vasculature is normal.

The right kidney has a normal shape and size (6.51 cm). Overall echogenicity is normal with adequate corticomedullary distinction and a typical 1:3 cortex:medulla ratio. There is no evidence of perinephric inflammation or effusion. Mild pyelectasia was noted and measured 0.35 cm. There is no evidence of nephroliths, infarcts or hydronephrosis. Renal vasculature is normal.

INTERPRETED BY

Kathleen Sennello
DVM, MS, Diplomate
ACVIM (Small Animal
Internal Medicine)

Adrenal Glands

The left adrenal gland is normal in size measuring 0.93 cm at the caudal pole It is observed in its normal position cranial to the left renal artery. It is normal in appearance (uniformly hypoechoic) and shape with no evidence of a mass effect.

The right adrenal gland is normal in size measuring 0.77 cm at the caudal pole It is observed in its normal position between the cranial aspect of the right kidney and the caudal vena cava. It is normal in appearance (uniformly hypoechoic) and shape with no evidence of a mass effect.

HOSPITAL NAME

Noah's Ark Veterinary
Boarding Resort

Spleen

The spleen is subjectively normal in size, echotexture is homogenous, and the splenic capsule is smooth with no irregularities. The blood flow through the hilus and splenic parenchyma appears normal. No focal parenchymal abnormalities are visualized.

REFERRING VET

Dr. Martinez-
Hernandez

INVOICE

96130

Liver

The liver is subjectively normal in size, and echogenicity with smooth peripheral margins. The parenchyma is homogenous echotexture. The visible portions of the vasculature and biliary tract appear normal. No focal nodules or cystic lesions are observed. The gallbladder lumen is moderately distended. The wall of the gallbladder is not thickened and has a smooth mucosal surface. Luminal contents are primarily anechoic. The cystic and common bile ducts are normal/not visible.

Gastrointestinal

The stomach is moderately dilated with fluid and irregular shadowing material most consistent with normal ingesta and gas. It measures at a normal thickness of <0.7cm with some variability due to the presence of rugal folds. The distinction of the gastric wall layering is adequate and there is no impression of reduced peristaltic activity. No masses or focal lesions were observed.

The visualized areas of duodenum, jejunum and ileum have a relatively uniform diameter with minimal fluid distension. Wall thickness is normal. Bowel loops follow a curvilinear path with distinct wall layering maintaining the typical 1:3 muscularis:mucosa layer ratio. The duodenum measured as normal (between 0.3-0.5cm in wall thickness) and the jejunum measured as normal (between 0.2-0.47cm.) Visualized peristalsis appears appropriate. There were no focal lesions consistent with obstruction or a mass effect observed.

The ileocecal junction was visualized and exhibited normal intact wall layering and is subjectively of normal thickness. Sections of colon are visualized with formed fecal material and gas shadowing distally. There is no observed focal or generalized colon wall thickening or loss of layering.

Pancreas

The pancreas is normal and isoechoic to surrounding mesentery. There is no evidence of nodules or cystic lesions. There is no evidence of regional mesenteric inflammation or fluid.

Free Abdomen

Evaluation of the peritoneal cavity did not reveal any evidence of effusion, or subjective lymphadenomegaly. The Medial iliac nodes appear normal and there was no evidence of a caudal aortic thrombus at the bifurcation. The omentum is of normal uniform echogenicity.

ULTRASONOGRAPHIC FINDINGS

PRIMARY FINDINGS:

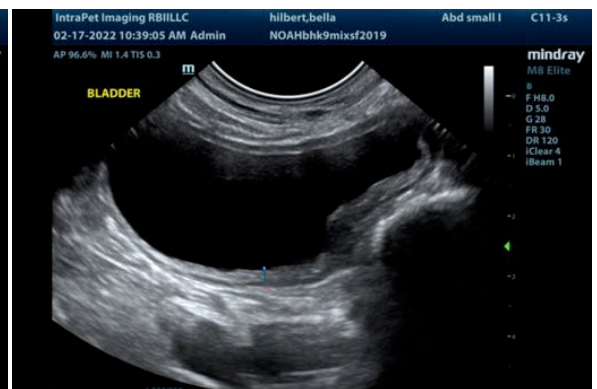
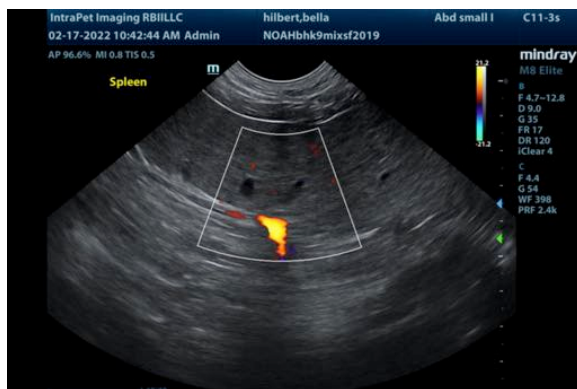
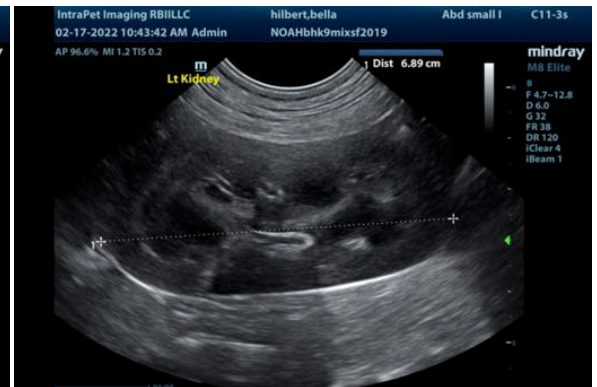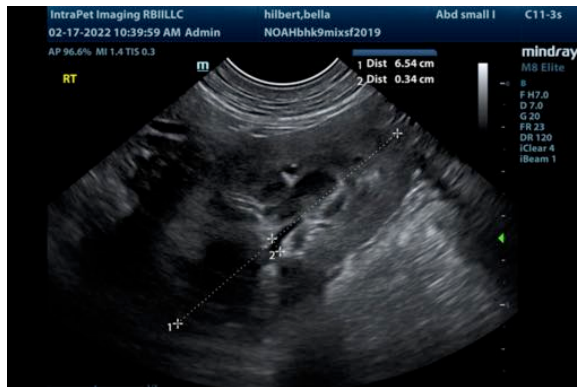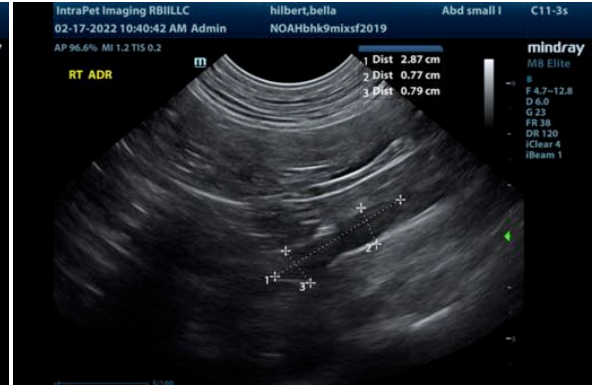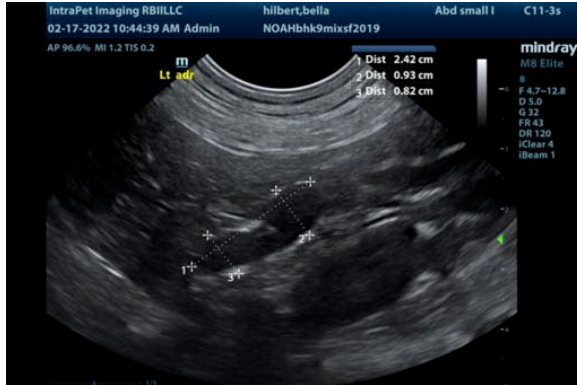- Bilateral mild pyelectasia. Pyelectasia of the left/right kidney could be consistent with pyelonephritis, chronic renal disease, secondary to PU/PD or fluid therapy (if applicable), other.

SECONDARY FINDINGS:

- Subjectively mildly prominent bladder wall the findings could be consistent with mild inflammation, but lack of urine distension is more likely the cause.

INTERPRETATION OF THE FINDINGS & FURTHER RECOMMENDATIONS

An obvious cause for the inappropriate urination is not visualized. There is mild pyelectasia of the kidneys that can be seen with pyelonephritis or PU/PD, etc. If not already done I recommend urinalysis and culture while off of antibiotics for at least a week. Also consider quantitating water intake and evaluation of urinalysis to see if urine is concentrated as this could be associated with increased intake. No stones or mass lesions are observed and there is no evidence of an ectopic ureter although some small ectopic ureters can be very difficult to see without a contrast study (contrast CT or excretory urogram). Additionally, a cystotomy can be considered to further evaluate the external urethra/vaginal vault, look for ectopic ureters, etc.



The information and recommendations provided are based on the images presented by the referring veterinarian. No evaluation can be communicated regarding pathology that was not visible in the image/video clips provided.

Thank you for this referral. If the clinical or image interpretation does not parallel your findings or if I can be of any further assistance please contact me.

Kathleen Sennello DVM,MS, Diplomate ACVIM (Small animal Internal Medicine)
kathleen.sennello@sonopath.com