

**DATE PRESENTING CLINICAL SIGNS**

2/16/23

Presents for chronic vomiting. Hx of 2-3 times per month but recently increased further and now having some diarrhea as well. Moderate gingivitis noted. About 1 lb of weight loss in past 5 months.

PATIENT

Freya Bozman

Current Medications: metronidazole 100mg/ml 0.6ml PO q12hr, proviable forte once daily, cerenia 24mg 1/2 tab PO once daily

Date of Previous IntraPet Ultrasound: No previous.

SPECIES

Feline

Sedation: dexmed 0.09 + torb 0.09ml IV.

Stat Report: Not requested.

BREED

DSH

Imaging Performed By: Rachel Brillhart, RDMS.

ULTRASONOGRAPHIC EXAMINATION OF THE ABDOMEN**SEX**

Spayed Female

Urinary System

The urinary bladder is moderately distended with anechoic urine. The Bladder wall, trigone, ureteral papillae and visible urethra (to a depth of 2cm) appear normal with no evidence of wall thickening, mucosal irregularities, masses or cystic calculi.

AGE

12/28/20

The left kidney has a normal shape and size (3.71 cm). Overall echogenicity is normal with adequate corticomedullary distinction and a typical 1:3 cortex:medulla ratio. There is no evidence of focal perinephric inflammation or effusion. There is no evidence of pyelectasia, nephroliths, infarcts or hydroureter. Renal vasculature is normal.

WEIGHT

9.37 Pounds

The right kidney has a normal shape and size (3.2 cm). Overall echogenicity is normal with adequate corticomedullary distinction and a typical 1:3 cortex:medulla ratio. There is no evidence of focal perinephric inflammation or effusion. There is no evidence of pyelectasia, nephroliths, infarcts or hydroureter. Renal vasculature is normal.

INTERPRETED BY

Kathleen Sennello DVM,
MS, Diplomate ACVIM
(Small Animal Internal
Medicine)

Adrenal Glands

The left adrenal gland is normal in size measuring 0.38 cm at the caudal pole. It is observed in its normal position cranial to the left renal artery. It is normal in appearance (uniformly hypoechoic) and shape with no evidence of a mass effect.

HOSPITAL NAME

Everhart Vet Hospital

The right adrenal gland is normal in size measuring 0.52 cm at the caudal pole. It is observed in its normal position between the cranial aspect of the right kidney and the caudal vena cava. It is normal in appearance (uniformly hypoechoic) and shape with no evidence of a mass effect.

REFERRING VET

Dr. Betta

Spleen

The spleen is subjectively normal in size (0.46 cm), echotexture is homogenous, and the splenic capsule is smooth with no irregularities. The blood flow through the hilus and splenic parenchyma appears normal. No focal parenchymal abnormalities are visualized.

INVOICE

45316

Liver

The liver is subjectively normal in size, and echogenicity with smooth peripheral margins. The parenchyma is homogenous echotexture. The visible portions of the vasculature and biliary tract appear normal. No focal nodules or cystic lesions are observed.

The gallbladder lumen is moderately distended. The wall of the gall bladder is not thickened and has a smooth mucosal surface. Luminal contents are mild and primarily anechoic. The cystic and common bile ducts are normal/not visible.

Gastrointestinal

The stomach contains minimal luminal contents. It measures at a normal thickness of <0.36cm with some variability due to the presence of rugal folds. The distinction of the gastric wall layers is adequate and there is no impression of reduced peristaltic activity. No masses or focal lesions were observed.

The visualized areas of duodenum, jejunum and ileum have a relatively uniform diameter with minimal fluid distension. Wall thickness is normal. Bowel loops follow a curvilinear path with distinct wall layering maintaining the typical 1:3 muscularis:mucosa layer ratio. Jejunum wall measures 0.16 cm. Visualized peristalsis appears appropriate. There were no focal lesions consistent with obstruction or a mass effect observed.

The ileocecal junction was visualized and exhibited normal intact wall layering and is subjectively of normal thickness. Sections of colon are visualized with formed fecal material and gas shadowing distally. There is no observed focal or generalized colon wall thickening or loss of layering.

Pancreas

The pancreas is normal and isoechoic to surrounding mesentery. There is no evidence of nodules or cystic lesions. There is no evidence of regional mesenteric inflammation or fluid.

Free Abdomen

Evaluation of the peritoneal cavity did not reveal any evidence of effusion, or subjective lymphadenomegaly. The Medial iliac nodes appear normal and there was no evidence of a caudal aortic thrombus at the bifurcation. The omentum is of normal uniform echogenicity.

ULTRASONOGRAPHIC FINDINGS

- No significant ultrasonographic lesions visualized

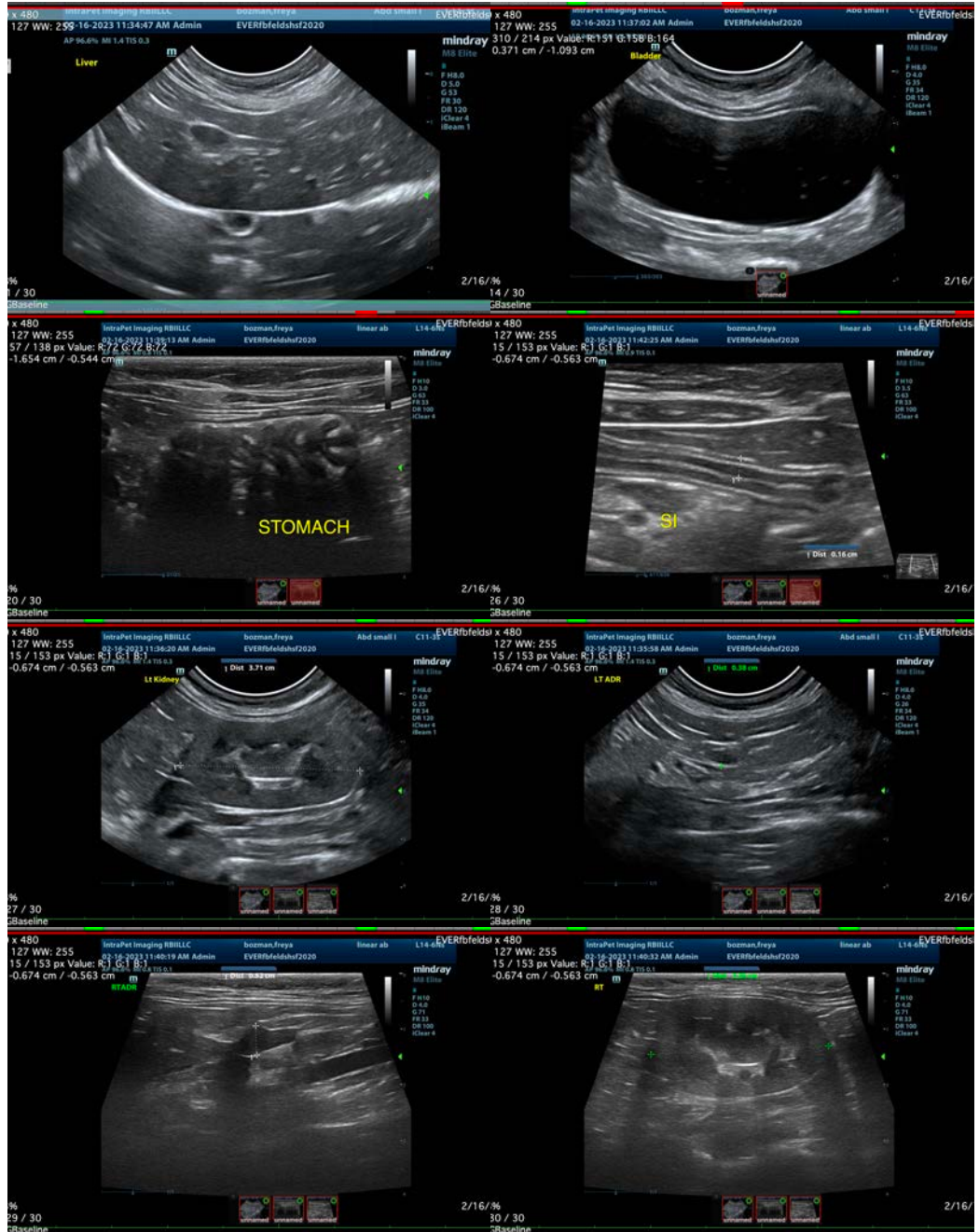
INTERPRETATION OF THE FINDINGS & FURTHER RECOMMENDATIONS

No focal lesions are visualized associated with the gastrointestinal tract to explain the chronic vomiting and diarrhea reported. Unfortunately, there are many causes for vomiting and diarrhea that cannot be diagnosed by ultrasound alone.

Consider such differentials as food allergy/dietary intolerance, GI parasitism, pancreatitis, dysbiosis, recurrent dietary indiscretion, IBD and less likely neoplasia, etc....

- Consider a novel protein/hydrolyzed protein diet (exclusively at least 4-6 weeks)
- Consider a GI panel to Texas A&M for evaluation of B12 levels, folate, PLI/TLI etc.. to further evaluate for pancreatic/small intestinal disease.
- Recommend chronic pre- and probiotic therapy.
- Consider empirical testing and deworming (if not already done).

If symptoms persist and underlying GI disease is strongly suspected, consider obtaining GI biopsies.



The information and recommendations provided are based on the images presented by the referring veterinarian/sonographer. No evaluation can be communicated regarding pathology that was not visible in the image/video clips provided.

Thank you for this referral. If the clinical or image interpretation does not parallel your findings or if I can be of any further assistance please contact me.

Kathleen Sennello DVM,MS, Diplomate ACVIM (Small animal Internal Medicine)
 kathleen.sennello@sonopath.com