



PATIENT

Charlie Gawne

SPECIES

Canine

BREED

Bearded Collie X

SEX

Neutered Male

AGE

7.5 Years

WEIGHT

96 Pounds

INTERPRETED BY

Kathleen Sennello DVM,
MS, Diplomate ACVIM
(Small Animal Internal
Medicine)

**IMAGING
PERFORMED BY**

Kelly Romero

HOSPITAL NAME

Countryside AH

REFERRING VET

Dr. Kerry Hoobler-Riek

INVOICE

45201

DATE

2/16/23

PRESENTING CLINICAL SIGNS

Significant weight loss (30 lb) in the last month. Intermittent vomiting, usually bile. Decreased appetite.

Abnormal PE/Chem/CBC/UA Results: Fever 103.5 Previous CBC end of last week (2/9) showed WBC 23,700 with neutrophilia, HCT 27% 10% reticulocytes 574 K/mcL. Chemistry showed ALT 203, ALP 218, T bili 9.9. No urinalysis A repeat CBC on 2/15 with clinical pathology review = HCT 24.7 w/ 2 nRBCs/100 WBC, reticulocytes 291 K/mcL, WBC 17,900 with neutrophilia and bands present. Smear evaluation showed moderate target cells, slightly toxic neutrophils, rouleaux's, negative agglutination. Patient was started on amoxi/Baytril.

ULTRASONOGRAPHIC EXAMINATION OF THE ABDOMEN

Urinary System

The urinary bladder is mildly to moderately distended with anechoic urine. The Bladder wall is diffusely mildly thickened (0.54 cm), and the mucosa is mildly irregular. The trigone, ureteral papillae, and visible urethra (to a depth of 2cm) appear normal with no evidence of severe mucosal irregularities, masses or cystic calculi. Findings are most consistent with bacterial cystitis or lack of urine distension.

Recommend urinalysis and culture.

The prostate is normal in size (1.08 cm) and shape for this neutered male dog. The parenchyma is homogenous and the external margins are smooth. The prostatic urethra appears normal with no evidence of irregularity, invasion, mass effect or calculi.

The left kidney has a normal shape and size (8.46 cm). Overall echogenicity is normal with adequate corticomedullary distinction and a typical 1:3 cortex:medulla ratio. There is no evidence of focal perinephric inflammation or effusion. There is no evidence of pyelectasia, nephroliths, infarcts or hydroureter. Renal vasculature is normal.

The right kidney has a normal shape and size (8.38 cm). Overall echogenicity is normal with adequate corticomedullary distinction and a typical 1:3 cortex:medulla ratio. There is no evidence of focal perinephric inflammation or effusion. There is no evidence of pyelectasia, nephroliths, infarcts or hydroureter. Renal vasculature is normal.

Adrenal Glands

The left adrenal gland is normal in size measuring 0.59 cm at the caudal pole. It is observed in its normal position cranial to the left renal artery. It is normal in appearance (uniformly hypoechoic) and shape with no evidence of a mass effect.

The right adrenal gland is normal in size measuring 0.72 cm at the caudal pole. It is observed in its normal position between the cranial aspect of the right kidney and the caudal vena cava. It is normal in appearance (uniformly hypoechoic) and shape with no evidence of a mass effect.

Spleen

The spleen is subjectively normal in size, echotexture is homogenous, and the splenic capsule is smooth with no irregularities. The blood flow through the hilus and splenic parenchyma appears normal. No focal parenchymal abnormalities are visualized.

Liver

The liver is subjectively normal in size, and hypoechoic with smooth peripheral margins. The parenchyma is heterogenous in echotexture with subtle, indistinct focal mottling. The visible portions of the vasculature and biliary tract appear normal. No focal nodules or cystic lesions are observed.



PATIENT

Charlie Gawne

The gall bladder lumen is significantly distended. Some areas of the wall appear mildly thickened with adherent debris. There is a large amount of primarily non-organized echogenic debris. The bile duct is difficult to visualize but appears somewhat dilated more distally at 0.50 cm.

SPECIES

Canine

Gastrointestinal

The stomach contains minimal luminal contents. It measures at a normal thickness of 0.46 cm in wall thickness with some variability due to the presence of rugal folds. The distinction of the gastric wall layers is adequate and there is no impression of reduced peristaltic activity. No masses or focal lesions were observed.

BREED

Bearded Collie X

SEX

Neutered Male

The visualized areas of duodenum, jejunum and ileum have a relatively uniform diameter with minimal fluid distension. Wall thickness is normal. Bowel loops follow a curvilinear path with distinct wall layering maintaining the typical 1:3 muscularis:mucosa layer ratio. Duodenum wall measures 0.50 cm. Jejunum wall measures 0.28 cm. Visualized peristalsis appears appropriate. There were no focal lesions consistent with obstruction or a mass effect observed.

AGE

7.5 Years

The ileocecal junction was visualized and exhibited normal intact wall layering and is subjectively of normal thickness. Sections of colon are visualized with formed fecal material and gas shadowing distally. There is no observed focal or generalized colon wall thickening or loss of layering.

WEIGHT

96 Pounds

Pancreas

The area of the pancreas is normal and isoechoic to surrounding mesentery. There is no evidence of nodules or cystic lesions. There is no evidence of regional mesenteric inflammation or fluid.

INTERPRETED BY

Kathleen Sennello DVM,
MS, Diplomate ACVIM
(Small Animal Internal
Medicine)

Free Abdomen

Evaluation of the peritoneal cavity did not reveal any evidence of effusion, or subjective lymphadenomegaly. The Medial iliac nodes appear normal and there was no evidence of a caudal aortic thrombus at the bifurcation. The omentum is of normal uniform echogenicity.

IMAGING PERFORMED BY

Kelly Romero

ULTRASONOGRAPHIC FINDINGS

- Thickened urinary bladder wall – The bladder mucosal changes could be consistent with cystitis or artifactual due to lack of adequate luminal distension. Bladder neoplasia cannot be ruled out but is considered unlikely in this patient.
- Heterogeneous liver – The diffuse hepatic changes are non-specific and could be consistent with vacuolar hepatopathy, nodular hyperplasia, inflammatory/immune-mediated disease, fibrosis, extramedullary hematopoiesis, toxic hepatopathy (e.g., copper), infiltrative neoplasia (less likely) or other hepatopathy.
- Significantly distended gallbladder with moderate sludge, some of which is adhered to the gallbladder wall, and mild to moderate bile duct dilation – Dilation of the common bile duct could be consistent with a functional obstruction (i.e. primary hepatic disease resulting in hepatocellular swelling) or with an extrahepatic bile duct obstruction (ie. choledocholith, bile duct tumor, pancreatic disease, other).

HOSPITAL NAME

Countryside AH

REFERRING VET

Dr. Kerry Hoobler-Riek

INVOICE

45201

DATE

2/16/23

INTERPRETATION OF THE FINDINGS & FURTHER RECOMMENDATIONS

A source for the elevated bilirubin is not definitively identified. The gallbladder does have a large amount of intraluminal material and a dilated bile duct. I am unable to identify a clear obstruction, and although the gallbladder appears abnormal, there is minimal surrounding inflammation, etc. at this time. The liver itself does appear somewhat heterogeneous, so primary parenchymal disease is also a



PATIENT

Charlie Gawne

SPECIES

Canine

BREED

Bearded Collie X

SEX

Neutered Male

AGE

7.5 Years

WEIGHT

96 Pounds

INTERPRETED BY

Kathleen Sennello DVM,
MS, Diplomate ACVIM
(Small Animal Internal
Medicine)

**IMAGING
PERFORMED BY**

Kelly Romero

HOSPITAL NAME

Countryside AH

REFERRING VET

Dr. Kerry Hoobler-Riek

INVOICE

45201

DATE

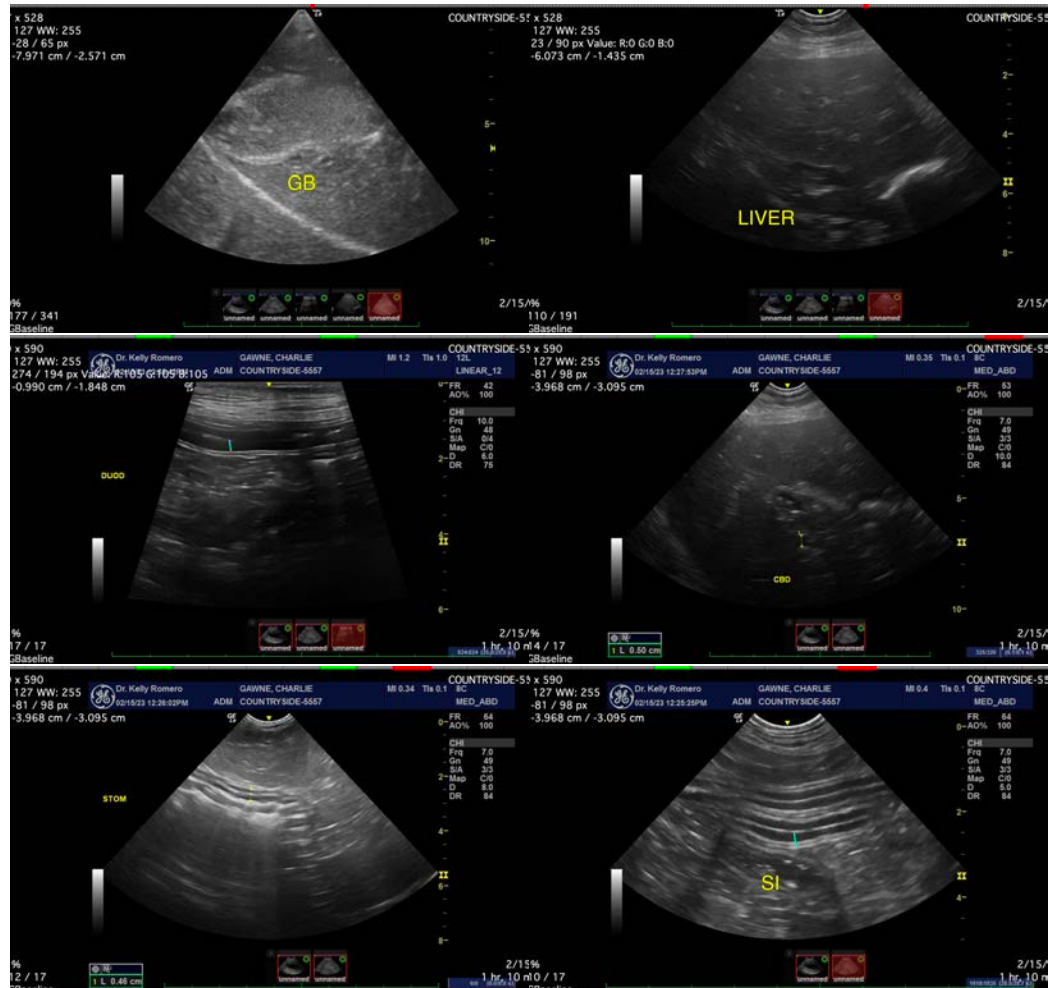
2/16/23

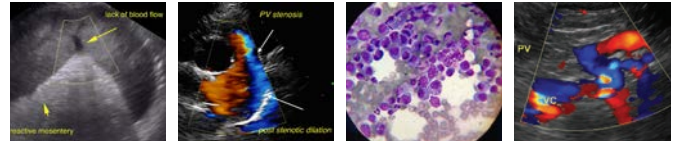
possibility. Consider a fine needle aspirate of the liver provided coagulation parameters are normal, and consider testing for Leptospirosis.

The anemia reported appears regenerative, so your concerns for possible hemolysis/immune mediated disease are valid. Also consider vector borne disease testing, and the possibility of this being an anemia of chronic disease, given the chronicity of the symptoms. Based on today's ultrasound I cannot definitively rule out a biliary obstruction, although this seems less likely, and a primary hepatopathy is also possible.

The fever in this patient could be secondary to an inflammatory infectious process, as sepsis does cause cholestatic disease as well, but typically the bilirubin isn't this high. Consider looking for other sources of infection such as culturing the urine, listening for a new heart murmur, etc. Consider reevaluation of the gallbladder in 24-48 hours, looking for any progression of this lesion, acquiring longitudinal and transverse views, including surrounding parenchyma and color flow to try and evaluate it in its entirety with surrounding tissue. This is a challenging patient to image due to its size and concurrent panting.

Recommend three view thoracic radiographs to evaluate for possible concurrent thoracic disease/involvement.





PATIENT

Charlie Gawne

SPECIES

Canine

BREED

Bearded Collie X

SEX

Neutered Male

AGE

7.5 Years

WEIGHT

96 Pounds

INTERPRETED BY

Kathleen Sennello DVM,
MS, Diplomate ACVIM
(Small Animal Internal
Medicine)

**IMAGING
PERFORMED BY**

Kelly Romero

HOSPITAL NAME

Countryside AH

REFERRING VET

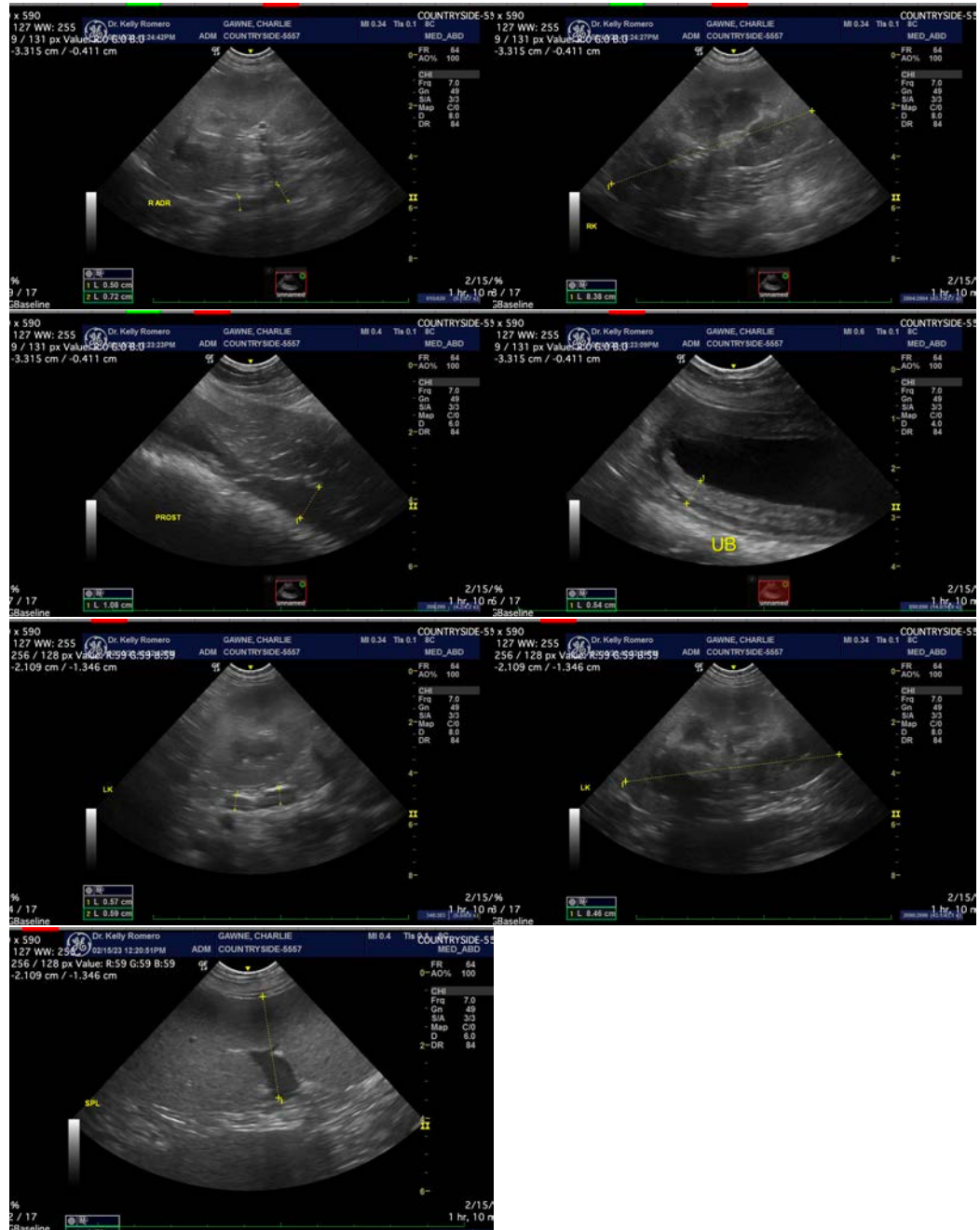
Dr. Kerry Hoobler-Riek

INVOICE

45201

DATE

2/16/23



The information and recommendations provided are based on the images presented by the referring veterinarian/sonographer. No evaluation can be communicated regarding pathology that was not visible in the image/video clips provided.

Thank you for this referral. If the clinical or image interpretation does not parallel your findings or if I can be of any further assistance please contact me.

Kathleen Sennello DVM,MS, Diplomate ACVIM (Small animal Internal Medicine)

kathleen.sennello@sonopath.com