

IMAGING PERFORMED BY

IntraPet.com



SonoPath

Clinical Sonography & Telecytology

EDUCATIONAL TELECONSULTATION SERVICES™

1-800-838-4268 info@sonopath.com SonoPath.com

DATE PRESENTING CLINICAL SIGNS

2/16/23

First time patient for evaluation of uncontrolled diabetes, potential cruciate rupture and potential abdominal mass noted on radiographs at another clinic on 1/31/2023. Ruptured CCL RH on exam, TPLO plate from previous L CCL Sx palpable, difficult to perform abdominal palpation remaining PE largely unremarkable.

PATIENT

Bailey Meyers

Current Medications: pro zinc insulin 17 u BID, proin 50 mg BID
Lab Results: bloodwork performed 1/06/2023 elsewhere BG 442 ALP 285 otherwise unremarkable.
Radiographs: See attached.

SPECIES

Canine

Date of Previous IntraPet Ultrasound: No previous.

BREED

Labrador Retriever

Sedation: Midazolam 0.2 mg/kg. Adequate sedation required if further imaging recommended.

Stat Report: Not requested.

Imaging Performed By: Rachel Brillhart, RDMS.

SEX

Spayed Female

ULTRASONOGRAPHIC EXAMINATION OF THE ABDOMEN

AGE

1/27/16

Urinary System

The urinary bladder is moderately distended with anechoic urine. The Bladder wall, trigone, ureteral papillae and visible urethra (to a depth of 2cm) appear normal with no evidence of wall thickening, mucosal irregularities, masses or cystic calculi.

WEIGHT

81.6 Pounds

The left kidney has a normal shape and size (7.22 cm). Overall echogenicity is normal with adequate corticomedullary distinction and a typical 1:3 cortex:medulla ratio. There is no evidence of focal perinephric inflammation or effusion. There is no evidence of pyelectasia, nephroliths, infarcts or hydroureter. Renal vasculature is normal.

INTERPRETED BY

Kathleen Sennello DVM,
MS, Diplomate ACVIM
(Small Animal Internal
Medicine)

The right kidney has a normal shape and size (7.41 cm). Overall echogenicity is normal with adequate corticomedullary distinction and a typical 1:3 cortex:medulla ratio. There is no evidence of focal perinephric inflammation or effusion. There is no evidence of pyelectasia, nephroliths, infarcts or hydroureter. Renal vasculature is normal.

HOSPITAL NAME

Pleasantville AH

Adrenal Glands

The left adrenal gland is normal in size measuring 0.64 cm at the caudal pole. It is observed in its normal position cranial to the left renal artery. It is normal in appearance (uniformly hypoechoic) and shape with no evidence of a mass effect.

REFERRING VET

Dr. Gounaris

The right adrenal gland is normal in size measuring 1.05 cm at the cranial pole, 0.68 cm at the caudal pole, and 2.75 cm in length, but it is slightly irregular in appearance in that there is a hyperechoic nodule in the cranial pole measuring 0.91 cm x 0.66 cm, which does not appear to significantly deform the adrenal. There is no evidence of vascular invasion observed. The adrenal is observed in its normal position between the cranial aspect of the right kidney and the caudal vena cava.

INVOICE

45317

Spleen

The spleen is subjectively normal in size, echotexture is homogenous, and the splenic capsule is smooth with no irregularities. The blood flow through the hilus and splenic parenchyma appears normal. No focal parenchymal abnormalities are visualized.

Liver

The liver is large in size, and hyperechoic with smooth peripheral margins. The parenchyma is heterogenous in echotexture with subtle, indistinct focal mottling. The visible portions of the vasculature and biliary tract

appear normal. There are numerous ill-defined hypoechoic nodules throughout the hepatic parenchyma varying in size from 0.25-1.0 cm.

The gallbladder lumen is moderately distended. The wall of the gall bladder is not thickened and has a smooth mucosal surface. Luminal contents are mild and primarily anechoic. The cystic and common bile ducts are normal/not visible.

Gastrointestinal

The stomach contains minimal luminal contents. It measures at a normal thickness of <0.7cm with some variability due to the presence of rugal folds. The distinction of the gastric wall layers is adequate and there is no impression of reduced peristaltic activity. No masses or focal lesions were observed.

The visualized areas of duodenum, jejunum and ileum have a relatively uniform diameter with mild to moderate fluid and chyme dilation. Wall thickness is normal. Bowel loops follow a curvilinear path with distinct wall layering maintaining the typical 1:3 muscularis:mucosa layer ratio. Jejunum wall measures 0.34 cm. Visualized peristalsis appears appropriate. There were no focal lesions consistent with obstruction or a mass effect observed.

The ileocecal junction was visualized and exhibited normal intact wall layering and is subjectively of normal thickness. Sections of colon are visualized with formed fecal material and gas shadowing distally. There is no observed focal or generalized colon wall thickening or loss of layering.

Pancreas

The pancreas is normal and isoechoic to surrounding mesentery. There is no evidence of nodules or cystic lesions. There is no evidence of regional mesenteric inflammation or fluid.

Free Abdomen

Evaluation of the peritoneal cavity did not reveal any evidence of effusion, or subjective lymphadenomegaly. The Medial iliac nodes appear normal and there was no evidence of a caudal aortic thrombus at the bifurcation. The omentum is of normal uniform echogenicity.

ULTRASONOGRAPHIC FINDINGS

- Large, hyperechoic, heterogeneous liver with ill-defined hypoechoic nodules – The diffuse hepatic changes are non-specific and could be consistent with vacuolar hepatopathy, nodular hyperplasia, inflammatory/immune-mediated disease, fibrosis, extramedullary hematopoiesis, toxic hepatopathy (e.g., copper), infiltrative neoplasia (less likely) or other hepatopathy. This is most consistent with a diabetic hepatopathy, although it is pronounced, and the nodular pattern is significant and still most consistent with a benign process. Consider a fine needle aspirate.
- Hyperechoic nodule in the cranial pole of the right adrenal gland – Adrenomegaly could be consistent with neoplasia (e.g., adenoma, carcinoma, pheochromocytoma), hyperplasia, inflammation, other.

INTERPRETATION OF THE FINDINGS & FURTHER RECOMMENDATIONS

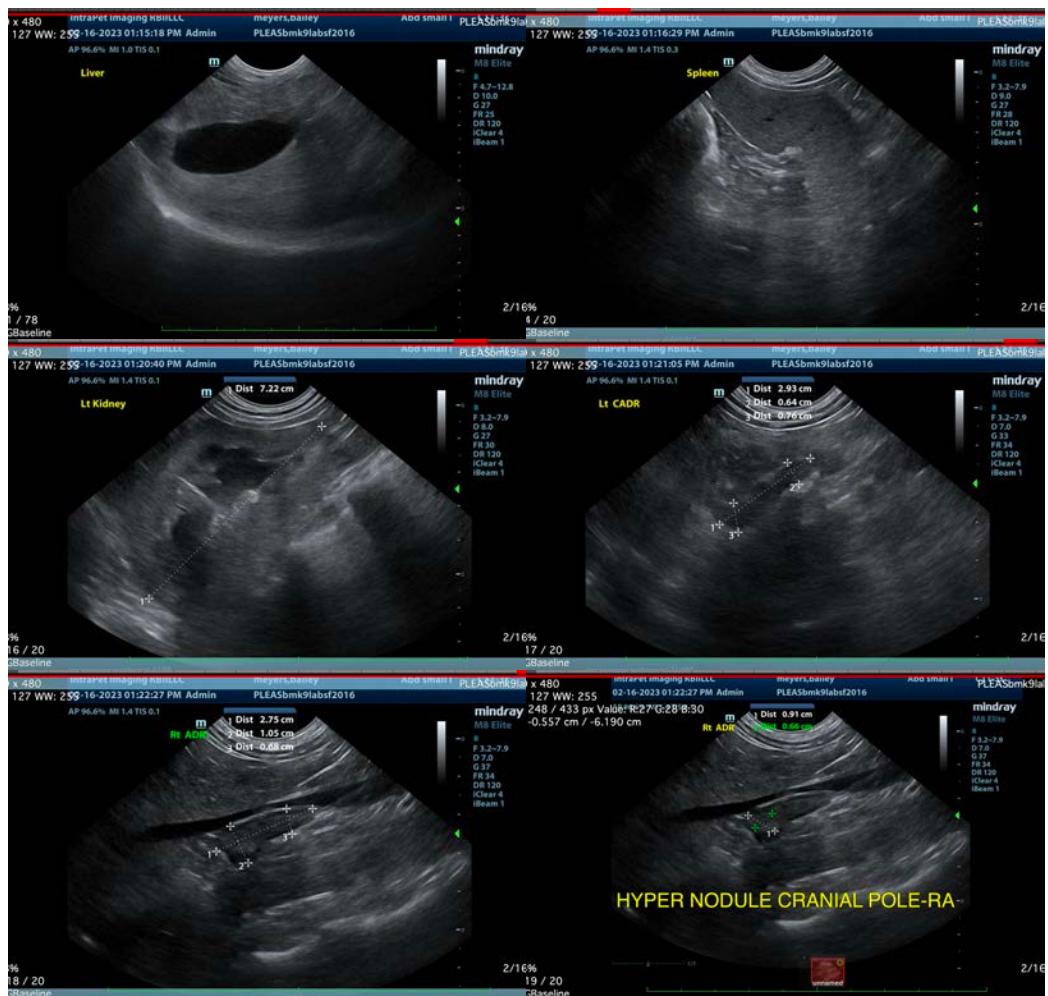
The liver is large and hyperechoic with ill-defined hypoechoic nodules. These changes could be consistent with a diabetic hepatopathy and regenerative nodules, but given the pronounced nature of these nodules, a fine needle aspirate could be considered (provided coagulation parameters are normal).

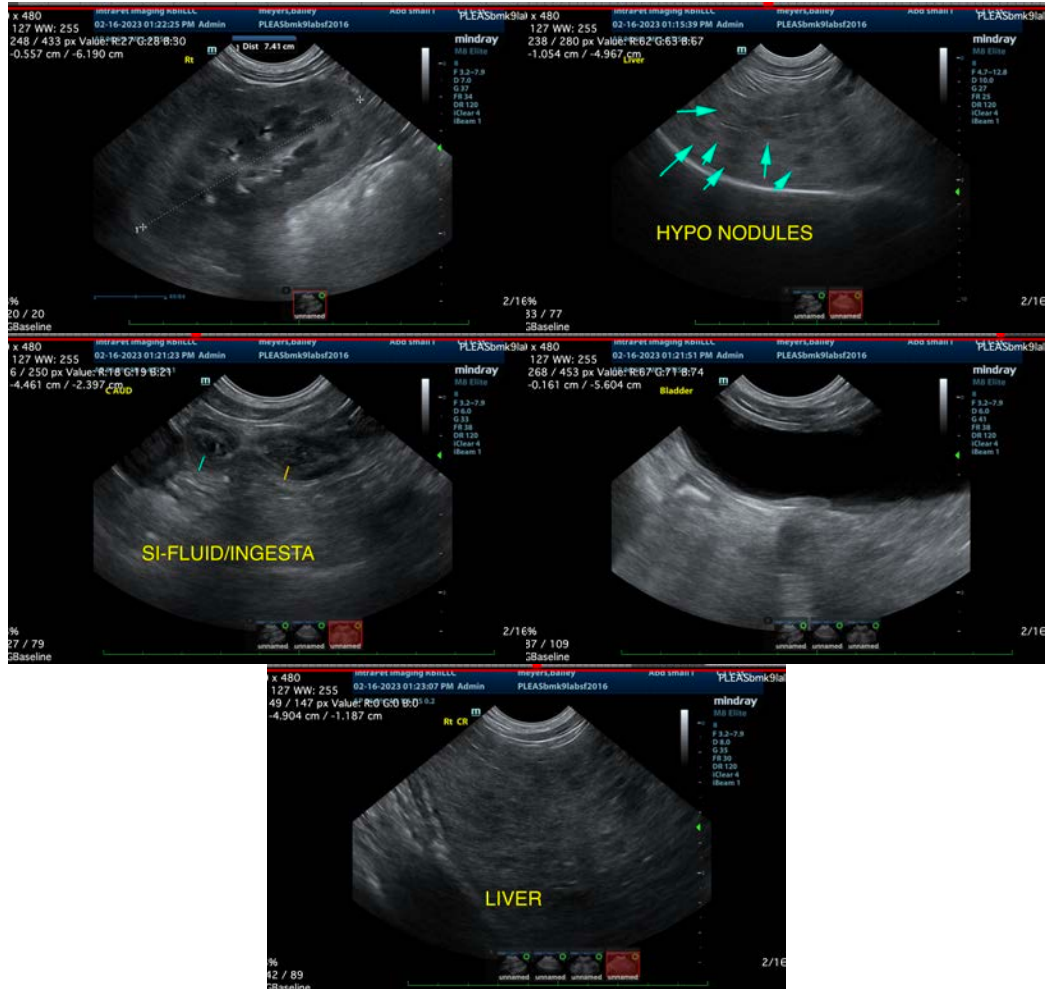
Additionally, there is a hyperechoic nodule in the cranial pole of the right adrenal gland. This is relatively small and does not significantly deform the adrenal gland. This could represent a benign lesion (hyperplasia, etc.), or a neoplastic lesion, pheochromocytoma, carcinoma, etc., and could be actively secreting hormone or

be non-active. It can be complicated to work up an adrenal nodule concurrently with diabetes, as the symptoms for Cushing's overlap diabetes significantly, and the diabetes can falsely elevate cortisol levels. Initially consider a blood pressure evaluation. If hypertension is present, recommend measuring catecholamine levels. Next step would likely be to continue working on controlling the diabetes. Recommend urinalysis and culture and glucose curves to try and determine if this is a matter of inadequate response to insulin, too long or short duration of insulin, etc. This is a low dose of insulin for this individual (0.2 units/lb twice daily). Insulin resistance is defined as over 1.0 unit/lb twice daily, so there may be room for increasing the dose if the response to insulin appears inadequate.

Once this patient's diabetes is better controlled, consider reevaluation of the adrenal nodule. It should be reimaged with ultrasound in 2-4 months to ensure it is not growing rapidly, and you could consider an ACTH stimulation test if symptoms of Cushing's are present despite adequate glycemic control.

Recommend three view thoracic radiographs to evaluate for possible concurrent thoracic disease/involvement.





The information and recommendations provided are based on the images presented by the referring veterinarian/sonographer. No evaluation can be communicated regarding pathology that was not visible in the image/video clips provided.

Thank you for this referral. If the clinical or image interpretation does not parallel your findings or if I can be of any further assistance please contact me.

Kathleen Sennello DVM,MS, Diplomate ACVIM (Small animal Internal Medicine)
 kathleen.sennello@sonopath.com