

**DATE**

2/16/22

PRESENTING CLINICAL SIGNS

Patient had recheck bloodwork for use of Denamarin. P has been off Denamarin for 3 weeks, Client was giving 1/2 tablet instead of 1 tab, client though too much medicine, p has lost 2 lbs since November. P does have grade 2/6 heart murmur; doctor wants to evaluate liver.

PATIENT

Maddie Bryant

Current Medications: Denamarin 1/2 tab every 24 hours on empty stomach. Client was to give 1 tablet.

Lab Results: Liver values significantly increased. SDMA 23, BUN 32

ALT 1993, ALP 1087. Attached separately.

Date of Previous IntraPet Ultrasound: No previous IntraPet scans.

Sedation: Declined.

SPECIES

Canine

Stat Report: Not requested.

Imaging Performed By: Andi Parkinson, RDMS

BREED

Coton de Tulear

ULTRASONOGRAPHIC EXAMINATION OF THE ABDOMEN**Urinary System**

The urinary bladder is minimally distended with urine. Visualization and interpretation of the urinary bladder is difficult. No obvious calculi or mass lesions are observed.

SEX

Spayed Female

The right kidney has a normal shape and size (3.36 cm). Overall echogenicity is slightly hyperechoic with poor corticomedullary distinction and a typical 1:3 cortex:medulla ratio. There is no evidence of perinephric inflammation or effusion. There is no evidence of pyelectasia, nephroliths, infarcts or hydroureter. Renal vasculature is normal.

AGE

5/8/08

The right kidney has a normal shape and size (3.43 cm). Overall echogenicity is slightly hyperechoic with poor corticomedullary distinction and a typical 1:3 cortex:medulla ratio. There is no evidence of perinephric inflammation or effusion. There is no evidence of pyelectasia, nephroliths, infarcts or hydroureter. Renal vasculature is normal.

WEIGHT

5.4 lbs

INTERPRETED BY

Kathleen Sennello
DVM, MS, Diplomate
ACVIM (Small Animal
Internal Medicine)

Adrenal Glands

The left adrenal gland is normal in size measuring 0.47 cm at the caudal pole It is observed in its normal position cranial to the left renal artery. It is normal in appearance (uniformly hypoechoic) and shape with no evidence of a mass effect.

The right adrenal gland is normal in size measuring 0.36 cm at the caudal pole It is observed in its normal position between the cranial aspect of the right kidney and the caudal vena cava. It is normal in appearance (uniformly hypoechoic) and shape with no evidence of a mass effect.

HOSPITAL NAME

Eldersburg VH

Spleen

The spleen is subjectively (normal or large) in size The spleen echotexture is heterogenous and mottled, the splenic capsule is smooth with no irregularities. The blood flow through the hilus and splenic parenchyma appears normal. Two mass lesions are observed in the spleen. A smaller mass lesion is noted in the head of the spleen and it is irregular with mixed echogenicity measuring 1.5 x 1.69 cm. This lesion is somewhat pedunculated and disrupts the splenic capsule. The second mass lesion is more towards the tail of the spleen and measures 1.81 x 1.87 cm. This is more rounded and somewhat isoechoic, but still disrupts the splenic capsule.

REFERRING VET

Dr. Alper

INVOICE

96104

Liver

The liver is subjectively normal in size, and echogenicity with smooth peripheral margins. The parenchyma is homogenous echotexture. The visible portions of the vasculature and biliary tract appear normal. No focal nodules or cystic lesions are observed. The gallbladder lumen is moderately distended with largely anechoic

interluminal material. The gallbladder wall appears normal. In some images there is the hint of a dilated bile duct measuring 0.47 cm. This is lost more distally due to patient panting, etc. Sedation would be required for further imaging. No obstructions are visualized.

Gastrointestinal

The stomach is moderately dilated with fluid and irregular shadowing material most consistent with normal ingesta and gas. It measures at a normal thickness of <0.7cm with some variability due to the presence of rugal folds. The distinction of the gastric wall layering is adequate and there is no impression of reduced peristaltic activity. No masses or focal lesions were observed.

The visualized areas of duodenum, jejunum and ileum have a relatively uniform diameter with minimal fluid distension. Wall thickness is normal. Bowel loops follow a curvilinear path with distinct wall layering maintaining the typical 1:3 muscularis:mucosa layer ratio. The duodenum measured as normal (between 0.3-0.5cm in wall thickness) and the jejunum measured as normal (between 0.2-0.47cm.) Visualized peristalsis appears appropriate. There were no focal lesions consistent with obstruction or a mass effect observed.

The ileocecal junction was visualized and exhibited normal intact wall layering and is subjectively of normal thickness. Sections of colon are visualized with formed fecal material and gas shadowing distally. There is no observed focal or generalized colon wall thickening or loss of layering.

Pancreas

The pancreas is normal and isoechoic to surrounding mesentery. There is no evidence of nodules or cystic lesions. There is no evidence of regional mesenteric inflammation or fluid.

Free Abdomen

Evaluation of the peritoneal cavity did not reveal any evidence of effusion, or subjective lymphadenomegaly. The Medial iliac nodes appear normal and there was no evidence of a caudal aortic thrombus at the bifurcation. The omentum is of normal uniform echogenicity.

Heart

A brief view of the heart was submitted. No pericardial effusion was seen.

ULTRASONOGRAPHIC FINDINGS

PRIMARY FINDINGS:

- Two splenic mass lesions visualized- these lesions could be either benign or malignant lesions, but there is concern that both disrupt the splenic capsule.
- Questionable prominent/dilation of the common bile duct. The significance of this is unclear, but no obvious obstruction is noted.

SECONDARY FINDINGS:

- Moderate distension of the gastric lumen with shadowing material. Shadowing material in the gastric lumen - correlate with feeding history and abdominal radiographs. If this patient was adequately fasted consider such differentials as delayed gastric emptying, ingested foreign material or a partial outflow tract obstruction (none observed.)
- Decreased corticomedullary distinction in both kidneys. The bilateral renal findings are consistent

with age-related change.

- Lack of urine distension of the urinary bladder prohibits full evaluation.

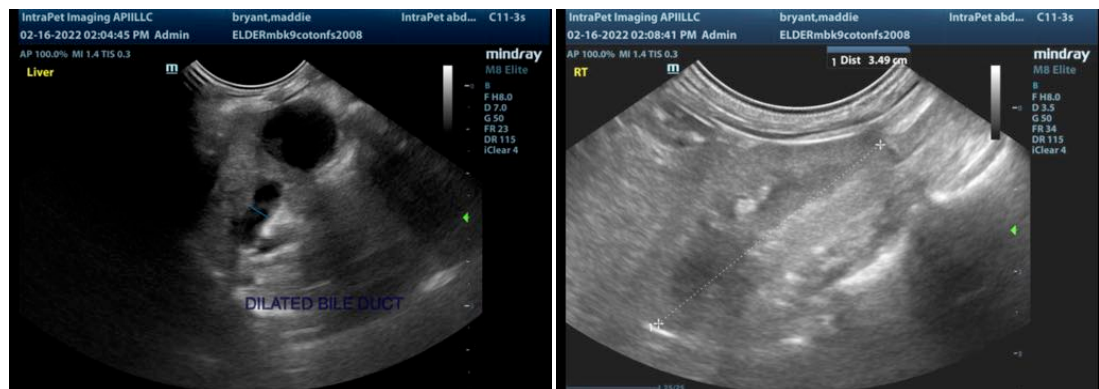
INTERPRETATION OF THE FINDINGS & FURTHER RECOMMENDATIONS

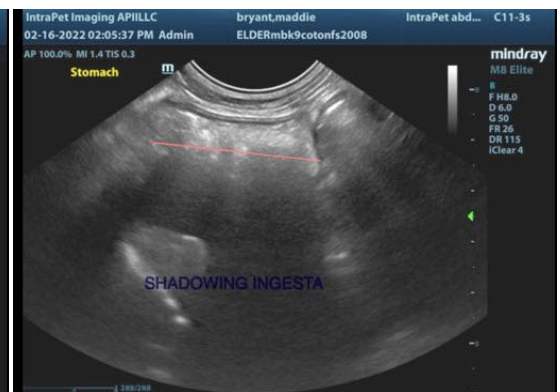
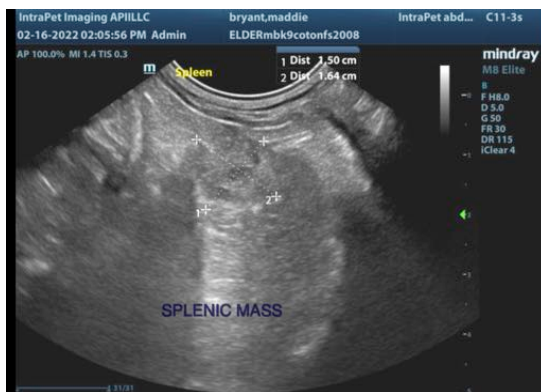
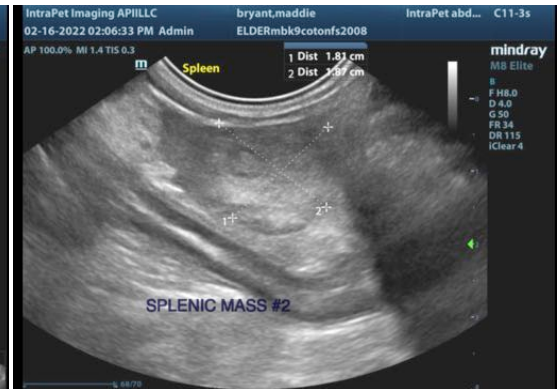
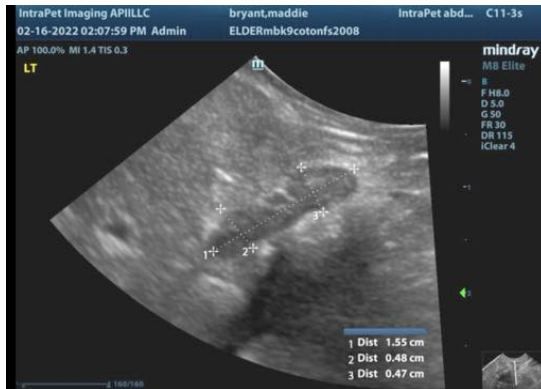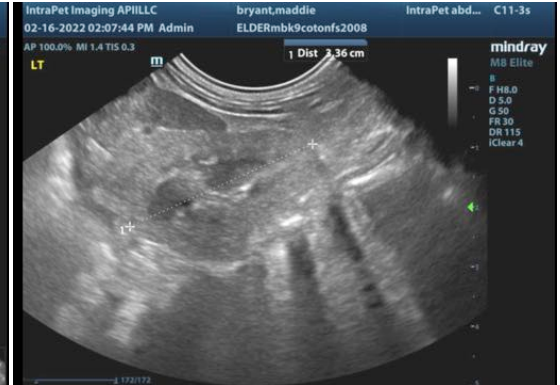
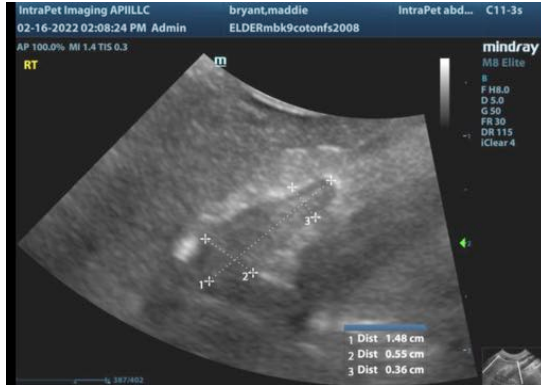No significant lesions are visualized associated with the liver. The gallbladder is somewhat distended and the bile duct appears prominent, but I am unable to follow this largely due to patient panting and confirmation (deep chested intercostal views). An obvious cause for the elevation of liver values is not observed. Additionally I do not see a bilirubin level on recent blood work.

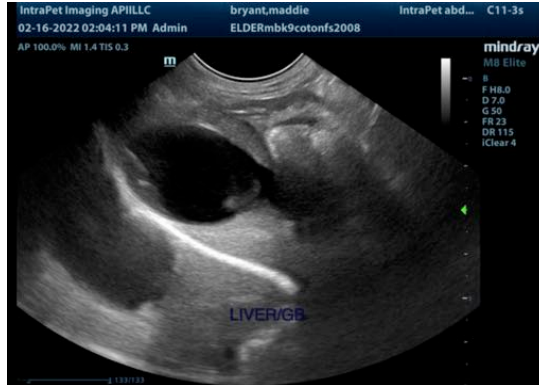- Consider close evaluation of history for possible toxic changes examine medications, diet, dietary indiscretion etc...
- Consider PCR on urine/serum for leptospirosis (if not on antibiotics)/serology if recent antibiotic history
- If not already done, consider pre and post prandial bile acids to evaluate liver function
- Consider Fine needle aspirate if round cell neoplasia is on your differentia list (25 g needle, normal coags)
- If no response to supportive care (Denamarin, fluids, antibiotics,+/- Ursodiol etc...) Consider liver biopsy with samples obtained for histopathology, culture, and copper levels.
- If bilirubin levels are elevated and are not improving consider reevaluation of the biliary tract for progressive distension and I recommend treatment with Ursodiol and antibiotics.

There are two mass lesions on the spleen. The appearance of these mass lesions is concerning as they disrupt the splenic capsule. Minimal cavitation is present. Ideally surgery to remove the spleen would be performed for both diagnostic and therapeutic purposes. Otherwise, a FNA could be considered or close continued monitoring.

I recommend three view thoracic radiographs.







The information and recommendations provided are based on the images presented by the referring veterinarian. No evaluation can be communicated regarding pathology that was not visible in the image/video clips provided.

Thank you for this referral. If the clinical or image interpretation does not parallel your findings or if I can be of any further assistance please contact me.

Kathleen Sennello DVM,MS, Diplomate ACVIM (Small animal Internal Medicine)
kathleen.sennello@sonopath.com