

**DATE PRESENTING CLINICAL SIGNS**

2/15/23

Tom presented today for evaluation of a mass on his dorsal right scapula and lateral thorax that has been present since 2019 and getting larger. A bone biopsy was performed by his regular veterinarian in October, 2019, which was consistent normal bone and cartilage. In June, 2022, radiographs were performed by his regular vet and the mass had grown significantly. At that time, Tom was still moving around well with a moderate right thoracic limb lameness but his veterinarian recommended seeing a specialist for surgical removal.

PATIENT

Tom Reichert

SPECIES

Feline

Current Medications: No current medications.

Radiographs: No evidence of pulmonary metastatic disease detected on thoracic radiographs. Cardiac silhouette WNL.

BREED

DSH

Date of Previous IntraPet Ultrasound: No previous.

Sedation: Not required to complete full diagnostic ultrasound.

Stat Report: Not requested.

Imaging Performed By: Andi Parkinson, BS, RDMS.

SEX

Neutered Male

ULTRASONOGRAPHIC EXAMINATION OF THE ABDOMEN**AGE**

2/14/11

Urinary System

The urinary bladder is moderately distended with anechoic urine. The Bladder wall, trigone, ureteral papillae and visible urethra (to a depth of 2cm) appear normal with no evidence of wall thickening, mucosal irregularities, masses or cystic calculi.

WEIGHT

8.8 kg

The left kidney has a normal shape and size (4.18 cm). Overall echogenicity is normal with adequate corticomedullary distinction and a typical 1:3 cortex:medulla ratio. There is no evidence of focal perinephric inflammation or effusion. There is no evidence of pyelectasia, nephroliths, infarcts or hydroureter. Renal vasculature is normal.

INTERPRETED BY

Kathleen Sennello DVM,
MS, Diplomate ACVIM
(Small Animal Internal
Medicine)

The right kidney has a normal shape and size (4.08 cm). Overall echogenicity is normal with adequate corticomedullary distinction and a typical 1:3 cortex:medulla ratio. There is no evidence of focal perinephric inflammation or effusion. There is no evidence of pyelectasia, nephroliths, infarcts or hydroureter. Renal vasculature is normal.

HOSPITAL NAME

Nexus Vet Specialists

Adrenal Glands

The left adrenal gland is normal in size measuring 0.57 cm at the caudal pole. It is observed in its normal position cranial to the left renal artery. It is normal in appearance (uniformly hypoechoic) and shape with no evidence of a mass effect.

REFERRING VET

Dr. Havemann

The region of the right adrenal (between right cranial kidney and vena cava) is unremarkable, but the adrenal is not distinctly visualized. No evidence of a mass effect is visualized.

INVOICE

45146

Spleen

The spleen is subjectively normal in size (0.62 cm), echotexture is homogenous, and the splenic capsule is smooth with no irregularities. The blood flow through the hilus and splenic parenchyma appears normal. No focal parenchymal abnormalities are visualized.

Liver

The liver is subjectively normal in size, and echogenicity with smooth peripheral margins. The parenchyma is homogenous echotexture. The visible portions of the vasculature and biliary tract appear normal. No focal nodules or cystic lesions are observed.

The gallbladder lumen is moderately distended. The wall of the gall bladder is not thickened and has a smooth mucosal surface. Luminal contents are mild and primarily anechoic. The cystic duct appears dilated and prominent at 0.54 cm. This can be followed to a tortuous common bile duct, which progressively narrows and is measured more distally at 0.37 cm.

Gastrointestinal

The stomach contains minimal luminal contents. It measures at a normal thickness of <0.36cm with some variability due to the presence of rugal folds. The distinction of the gastric wall layers is adequate and there is no impression of reduced peristaltic activity. No masses or focal lesions were observed.

The visualized areas of duodenum, jejunum and ileum have a relatively uniform diameter with minimal fluid distension. Wall thickness is normal. Bowel loops follow a curvilinear path with distinct wall layering maintaining the typical 1:3 muscularis:mucosa layer ratio. Jejunum wall measures 0.22 cm. Visualized peristalsis appears appropriate. There were no focal lesions consistent with obstruction or a mass effect observed.

The ileocecal junction was visualized and exhibited normal intact wall layering and is subjectively of normal thickness. Sections of colon are visualized with formed fecal material and gas shadowing distally. There is no observed focal or generalized colon wall thickening or loss of layering.

Pancreas

The pancreas is normal and isoechoic to surrounding mesentery. There is no evidence of nodules or cystic lesions. There is no evidence of regional mesenteric inflammation or fluid.

Free Abdomen

Evaluation of the peritoneal cavity did not reveal any evidence of effusion, or subjective lymphadenomegaly. The Medial iliac nodes appear normal and there was no evidence of a caudal aortic thrombus at the bifurcation. The omentum is of normal uniform echogenicity.

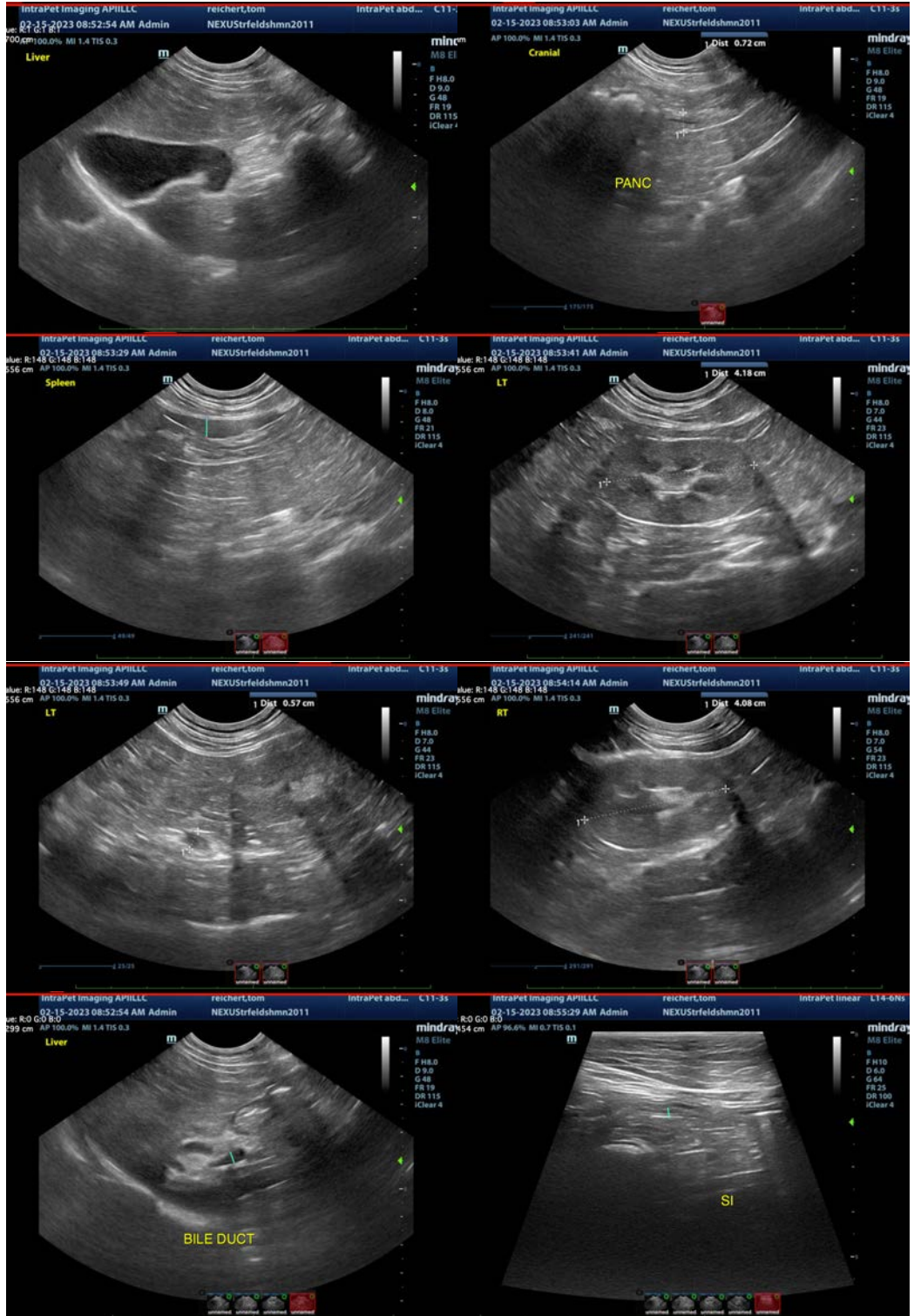
ULTRASONOGRAPHIC FINDINGS

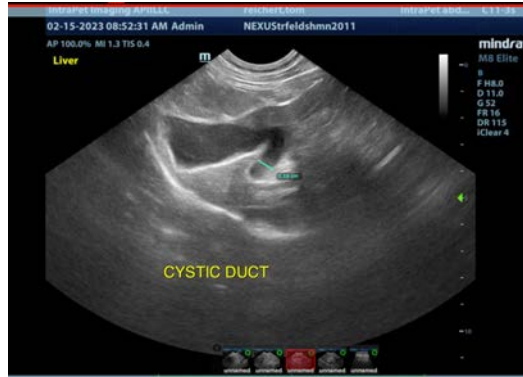- Mildly dilated/tortuous cystic and common bile duct – Dilation of the common bile duct could be consistent with a functional obstruction (i.e. primary hepatic disease resulting in hepatocellular swelling) or with an extrahepatic bile duct obstruction (ie. choledocholith, bile duct tumor, pancreatic disease, other).

INTERPRETATION OF THE FINDINGS & FURTHER RECOMMENDATIONS

Ultrasonographic findings include a mildly dilated/tortuous cystic and common bile duct with no obvious obstruction visualized. No focal mass lesions are observed.

Further diagnostic and therapeutic recommendations regarding this exam to be made by Dr. Cara Steele.





The information and recommendations provided are based on the images presented by the referring veterinarian/sonographer. No evaluation can be communicated regarding pathology that was not visible in the image/video clips provided.

Thank you for this referral. If the clinical or image interpretation does not parallel your findings or if I can be of any further assistance please contact me.

Kathleen Sennello DVM,MS, Diplomate ACVIM (Small animal Internal Medicine)
kathleen.sennello@sonopath.com