



PATIENT PRESENTING CLINICAL SIGNS

Sylvester Roberts

Weight loss low blood glucose consistently, slightly decreased HCT
Abnormal PE/Chem/CBC/UA Results: Hematocrit 29.3%, Glucose 69 LABs attached

SPECIES

Feline

ULTRASONOGRAPHIC EXAMINATION OF THE ABDOMEN

BREED

Urinary System

Scottish Fold

The urinary bladder is moderately distended with anechoic urine. The Bladder wall, trigone, ureteral papillae and visible urethra (to a depth of 2cm) appear normal with no evidence of wall thickening, mucosal irregularities, masses or cystic calculi.

SEX

Neutered Male

The left kidney has a normal shape and size (3.86 cm). Overall echogenicity is normal with adequate corticomedullary distinction and a typical 1:3 cortex:medulla ratio. There is no evidence of focal perinephric inflammation or effusion. There is no evidence of pyelectasia, nephroliths, infarcts or hydroureter. Renal vasculature is normal.

AGE

2013

The right kidney has a normal shape and size (3.22 cm). Overall echogenicity is normal with adequate corticomedullary distinction and a typical 1:3 cortex:medulla ratio. There is no evidence of focal perinephric inflammation or effusion. There is no evidence of pyelectasia, nephroliths, infarcts or hydroureter. Renal vasculature is normal.

WEIGHT

7.4 Pounds

Adrenal Glands

INTERPRETED BY

Kathleen Sennello DVM,
MS, Diplomate ACVIM
(Small Animal Internal
Medicine)

The left adrenal gland is normal in size measuring 0.36 cm at the caudal pole. It is observed in its normal position cranial to the left renal artery. It is normal in appearance (uniformly hypoechoic) and shape with no evidence of a mass effect.

The right adrenal gland is normal in size measuring 0.37 cm at the caudal pole. It is observed in its normal position between the cranial aspect of the right kidney and the caudal vena cava. It is normal in appearance (uniformly hypoechoic) and shape with no evidence of a mass effect.

IMAGING PERFORMED BY

Loetitia Saint-Jacques,
LVT

Spleen

The spleen is subjectively normal in size (0.61 cm), echotexture is homogenous, and the splenic capsule is smooth with no irregularities. The blood flow through the hilus and splenic parenchyma appears normal. No focal are visualized associated with the parenchyma, and the spleen is somewhat folded over upon itself.

HOSPITAL NAME

Sierra Animal Wellness

Liver

The liver is subjectively normal in size, and echogenicity with smooth peripheral margins. The parenchyma is mildly heterogenous in echotexture with subtle, indistinct focal mottling. The visible portions of the vasculature and biliary tract appear normal. No focal nodules or cystic lesions are observed.

REFERRING VET

Dr. Peggy Roberts

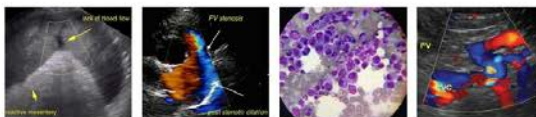
INVOICE

45189

The gallbladder lumen is moderately distended. The wall of the gall bladder is not thickened and has a smooth mucosal surface. Luminal contents are mild and primarily anechoic. The cystic and common bile ducts are normal/not visible.

DATE

2/15/23


PATIENT *Gastrointestinal*

Sylvester Roberts

SPECIES

Feline

BREED

Scottish Fold

SEX

Neutered Male

AGE

2013

WEIGHT

7.4 Pounds

INTERPRETED BY

 Kathleen Sennello DVM,
 MS, Diplomate ACVIM
 (Small Animal Internal
 Medicine)

IMAGING PERFORMED BY

 Loetitia Saint-Jacques,
 LVT

HOSPITAL NAME

Sierra Animal Wellness

REFERRING VET

Dr. Peggy Roberts

INVOICE

45189

DATE

2/15/23

The stomach is moderately dilated with fluid and irregular shadowing material most consistent with normal ingesta and gas. It measures at a normal thickness of <0.36cm with some variability due to the presence of rugal folds. The distinction of the gastric wall layering is adequate and there is no impression of reduced peristaltic activity. No masses or focal lesions were observed.

The visualized areas of duodenum, jejunum and ileum have a relatively uniform diameter with minimal fluid distension. Wall thickness is normal. Bowel loops follow a curvilinear path with distinct wall layering maintaining the typical 1:3 muscularis:mucosa layer ratio. Duodenum wall measures 0.26 cm. Jejunum wall measures 0.16 cm. Visualized peristalsis appears appropriate. There were no focal lesions consistent with obstruction or a mass effect observed.

The ileocecal junction was visualized and exhibited normal intact wall layering and is subjectively of normal thickness. Sections of colon are visualized with formed fecal material and gas shadowing distally. There is no observed focal or generalized colon wall thickening or loss of layering.

Pancreas

The pancreas is prominent and mottled compared to the surrounding isoechoic mesentery. There is no evidence of nodules or cystic lesions. There is no evidence of regional mesenteric inflammation or fluid.

Free Abdomen

Evaluation of the peritoneal cavity did not reveal any evidence of effusion. There are prominent mesenteric lymph nodes measuring 0.44, 0.43, and 0.26 cm. The omentum is of normal echogenicity.

ULTRASONOGRAPHIC FINDINGS

- Prominent, mottled pancreas – The pancreatic changes are most consistent with age-related parenchymal remodeling, potentially secondary to a prior inflammatory episode, early fibrosis or chronic pancreatitis.
- Heterogeneous liver – The diffuse hepatic changes are non-specific and could be consistent with vacuolar hepatopathy, nodular hyperplasia, inflammatory/immune-mediated disease, fibrosis, extramedullary hematopoiesis, toxic hepatopathy (e.g., copper), infiltrative neoplasia (less likely) or other hepatopathy.
- Moderate ingesta and fluid within the gastric lumen – Findings are most consistent with a non-fasted patient.
- Prominent mesenteric lymph nodes – The prominent abdominal lymph nodes are most consistent with reactive lymphadenitis or lymphoid hyperplasia. Neoplastic infiltration is considered less likely.

INTERPRETATION OF THE FINDINGS & FURTHER RECOMMENDATIONS

No overt mass effects or nodules are visualized to explain the hypoglycemia reported. Recommend liver function test and potentially screening for Addison's if clinically appropriate. If the blood glucose can drop below 60 (closer to 40 is ideal), you could consider an insulin to glucose ratio, looking for evidence of an insulinoma. If insulin levels are high, consider a contrast CT scan, as this may be able to pick up smaller, less well defined pancreatic lesions.



PATIENT

Sylvester Roberts

Most of the lesions observed on today's scan are relatively non-specific and could be within normal limits for this individual.

SPECIES

Feline

Recommend three view thoracic radiographs to evaluate for possible concurrent thoracic disease/involvement.

BREED

Scottish Fold

SEX

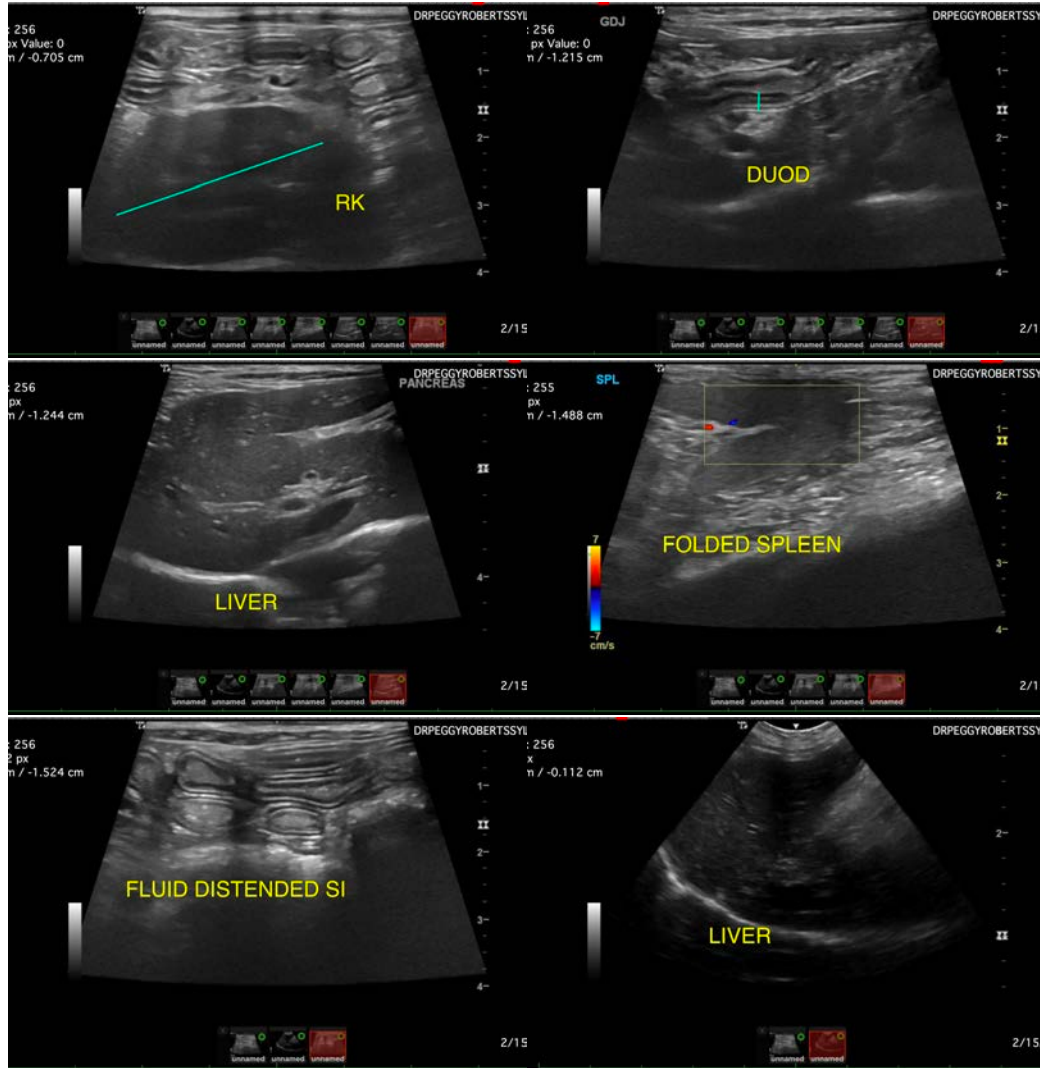
Neutered Male

AGE

2013

WEIGHT

7.4 Pounds



INTERPRETED BY

Kathleen Sennello DVM,
MS, Diplomate ACVIM
(Small Animal Internal
Medicine)

IMAGING PERFORMED BY

Loetitia Saint-Jacques,
LVT

HOSPITAL NAME

Sierra Animal Wellness

REFERRING VET

Dr. Peggy Roberts

INVOICE

45189

DATE

2/15/23



PATIENT

Sylvester Roberts

SPECIES

Feline

BREED

Scottish Fold

SEX

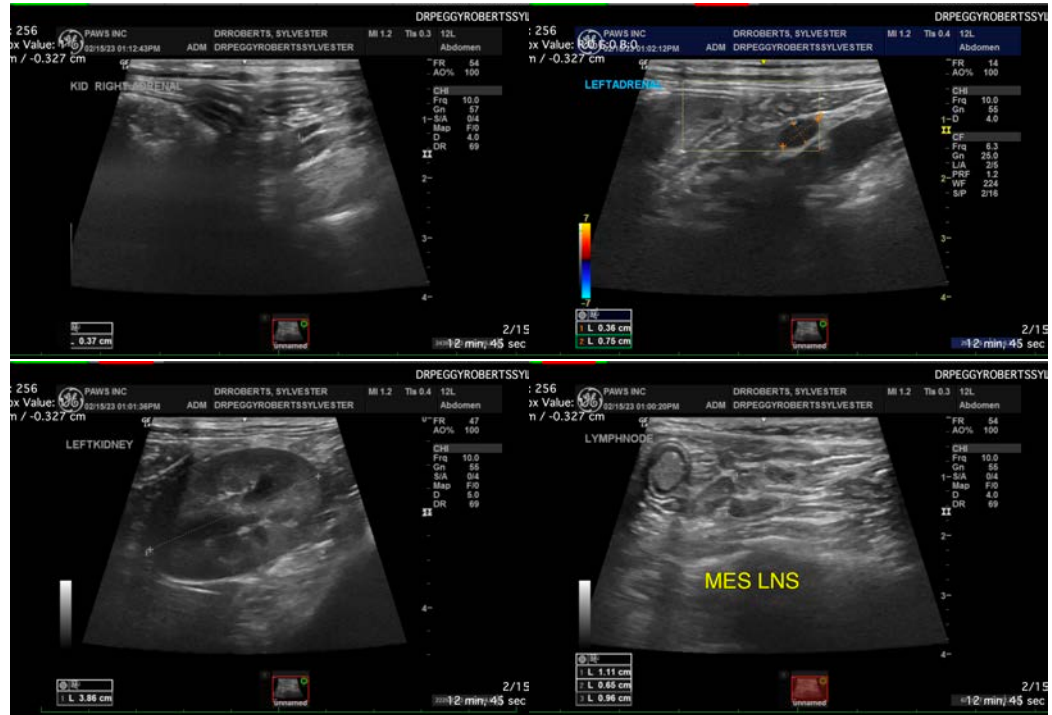
Neutered Male

AGE

2013

WEIGHT

7.4 Pounds



INTERPRETED BY

Kathleen Sennello DVM,
MS, Diplomate ACVIM
(Small Animal Internal
Medicine)

**IMAGING
PERFORMED BY**

Loetitia Saint-Jacques,
LVT

HOSPITAL NAME

Sierra Animal Wellness

REFERRING VET

Dr. Peggy Roberts

INVOICE

45189

DATE

2/15/23

The information and recommendations provided are based on the images presented by the referring veterinarian/sonographer. No evaluation can be communicated regarding pathology that was not visible in the image/video clips provided.

Thank you for this referral. If the clinical or image interpretation does not parallel your findings or if I can be of any further assistance please contact me.

Kathleen Sennello DVM,MS, Diplomate ACVIM (Small animal Internal Medicine)

kathleen.sennello@sonopath.com