



PATIENT

Nacho Flores

SPECIES

Canine

BREED

Beagle

SEX

Neutered Male

AGE

9 Years

WEIGHT

36

INTERPRETED BY

Kathleen Sennello DVM,
MS, Diplomate ACVIM
(Small Animal Internal
Medicine)

IMAGING PERFORMED BY

Dr. Megan Cassels-
Conway

HOSPITAL NAME

Central Broward AH

REFERRING VET

Dr. Janeen Lezcano

INVOICE

45184

DATE

2/15/23

PRESENTING CLINICAL SIGNS

P recently had incident of gastroenteritis of unknown origin. Appears resolved. P has been doing well up to that point. Has hx of hypertension (appears controlled), proteinuria, pancreatitis and splenic nodule. Current medications

Abnormal PE/Chem/CBC/UA Results: Most recent bw (2/6/2023): CBC: WNL; Chem: , glob: 3.7H, ALP: 161H, t bili: 0.4H, choles: 545H, T4: 1.3, UA: SG: 1.013, 2+ prot, quiet sediment UPC prior to dx hypertension was 5.3, has not been repeated since.

ULTRASONOGRAPHIC EXAMINATION OF THE ABDOMEN

Urinary System

The urinary bladder is moderately distended with anechoic urine. The Bladder wall, trigone, ureteral papillae and visible urethra (to a depth of 2cm) appear normal with no evidence of wall thickening, mucosal irregularities, masses or cystic calculi.

The prostate is normal in size (1.06 cm) and shape for this neutered male dog. The parenchyma is homogenous and the external margins are smooth. The prostatic urethra appears normal with no evidence of irregularity, invasion, mass effect or calculi.

The left kidney has a normal shape and size (5.96 cm). Overall echogenicity is normal with adequate corticomedullary distinction and a typical 1:3 cortex:medulla ratio. There is no evidence of focal perinephric inflammation or effusion. There is no evidence of pyelectasia, nephroliths, infarcts or hydroureter. Renal vasculature is normal.

The right kidney has a normal shape and size (5.55 cm). Overall echogenicity is normal with adequate corticomedullary distinction and a typical 1:3 cortex:medulla ratio. There is no evidence of focal perinephric inflammation or effusion. There is no evidence of pyelectasia, nephroliths, infarcts or hydroureter. Renal vasculature is normal.

Adrenal Glands

The left adrenal gland is normal in size measuring 0.73 cm at the caudal pole. It is observed in its normal position cranial to the left renal artery. It is normal in appearance (uniformly hypoechoic) and shape with no evidence of a mass effect.

The right adrenal gland is normal in size measuring 0.86 cm at the caudal pole. It is observed in its normal position between the cranial aspect of the right kidney and the caudal vena cava. It is normal in appearance (uniformly hypoechoic) and shape with no evidence of a mass effect.

Spleen

The spleen is subjectively normal in size but slightly irregular in shape. The blood flow through the hilus and splenic parenchyma appears normal. There is a moderately sized hypoechoic, slightly mottled mass effect towards the tail of the spleen measuring 2.08 cm x 1.48 cm. Additionally, there is a very small irregularity off this lesion measuring 0.43 cm in diameter, which seems to deviate the splenic capsule slightly. This mass appears larger than on the previous scan (9/7/22), when it measured at 1.87 cm x 1.29 cm.



PATIENT

Liver

Nacho Flores

The liver is large in size, and normal in echogenicity with smooth peripheral margins. The parenchyma is heterogenous in echotexture with subtle, indistinct focal mottling. The visible portions of the vasculature and biliary tract appear normal. No focal nodules or cystic lesions are observed.

SPECIES

Canine

The gall bladder lumen is significantly distended. Some areas of the wall appear mildly thickened with adherent debris and some areas have early mucosal stranding and organization of the debris into an early mucocele. There is a large amount of primarily non-organized echogenic debris present as well. There is no evidence of bile duct dilation.

BREED

Beagle

SEX

Neutered Male

The stomach contains minimal luminal contents. It measures at a normal thickness of <0.7cm with some variability due to the presence of rugal folds. The distinction of the gastric wall layers is adequate and there is no impression of reduced peristaltic activity. No masses or focal lesions were observed.

AGE

9 Years

The visualized areas of duodenum, jejunum and ileum have a relatively uniform diameter with minimal fluid distension. Wall thickness is normal. Bowel loops follow a curvilinear path with distinct wall layering maintaining the typical 1:3 muscularis:mucosa layer ratio. Duodenum wall measures 0.47 cm. Jejunum wall measures 0.32 cm. Visualized peristalsis appears appropriate. There were no focal lesions consistent with obstruction or a mass effect observed.

WEIGHT

36

The ileocecal junction was visualized and exhibited normal intact wall layering and is subjectively of normal thickness. Sections of colon are visualized with formed fecal material and gas shadowing distally. There is no observed focal or generalized colon wall thickening or loss of layering.

INTERPRETED BY

Kathleen Sennello DVM,
MS, Diplomate ACVIM
(Small Animal Internal
Medicine)

Pancreas

The pancreas is normal and isoechoic to surrounding mesentery. There is no evidence of nodules or cystic lesions. There is no evidence of regional mesenteric inflammation or fluid.

IMAGING PERFORMED BY

Dr. Megan Cassels-
Conway

Free Abdomen

Evaluation of the peritoneal cavity did not reveal any evidence of effusion, or subjective lymphadenomegaly. The Medial iliac nodes appear normal and there was no evidence of a caudal aortic thrombus at the bifurcation. The omentum is of normal uniform echogenicity.

HOSPITAL NAME

Central Broward AH

ULTRASONOGRAPHIC FINDINGS

REFERRING VET

Dr. Janeen Lezcano

INVOICE

45184

DATE

2/15/23

- Hypoechoic nodule/small mass in the tail of the spleen – There is a non-cavitated, hypoechoic splenic nodule visualized. Differentials include lymphoid hyperplasia, extramedullary hematopoiesis, infiltrative neoplasia, inflammation, other. Cytology or histopathology would be necessary to get a definitive diagnosis. The appearance and size of this lesion appears to be progressing. Recommend fine needle aspirate and splenectomy.
- Heterogeneous liver – The diffuse hepatic changes are non-specific and could be consistent with vacuolar hepatopathy, nodular hyperplasia, inflammatory/immune-mediated disease, fibrosis, extramedullary hematopoiesis, toxic hepatopathy (e.g., copper), infiltrative neoplasia (less likely) or other hepatopathy.
- Gallbladder distended with a large amount of intraluminal material with some early mucosal stranding along the wall of the gallbladder – The gall bladder changes are most consistent with a developing mucocele. Consider medical management and close monitoring for progression of this lesion.



PATIENT

Nacho Flores

SPECIES

Canine

BREED

Beagle

SEX

Neutered Male

AGE

9 Years

WEIGHT

36

INTERPRETED BY

Kathleen Sennello DVM,
MS, Diplomate ACVIM
(Small Animal Internal
Medicine)

IMAGING PERFORMED BY

Dr. Megan Cassels-
Conway

HOSPITAL NAME

Central Broward AH

REFERRING VET

Dr. Janeen Lezcano

INVOICE

45184

DATE

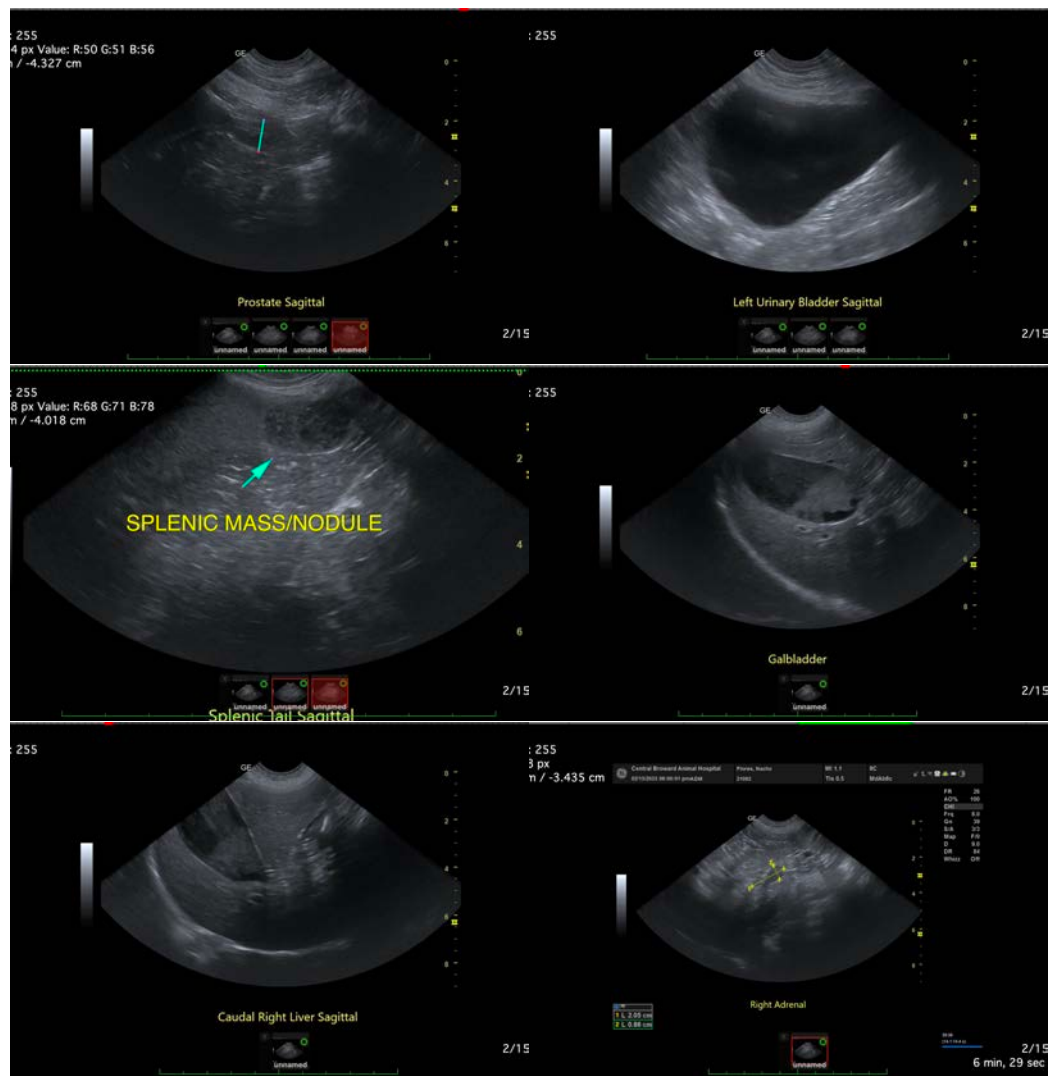
2/15/23

INTERPRETATION OF THE FINDINGS & FURTHER RECOMMENDATIONS

The splenic nodule, which is being followed, continues to enlarge slowly, and today has a slight irregularity towards the cranial aspect and appears to mildly deviate the splenic capsule. While the progression of this lesion is not rapid, it does appear to be progressing. Consider a fine needle aspirate +/- splenectomy.

The liver is somewhat heterogeneous. This is a non-specific finding. Correlate with liver values. A liver function test and fine needle aspirate could be considered. Additionally, the gallbladder changes appear to have progressed slightly with some early organization of the biliary secretions within the gallbladder. Consider starting chronic Ursodiol therapy.

Recommend three view thoracic radiographs to evaluate for possible concurrent thoracic disease/involvement.





PATIENT

Nacho Flores

SPECIES

Canine

BREED

Beagle

SEX

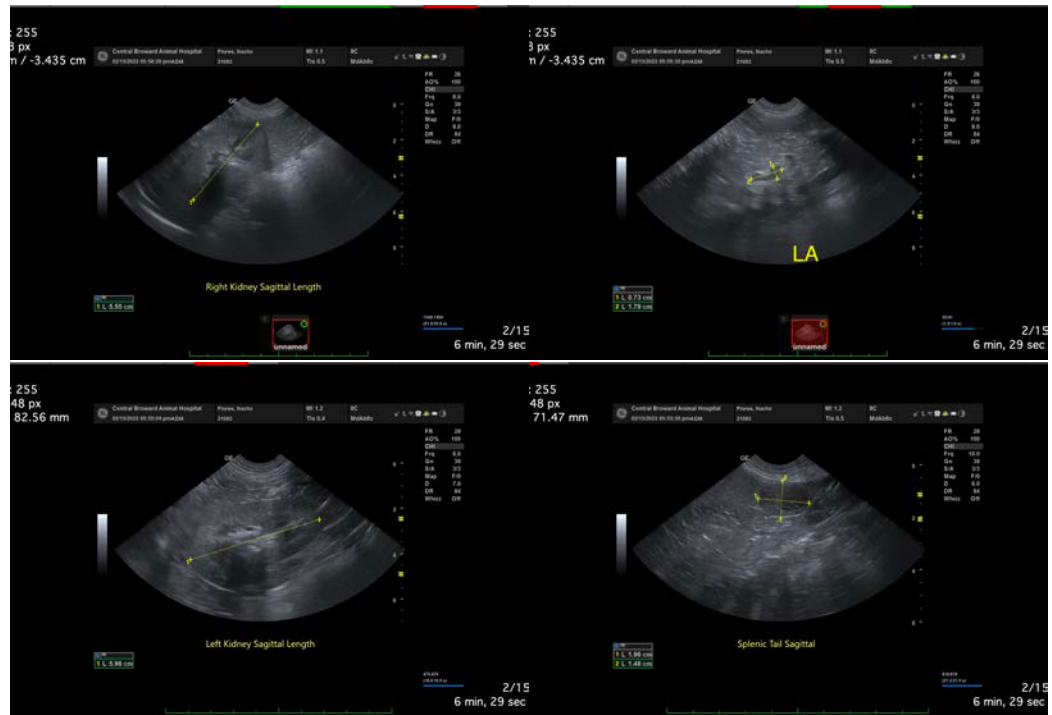
Neutered Male

AGE

9 Years

WEIGHT

36



INTERPRETED BY

Kathleen Sennello DVM, MS, Diplomate ACVIM (Small Animal Internal Medicine)

IMAGING PERFORMED BY

Dr. Megan Cassels-Conway

HOSPITAL NAME

Central Broward AH

REFERRING VET

Dr. Janeen Lezcano

INVOICE

45184

DATE

2/15/23

The information and recommendations provided are based on the images presented by the referring veterinarian/sonographer. No evaluation can be communicated regarding pathology that was not visible in the image/video clips provided.

Thank you for this referral. If the clinical or image interpretation does not parallel your findings or if I can be of any further assistance please contact me.

Kathleen Sennello DVM,MS, Diplomate ACVIM (Small animal Internal Medicine)

kathleen.sennello@sonopath.com