



PATIENT

Abby Origlio

SPECIES

Canine

BREED

Mix

SEX

Spayed Female

AGE

11 years

WEIGHT

31.8 lbs

INTERPRETED BY

Kathleen Sennello
DVM, MS, Diplomate
ACVIM (Small Animal
Internal Medicine)

IMAGING PERFORMED BY

Kelly Vazquez, CVT

HOSPITAL NAME

Ringwood AH

REFERRING VET

Dr. DeSpirito

INVOICE

96083

DATE

2/15/22

PRESENTING CLINICAL SIGNS

Patient presents for weight loss.

Abnormal PE/Chem/CBC/UA Results: SDMA 23, creat. 1.7, BUN 39, ALT 185, AST 66, USG: 1.020.

Total # of Files Uploaded: 43

ULTRASONOGRAPHIC EXAMINATION OF THE ABDOMEN

Urinary System

The urinary bladder is moderately distended with anechoic urine. The Bladder wall, trigone, ureteral papillae and visible urethra (to a depth of 2cm) appear normal with no evidence of wall thickening, mucosal irregularities, masses or cystic calculi.

The left kidney has a normal shape and size (3.63 cm). Overall echogenicity is slightly hyperechoic with poor corticomedullary distinction and a typical 1:3 cortex:medulla ratio. There is no evidence of perinephric inflammation or effusion. There is no evidence of pyelectasia, nephroliths, infarcts or hydroureter. Renal vasculature is normal.

The right kidney has a normal shape and size (4.55 cm). Overall echogenicity is slightly hyperechoic with poor corticomedullary distinction and a typical 1:3 cortex:medulla ratio. There is no evidence of perinephric inflammation or effusion. There is no evidence of pyelectasia, nephroliths, infarcts or hydroureter. Renal vasculature is normal.

Adrenal Glands

The left adrenal gland is borderline normal/borderline large in size measuring 0.83 cm at the caudal pole. It is observed in its normal position cranial to the left renal artery. It is normal in appearance (uniformly hypoechoic) and shape with no evidence of a mass effect.

The right adrenal gland is normal in size measuring 0.75 cm at the caudal pole. It is observed in its normal position between the cranial aspect of the right kidney and the caudal vena cava. It is normal in appearance (uniformly hypoechoic) and shape with no evidence of a mass effect.

Spleen

The spleen is subjectively (normal or large) in size. The spleen echotexture is heterogenous and mottled, the splenic capsule is smooth with no irregularities. The blood flow through the hilus and splenic parenchyma appears normal. There is an ill-defined, hypoechoic nodule that measured 0.86 x 0.67 cm towards the periphery of the splenic parenchyma.

Liver

The liver is subjectively normal in size, and echogenicity with smooth peripheral margins. The parenchyma is homogenous echotexture. The visible portions of the vasculature and biliary tract appear



PATIENT

Abby Origlio

normal. No focal nodules or cystic lesions are observed. The gallbladder lumen is moderately distended. The wall of the gallbladder is not thickened and has a smooth mucosal surface. Luminal contents are primarily anechoic. The cystic and common bile ducts are normal/not visible.

SPECIES

Canine

Gastrointestinal

The stomach contains minimal luminal contents. It measures at a normal thickness of <0.7cm with some variability due to the presence of rugal folds. The distinction of the gastric wall layers is adequate and there is no impression of reduced peristaltic activity. No masses or focal lesions were observed.

BREED

Mix

The visualized areas of duodenum, jejunum and ileum have a relatively uniform diameter with minimal fluid distension. Wall thickness is normal. Bowel loops follow a curvilinear path with distinct wall layering maintaining the typical 1:3 muscularis:mucosa layer ratio. The duodenum measured as normal (between 0.3-0.5cm in wall thickness) and the jejunum measured as normal (between 0.2-0.47cm.)

SEX

Spayed Female

Visualized peristalsis appears appropriate. There were no focal lesions consistent with obstruction or a mass effect observed.

AGE

11 years

The ileocecal junction was visualized and exhibited normal intact wall layering and is subjectively of normal thickness. Sections of colon are visualized with formed fecal material and gas shadowing distally. There is no observed focal or generalized colon wall thickening or loss of layering.

WEIGHT

31.8 lbs

Pancreas

The pancreas is normal and isoechoic to surrounding mesentery. There is no evidence of nodules or cystic lesions. There is no evidence of regional mesenteric inflammation or fluid.

INTERPRETED BY

Kathleen Sennello
DVM, MS, Diplomate
ACVIM (Small Animal
Internal Medicine)

Free Abdomen

Evaluation of the peritoneal cavity did not reveal any evidence of effusion, or subjective lymphadenomegaly. The Medial iliac nodes appear normal and there was no evidence of a caudal aortic thrombus at the bifurcation. The omentum is of normal uniform echogenicity.

IMAGING PERFORMED BY

Kelly Vazquez, CVT

ULTRASONOGRAPHIC FINDINGS

HOSPITAL NAME

Ringwood AH

PRIMARY FINDINGS:

- Decreased corticomedullary distinction in both kidneys. Mild loss of corticomedullary distinction in both kidneys could be consistent with chronic degenerative disease or interstitial nephrosis.
- Mottled spleen with hypoechoic nodule. The diffuse splenic changes are non-specific and could be consistent with lymphoid hyperplasia, extramedullary hematopoiesis, infiltrative neoplasia, inflammation, other. Cytology or histopathology would be necessary to get a definitive diagnosis.

REFERRING VET

Dr. DeSpirito

INVOICE

96083

DATE

2/15/22



PATIENT

Abby Origlio

SPECIES

Canine

BREED

Mix

SEX

Spayed Female

AGE

11 years

WEIGHT

31.8 lbs

INTERPRETED BY

Kathleen Sennello
DVM, MS, Diplomate
ACVIM (Small Animal
Internal Medicine)

IMAGING PERFORMED BY

Kelly Vazquez, CVT

HOSPITAL NAME

Ringwood AH

REFERRING VET

Dr. DeSpirito

INVOICE

96083

DATE

2/15/22

SECONDARY FINDINGS:

- Borderline bilateral adrenomegaly. The bilateral adrenomegaly could be consistent with bilateral hyperplasia (e.g., secondary to pituitary-dependent hyperadrenocorticism), bilateral infiltrative neoplasia, inflammatory adrenal disease, other. Correlation with clinical findings is recommended.

INTERPRETATION OF THE FINDINGS & FURTHER RECOMMENDATIONS

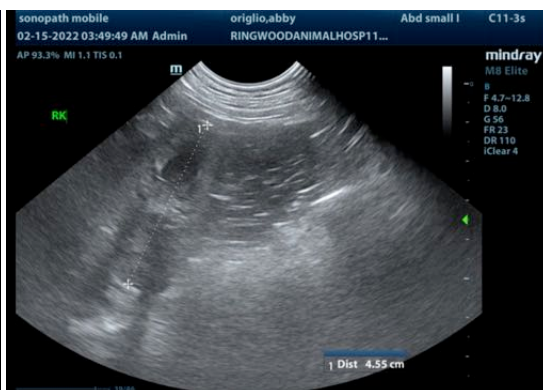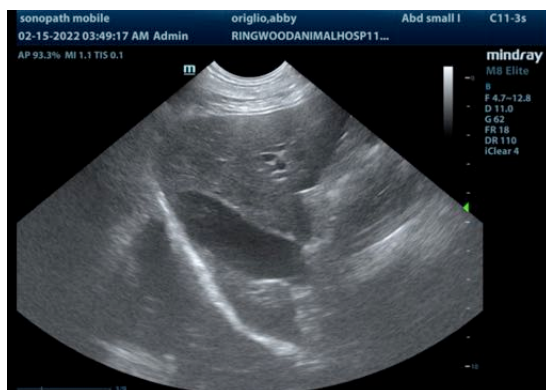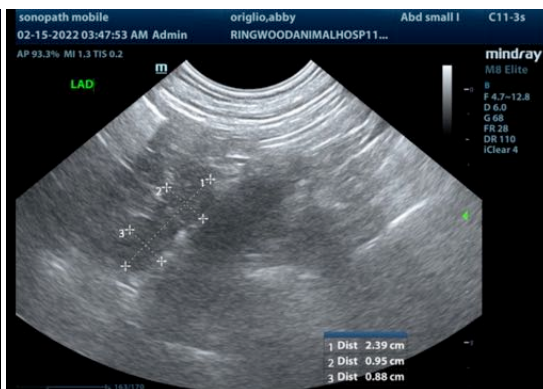
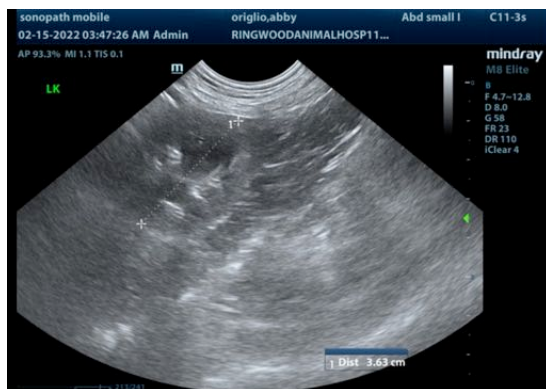
No large, focal mass lesions were observed, but the spleen appears somewhat mottled and there is a small, hypochoic nodule visualized. Consider a FNA of the spleen.

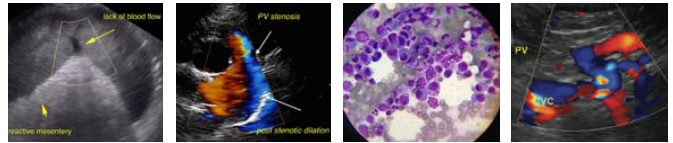
Additionally there are changes observed in the kidneys that are consistent with chronic, progressive renal disease.

- Consider blood pressure evaluation.
- Recommend urinalysis and culture

The adrenal glands are somewhat plump in appearance. I suspect this is an incidental finding as weight loss would be an atypical symptom for Cushing's disease.

Consider three view thoracic radiographs to rule out concurrent thoracic disease/involvement.





PATIENT

Abby Origlio

SPECIES

Canine

BREED

Mix

SEX

Spayed Female

AGE

11 years

WEIGHT

31.8 lbs

INTERPRETED BY

Kathleen Sennello
DVM, MS, Diplomate
ACVIM (Small Animal
Internal Medicine)

**IMAGING
PERFORMED BY**

Kelly Vazquez, CVT

HOSPITAL NAME

Ringwood AH

REFERRING VET

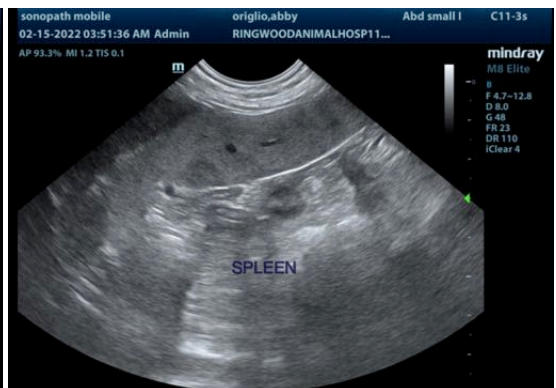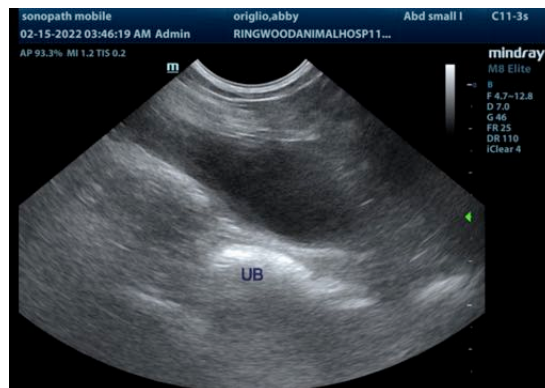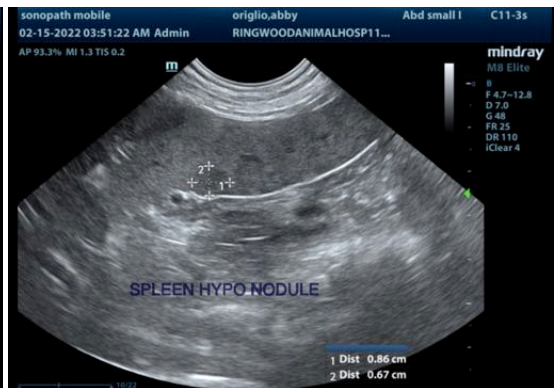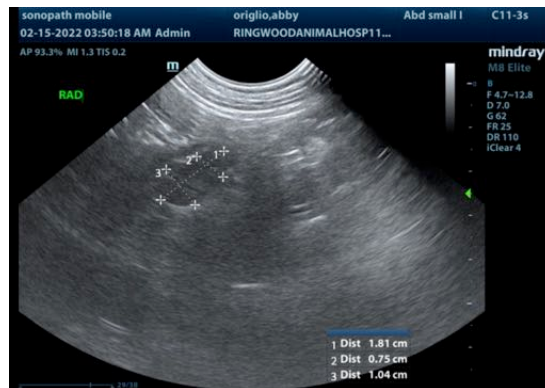
Dr. DeSpirito

INVOICE

96083

DATE

2/15/22



The information and recommendations provided are based on the images presented by the referring veterinarian/sonographer. No evaluation can be communicated regarding pathology that was not visible in the image/video clips provided.

Thank you for this referral. If the clinical or image interpretation does not parallel your findings or if I can be of any further assistance please contact me.

Kathleen Sennello DVM,MS, Diplomate ACVIM (Small animal Internal Medicine)
kathleen.sennello@sonopath.com