



PATIENT

Ollie MacDonald

SPECIES

Canine

BREED

Yorkshire Terrier

SEX

Spayed Female

AGE

8 Years

WEIGHT

7.1 Pounds

INTERPRETED BY

Kathleen Sennello DVM,
MS, Diplomate ACVIM
(Small Animal Internal
Medicine)

IMAGING PERFORMED BY

Diane McFadden

HOSPITAL NAME

Tranquility Vet Clinic

REFERRING VET

Dr. Blackman

INVOICE

45096

DATE

2/14/23

PRESENTING CLINICAL SIGNS

Enlarged spleen on FAST scan; no chronic meds; was on carprofen for 5 days after a fall on her face
Abnormal PE/Chem/CBC/UA Results: Pendine

ULTRASONOGRAPHIC EXAMINATION OF THE ABDOMEN

Urinary System

The urinary bladder is mildly distended with anechoic urine. The Bladder wall, trigone, ureteral papillae and visible urethra (to a depth of 2cm) appear normal with no evidence of wall thickening, mucosal irregularities, masses or cystic calculi. Lack of urine distention somewhat hinders full evaluation of the urinary bladder.

The left kidney has a normal shape and size (3.41 cm). Overall echogenicity is normal with adequate corticomedullary distinction and a typical 1:3 cortex:medulla ratio. There is no evidence of focal perinephric inflammation or effusion. There is no evidence of pyelectasia, nephroliths, infarcts or hydroureter. Renal vasculature is normal.

The right kidney has a normal shape and size (3.3 cm). Overall echogenicity is normal with adequate corticomedullary distinction and a typical 1:3 cortex:medulla ratio. There is no evidence of focal perinephric inflammation or effusion. There is no evidence of pyelectasia, nephroliths, infarcts or hydroureter. Renal vasculature is normal.

Adrenal Glands

The left adrenal gland is normal in size measuring 0.39 cm at the caudal pole. It is observed in its normal position cranial to the left renal artery. It is normal in appearance (uniformly hypoechoic) and shape with no evidence of a mass effect.

The right adrenal gland is normal in size measuring 0.52 cm at the caudal pole. It is observed in its normal position between the cranial aspect of the right kidney and the caudal vena cava. It is normal in appearance (uniformly hypoechoic) and shape with no evidence of a mass effect.

Spleen

The spleen is normal/borderline large in size, echotexture is homogenous, and the splenic capsule is smooth with no irregularities. The vasculature appears slightly prominent/congested. No focal parenchymal abnormalities are visualized.

Liver

The liver is subjectively normal in size, and echogenicity with smooth peripheral margins. The parenchyma is homogenous echotexture. The visible portions of the vasculature and biliary tract appear normal. No focal nodules or cystic lesions are observed.

The gallbladder lumen is moderately distended. The wall of the gall bladder is not thickened and has a smooth mucosal surface. Luminal contents are mild and primarily anechoic. The cystic and common bile ducts are normal/not visible.

Gastrointestinal

The stomach contains minimal luminal contents. It measures at a normal thickness of <0.7cm with some variability due to the presence of rugal folds. The distinction of the gastric wall layers is adequate and there is no impression of reduced peristaltic activity. No masses or focal lesions were observed.



PATIENT

Ollie MacDonald

SPECIES

Canine

BREED

Yorkshire Terrier

SEX

Spayed Female

AGE

8 Years

WEIGHT

7.1 Pounds

INTERPRETED BY

Kathleen Sennello DVM,
MS, Diplomate ACVIM
(Small Animal Internal
Medicine)

IMAGING PERFORMED BY

Diane McFadden

HOSPITAL NAME

Tranquility Vet Clinic

REFERRING VET

Dr. Blackman

INVOICE

45096

DATE

2/14/23

The visualized areas of duodenum, jejunum and ileum have a relatively uniform diameter with minimal fluid distension. Wall thickness is normal. Bowel loops follow a curvilinear path with distinct wall layering maintaining the typical 1:3 muscularis:mucosa layer ratio. Jejunum wall measures 0.32 cm. Duodenum wall measures 0.38 cm. Visualized peristalsis appears appropriate. There were no focal lesions consistent with obstruction or a mass effect observed.

The ileocecal junction was visualized and exhibited normal intact wall layering and is subjectively of normal thickness. Sections of colon are visualized with formed fecal material and gas shadowing distally. There is no observed focal or generalized colon wall thickening or loss of layering.

Pancreas

The pancreas is normal and isoechoic to surrounding mesentery. There is no evidence of nodules or cystic lesions. There is no evidence of regional mesenteric inflammation or fluid.

Free Abdomen

Evaluation of the peritoneal cavity did not reveal any evidence of effusion, or subjective lymphadenomegaly. The Medial iliac nodes appear normal and there was no evidence of a caudal aortic thrombus at the bifurcation. The omentum is of normal uniform echogenicity.

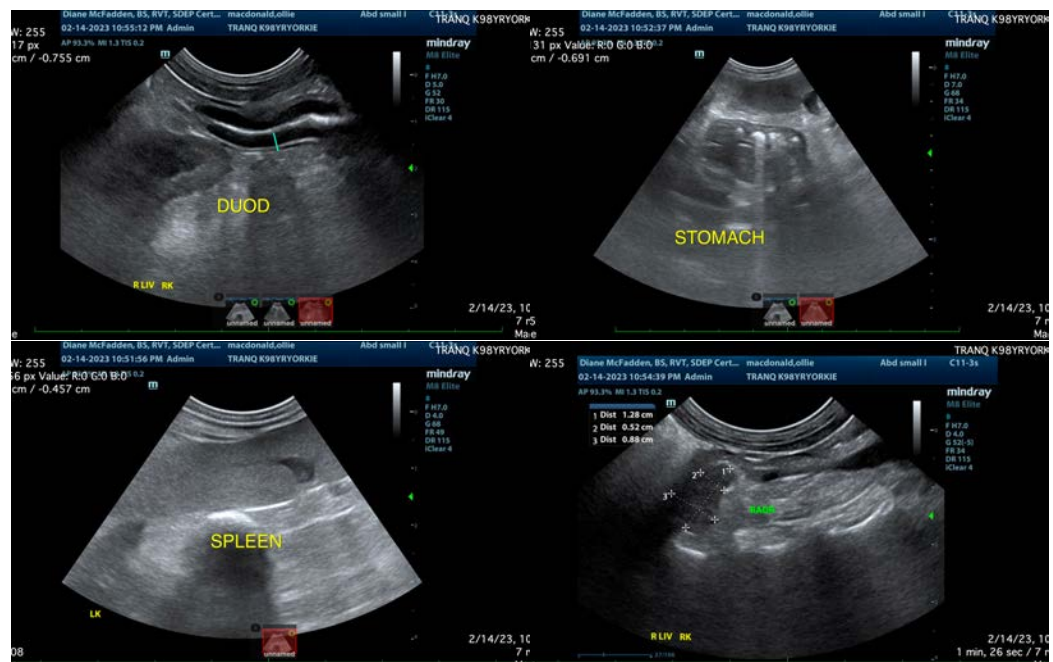
ULTRASONOGRAPHIC FINDINGS

- Subjectively mildly enlarged spleen with prominent vasculature – This could be normal for this individual or could represent congestion, less likely infiltration.

INTERPRETATION OF THE FINDINGS & FURTHER RECOMMENDATIONS

Correlate the splenic findings with abdominal radiographs and the symptoms exhibited by the patient. If splenic enlargement is strongly suspected, consider the possibility of cardiac disease, less likely infiltrative disease, portal hypertension, sedation, etc. Correlate with bloodwork findings.

Recommend three view thoracic radiographs to evaluate for possible concurrent thoracic disease/involvement.





PATIENT

Ollie MacDonald

SPECIES

Canine

BREED

Yorkshire Terrier

SEX

Spayed Female

AGE

8 Years

WEIGHT

7.1 Pounds

INTERPRETED BY

Kathleen Sennello DVM,
MS, Diplomate ACVIM
(Small Animal Internal
Medicine)

**IMAGING
PERFORMED BY**

Diane McFadden

HOSPITAL NAME

Tranquility Vet Clinic

REFERRING VET

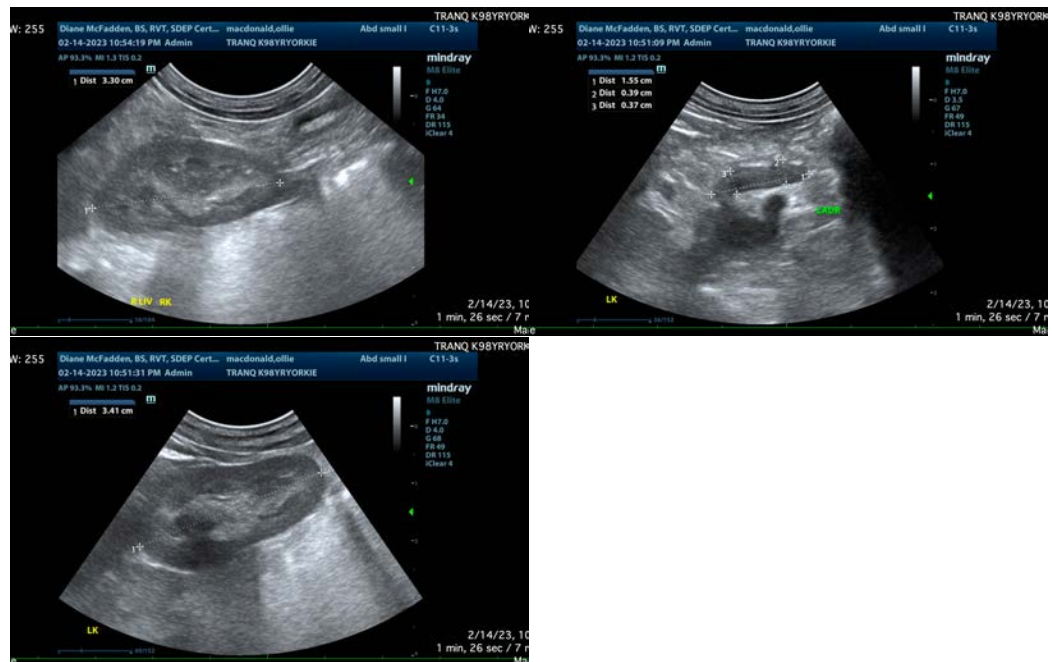
Dr. Blackman

INVOICE

45096

DATE

2/14/23



The information and recommendations provided are based on the images presented by the referring veterinarian/sonographer. No evaluation can be communicated regarding pathology that was not visible in the image/video clips provided.

Thank you for this referral. If the clinical or image interpretation does not parallel your findings or if I can be of any further assistance please contact me.

Kathleen Sennello DVM,MS, Diplomate ACVIM (Small animal Internal Medicine)

kathleen.sennello@sonopath.com