

**DATE PRESENTING CLINICAL SIGNS**

2/14/23 Lethargic, not eating well, sneezing. Ear, teeth and respiratory infections. Upon abdominal examination felt a mass vs large kidney on the left side.

**PATIENT**

Little Bit Simth

Current Medications: 15 Enrofloxacin 22.5mg give ¾ BID, Tresaderm 15ml- 5 drops @ ear BID.

Date of Previous IntraPet Ultrasound: No previous.

Sedation: Not required to complete full diagnostic ultrasound.

Stat Report: Not requested.

Imaging Performed By: Rachel Brillhart, RDMS.

**SPECIES**

Feline

**ULTRASONOGRAPHIC EXAMINATION OF THE ABDOMEN****BREED**

DLH

**Urinary System**

The urinary bladder is minimally distended with urine, making evaluation of the bladder wall anatomy very difficult/impossible. Recommend reevaluation with a full bladder.

**SEX**

Spayed Female

The left kidney is large, measuring 4.13 cm, and severely hydronephrotic, dilated with mildly echogenic fluid and minimal visible cortex. The proximal ureter is distended and dilated, consistent with a hydroureter. This can be followed down to the mid/caudal abdomen. No obvious mass lesions or stones are visualized, but the urinary bladder cannot be fully evaluated due to lack of urine distention.

**AGE**

4/12/17

The right kidney has a normal shape and size (4.6 cm). Overall echogenicity is slightly hyperechoic with poor corticomedullary distinction and a typical 1:3 cortex:medulla ratio. There is no evidence of focal perinephric inflammation or effusion. There is no evidence of pyelectasia, nephroliths, infarcts or hydroureter. Renal vasculature is normal.

**WEIGHT**

8.4 Pounds

**Adrenal Glands**

The region of left adrenal (Cranial to left renal artery) is unremarkable but the adrenal is not distinctly visualized. No evidence of a mass effect is visualized.

The right adrenal gland is normal in size measuring 0.43 cm at the caudal pole. It is observed in its normal position between the cranial aspect of the right kidney and the caudal vena cava. It is normal in appearance (uniformly hypoechoic) and shape with no evidence of a mass effect.

**INTERPRETED BY**

Kathleen Sennello DVM,  
MS, Diplomate ACVIM  
(Small Animal Internal  
Medicine)

**HOSPITAL NAME**

Forest Hill Vet

**Spleen**

The spleen is subjectively normal in size (0.70 cm), echotexture is homogenous, and the splenic capsule is smooth with no irregularities. The blood flow through the hilus and splenic parenchyma appears normal. No focal parenchymal abnormalities are visualized.

**REFERRING VET**

Dr. Saad

**Liver**

The liver is subjectively normal in size, and echogenicity with smooth peripheral margins. The parenchyma is homogenous echotexture. The visible portions of the vasculature and biliary tract appear normal. No focal nodules or cystic lesions are observed.

**INVOICE**

45107

The gallbladder lumen is moderately distended. The wall of the gall bladder is not thickened and has a smooth mucosal surface. Luminal contents are mild and primarily anechoic. The cystic and common bile ducts are normal/not visible.

**Gastrointestinal**

The stomach contains minimal luminal contents. It measures at a normal thickness of <0.36cm with some variability due to the presence of rugal folds. The distinction of the gastric wall layers is adequate and there is no impression of reduced peristaltic activity. No masses or focal lesions were observed.

The visualized areas of duodenum, jejunum and ileum have a relatively uniform diameter with minimal fluid distension. Wall thickness is normal. Bowel loops follow a curvilinear path with distinct wall layering maintaining the typical 1:3 muscularis:mucosa layer ratio. Jejunum wall measures 0.20 cm. Visualized peristalsis appears appropriate. There were no focal lesions consistent with obstruction or a mass effect observed.

The ileocecal junction was visualized and exhibited normal intact wall layering and is subjectively of normal thickness. Sections of colon are visualized with formed fecal material and gas shadowing distally. There is no observed focal or generalized colon wall thickening or loss of layering.

### ***Pancreas***

The pancreas is normal and isoechoic to surrounding mesentery. There is no evidence of nodules or cystic lesions. There is no evidence of regional mesenteric inflammation or fluid.

### ***Free Abdomen***

Evaluation of the peritoneal cavity did not reveal any evidence of effusion, or subjective lymphadenomegaly. The Medial iliac nodes appear normal and there was no evidence of a caudal aortic thrombus at the bifurcation. The omentum is of normal uniform echogenicity.

## **ULTRASONOGRAPHIC FINDINGS**

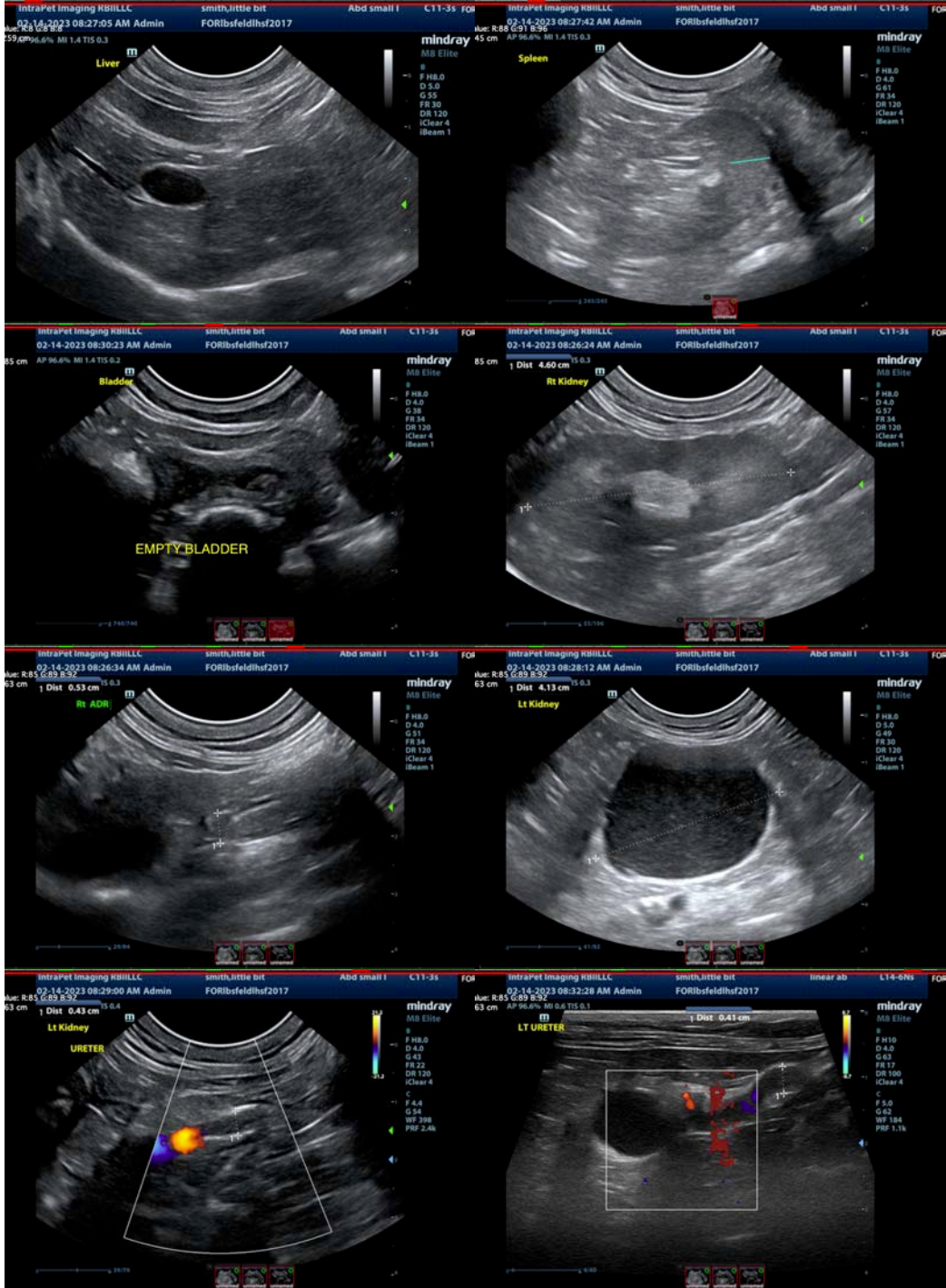
- Large hydronephrotic left kidney with hydroureter – An obvious point of obstruction is not visualized but is likely distal. Consider such differentials as a stricture, stone, mass effect, etc.
- Decreased corticomedullary distinction in the right kidney – Mild loss of corticomedullary distinction in both kidneys could be consistent with chronic degenerative disease or interstitial nephrosis.
- Empty urinary bladder – This is likely secondary to recent voiding. Recommend reevaluation with a full urinary bladder.

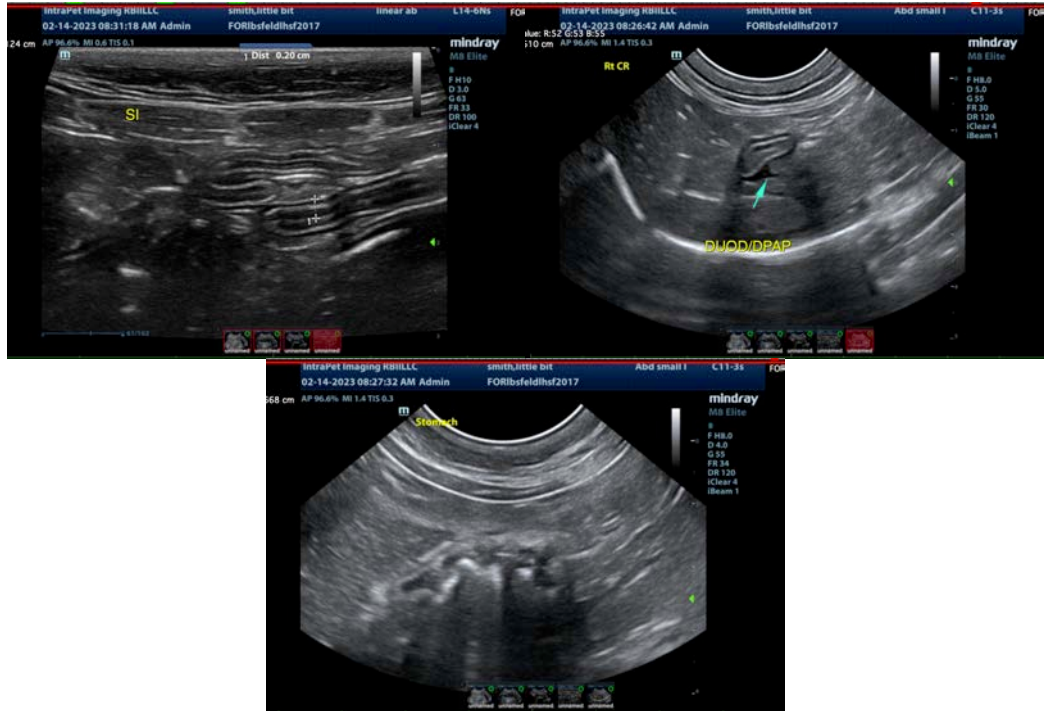
## **INTERPRETATION OF THE FINDINGS & FURTHER RECOMMENDATIONS**

The left kidney is severely hydronephrotic with minimal visible cortical tissue, and additionally there is hydroureter extending into the caudal abdomen. An obvious point of obstruction is not visualized, but the urinary bladder cannot be fully evaluated due to lack of urinary distention. Correlate these findings with current bloodwork, a urinalysis and culture. Consider such differentials as a ureteral stricture, stone, mass, etc. It is likely that nephrectomy will be necessary, and the possibility of an infected kidney based on the echogenic material in the fluid, but ideally you would like to confirm that the right kidney is adequately functioning, producing urine, etc.

Options moving forward include a contrast study (IVP) provided the patient is well hydrated and producing urine to see if this might outline where the obstruction is located. Alternately, you could consider a contrast CT scan or referral to a veterinary surgeon for nephrectomy, provided the patient is not overtly azotemic, appears to be producing urine, etc. (ideally concentrated urine).

Recommend three view thoracic radiographs to evaluate for possible concurrent thoracic disease/involvement. Additionally, recommend abdominal radiographs, looking for any mineral opacities.





The information and recommendations provided are based on the images presented by the referring veterinarian/sonographer. No evaluation can be communicated regarding pathology that was not visible in the image/video clips provided.

Thank you for this referral. If the clinical or image interpretation does not parallel your findings or if I can be of any further assistance please contact me.

Kathleen Sennello DVM,MS, Diplomate ACVIM (Small animal Internal Medicine)  
kathleen.sennello@sonopath.com