



PATIENT PRESENTING CLINICAL SIGNS

Vic Swank
 PU/PD
 PE: WNL CBC/CHEM : mild neutropenia; Rest is wnl U/A: USG - 1023 (after withholding water overnight) Rest is wnl UCCR: 15 Urine culture is pending.

SPECIES

Canine

ULTRASONOGRAPHIC EXAMINATION OF THE ABDOMEN

BREED

Retriever Mix

Urinary System

The urinary bladder is moderately distended with anechoic urine. The Bladder wall, trigone, ureteral papillae and visible urethra (to a depth of 2cm) appear normal with no evidence of wall thickening, mucosal irregularities, masses or cystic calculi.

SEX

Neutered male

The prostate is normal in size (1.3 cm) and shape for this neutered male dog. The parenchyma is homogenous and the external margins are smooth. The prostatic urethra appears normal with no evidence of irregularity, invasion, mass effect or calculi.

AGE

7 years

The left kidney has a normal shape and size (6.7 cm). Overall echogenicity is normal with adequate corticomedullary distinction and a typical 1:3 cortex:medulla ratio. There is no evidence of perinephric inflammation or effusion. There is no evidence of pyelectasia, nephroliths, infarcts or hydroureter. Renal vasculature is normal.

WEIGHT

72 lbs

The right kidney has a normal shape and size (7.0 cm). Overall echogenicity is normal with adequate corticomedullary distinction and a typical 1:3 cortex:medulla ratio. There is no evidence of perinephric inflammation or effusion. There is no evidence of pyelectasia, nephroliths, infarcts or hydroureter. Renal vasculature is normal.

INTERPRETED BY

Kathleen Sennello
 DVM, MS, Diplomate
 ACVIM (Small Animal
 Internal Medicine)

Adrenal Glands

The left adrenal gland is normal in size measuring 0.45 cm at the caudal pole It is observed in its normal position cranial to the left renal artery. It is normal in appearance (uniformly hypoechoic) and shape with no evidence of a mass effect.

IMAGING PERFORMED BY

Dr. Cerf

The right adrenal gland is normal in size measuring 0.62 cm at the caudal pole It is observed in its normal position between the cranial aspect of the right kidney and the caudal vena cava. It is normal in appearance (uniformly hypoechoic) and shape with no evidence of a mass effect.

HOSPITAL NAME

Veterinary Center of
 Hardyston

Spleen

The spleen is subjectively normal in size, echotexture is homogenous, and the splenic capsule is smooth with no irregularities. The blood flow through the hilus and splenic parenchyma appears normal. No focal parenchymal abnormalities are visualized.

REFERRING VET

Dr. Cerf

Liver

The liver is subjectively normal in size, and echogenicity with smooth peripheral margins. The parenchyma is homogenous echotexture. The visible portions of the vasculature and biliary tract appear normal. No focal nodules or cystic lesions are observed. The gallbladder lumen is moderately distended.

INVOICE

96041

DATE

2/9/22



PATIENT

Vic Swank

The wall of the gallbladder is not thickened and has a smooth mucosal surface. There is a moderate amount of non-organized echogenic debris. The cystic and common bile ducts are normal/not visible.

SPECIES

Canine

Gastrointestinal

The stomach contains minimal luminal contents. It measures at a normal thickness of <0.7cm with some variability due to the presence of rugal folds. The distinction of the gastric wall layers is adequate and there is no impression of reduced peristaltic activity. No masses or focal lesions were observed.

BREED

Retriever Mix

The visualized areas of duodenum, jejunum and ileum have a relatively uniform diameter with minimal fluid distension. Wall thickness is normal. Bowel loops follow a curvilinear path with distinct wall layering maintaining the typical 1:3 muscularis:mucosa layer ratio. The duodenum measured as normal and the jejunum measured as normal (0.37 cm). Visualized peristalsis appears appropriate. There were no focal lesions consistent with obstruction or a mass effect observed.

SEX

Neutered male

The ileocecal junction was visualized and exhibited normal intact wall layering and is subjectively of normal thickness. Sections of colon are visualized with formed fecal material and gas shadowing distally. There is no observed focal or generalized colon wall thickening or loss of layering.

AGE

7 years

Pancreas

WEIGHT

72 lbs

The pancreas is normal and isoechoic to surrounding mesentery. There is no evidence of nodules or cystic lesions. There is no evidence of regional mesenteric inflammation or fluid.

INTERPRETED BY

Kathleen Sennello
DVM, MS, Diplomate
ACVIM (Small Animal
Internal Medicine)

Free Abdomen

Evaluation of the peritoneal cavity did not reveal any evidence of effusion, or subjective lymphadenomegaly. The Medial iliac nodes appear normal and there was no evidence of a caudal aortic thrombus at the bifurcation. The omentum is of normal uniform echogenicity.

IMAGING PERFORMED BY

Dr. Cerf

ULTRASONOGRAPHIC FINDINGS

PRIMARY FINDINGS:

- Moderate gallbladder sludge. The significance of the aggregated gallbladder debris is unclear. This could represent an early mucocele, cholestasis, or may be secondary to fasting.

HOSPITAL NAME

Veterinary Center of
Hardyston

INTERPRETATION OF THE FINDINGS & FURTHER RECOMMENDATIONS

REFERRING VET

Dr. Cerf

An obvious lesion responsible for the reported increase in thirst and urination was not visualized. Some issues such as early renal disease, Cushing's disease, behavioral, neurologic, dietary, electrolyte disturbances etc.. are not able to be diagnosed with ultrasound alone. These can be challenging cases. The top 10 differentials can be ruled in/out with routine bloodwork, urinalysis and culture, several more can be evaluated with a good history and imaging. Unfortunately, as you work your way down the list the differentials become harder to definitively diagnose. This is the differential list I start with.

INVOICE

96041

DATE

2/9/22



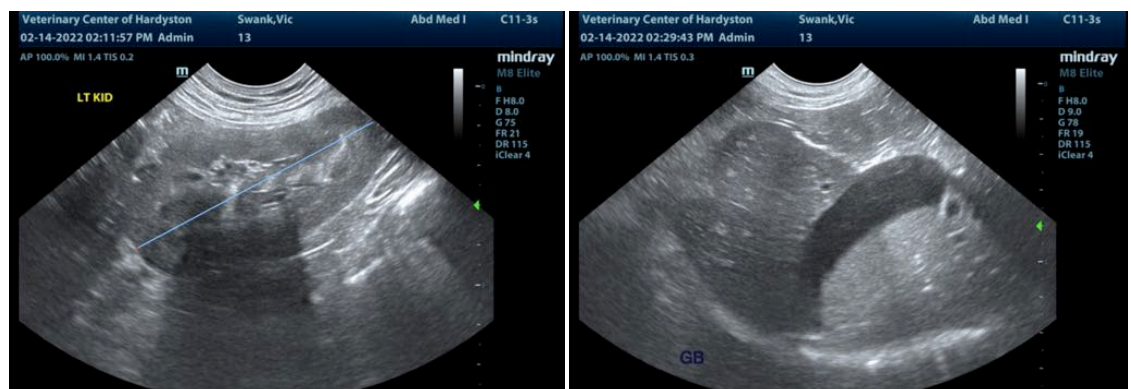
PATIENT	Diabetes Mellitus
Vic Swank	Chronic Renal Disease/Renal Failure (can present pre-azotemic, especially in dogs, but expect the BUN & creatinine not to be at the low end of the reference range) Hypercalcemia
SPECIES	Urinary tract infection
Canine	Iatrogenic Disease due to medications (diuretics, phenobarbital, KBr; diets either high in salt [such as S/D] or very low in protein (such as U/D))
BREED	Hyperthyroidism
Retriever Mix	Hypokalemia
SEX	Liver Disease (hepatic encephalopathy may be a mixed primary PU and PD) Pyelonephritis
Neutered male	Polycythemia
AGE	Renal Tubular Diseases (glycosuria or Fanconi & Fanconi-like syndromes or RTA) Hyperadrenocorticism (may be a mixed primary PU and PD) Hypoadrenocorticism (either Addison's or hypocortisolism) Paraneoplastic Syndromes (particularly splenic hemangiosarcoma?) Pericardial Effusion
7 years	Pyometra (including stump pyometra in spayed dogs) Chronic Partial Urinary Obstruction or Post-Obstructive Diuresis Pheochromocytoma Psychogenic Polydipsia (as in a true behavior disorder with a compulsive element)
WEIGHT	Primary Non-Medical Polydipsia (aka "I drink a lot because I like it or I engage in activities that promote it, but that doesn't mean I'm sick")
72 lbs	Primary Nephrogenic Diabetes Insipidus (Congenital Nephrogenic Diabetes Insipidus, other diseases that cause primary PU other than Congenital Diabetes Insipidus would be considered Acquired Nephrogenic Diabetes Insipidus) Atypical Cushing's and SARDS Central Diabetes Insipidus
INTERPRETED BY	
Kathleen Sennello DVM, MS, Diplomate ACVIM (Small Animal Internal Medicine)	
IMAGING PERFORMED BY	
Dr. Cerf	I would start by evaluating the urine culture you submitted, confirming you have normal calcium level, consider a liver function test +/- testing for Leptospirosis and three view thoracic radiographs and then work through the list of differentials from there.

HOSPITAL NAME
Veterinary Center of
Hardyston

REFERRING VET
Dr. Cerf

INVOICE
96041

DATE
2/9/22





PATIENT

Vic Swank

SPECIES

Canine

BREED

Retriever Mix

SEX

Neutered male

AGE

7 years

WEIGHT

72 lbs

INTERPRETED BY

Kathleen Sennello
DVM, MS, Diplomate
ACVIM (Small Animal
Internal Medicine)

IMAGING PERFORMED BY

Dr. Cerf

HOSPITAL NAME

Veterinary Center of
Hardyston

REFERRING VET

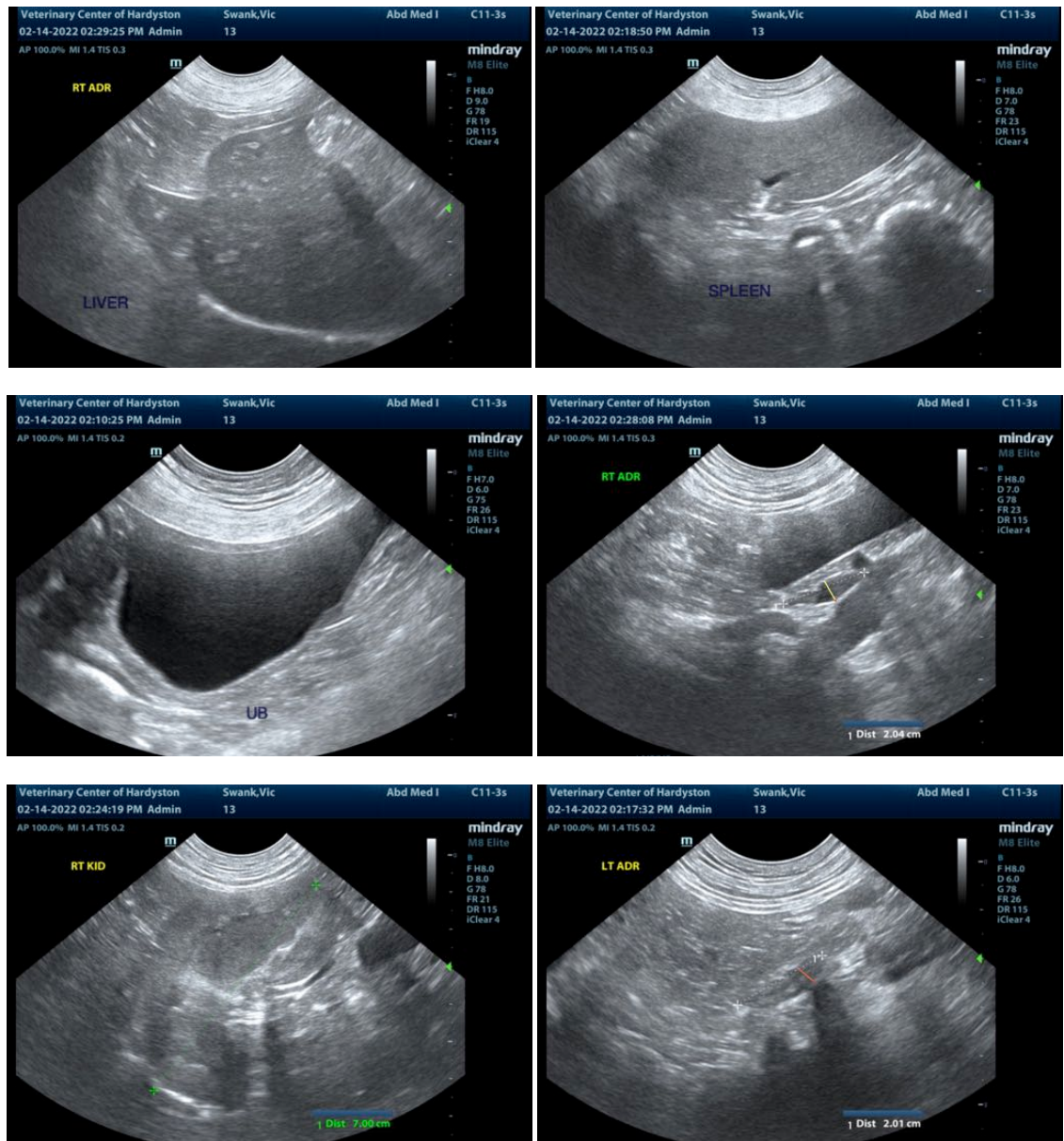
Dr. Cerf

INVOICE

96041

DATE

2/9/22



The information and recommendations provided are based on the images presented by the referring veterinarian/sonographer. No evaluation can be communicated regarding pathology that was not visible in the image/video clips provided.

Thank you for this referral. If the clinical or image interpretation does not parallel your findings or if I can be of any further assistance please contact me.

Kathleen Sennello DVM,MS, Diplomate ACVIM (Small animal Internal Medicine)
kathleen.sennello@sonopath.com