



PATIENT

Nicki Dohm

PRESENTING CLINICAL SIGNS

History of increasing liver Values. DDX: cushings, infection, neoplasia, cholestasis
Abnormal PE/Chem/CBC/UA Results: HEM ALT 415 (10-125) (Prev 295) ALP 274 (23-212) (Prev 210) AUS

SPECIES

Canine

BREED

Australian Red Heeler

SEX

Spayed Female

AGE

11 years

WEIGHT

20.7 kg

INTERPRETED BY

Kathleen Sennello
DVM, MS, Diplomate
ACVIM (Small Animal
Internal Medicine)

IMAGING PERFORMED BY

Dr. Barnes

HOSPITAL NAME

Westview VH

REFERRING VET

Dr. Barnes

INVOICE

96044

DATE

2/14/22

ULTRASONOGRAPHIC EXAMINATION OF THE ABDOMEN

Urinary System

The urinary bladder is moderately distended with anechoic urine. The Bladder wall, trigone, ureteral papillae and visible urethra (to a depth of 2cm) appear normal with no evidence of wall thickening, mucosal irregularities, masses or cystic calculi.

The left kidney has a normal shape and size (6.51 cm). Overall echogenicity is normal with adequate corticomedullary distinction and a typical 1:3 cortex:medulla ratio. There is no evidence of perinephric inflammation or effusion. There is no evidence of pyelectasia, nephroliths, infarcts or hydroureter. Renal vasculature is normal.

The right kidney has a normal shape and size (6.5 cm). Overall echogenicity is normal with adequate corticomedullary distinction and a typical 1:3 cortex:medulla ratio. There is no evidence of perinephric inflammation or effusion. There is no evidence of pyelectasia, nephroliths, infarcts or hydroureter. Renal vasculature is normal.

Adrenal Glands

The left adrenal gland is normal in size measuring 0.69 cm at the caudal pole It is observed in its normal position cranial to the left renal artery. It is normal in appearance (uniformly hypoechoic) and shape with no evidence of a mass effect.

The right adrenal gland is normal in size measuring 0.54 cm at the caudal pole It is observed in its normal position between the cranial aspect of the right kidney and the caudal vena cava. It is normal in appearance (uniformly hypoechoic) and shape with no evidence of a mass effect.

Spleen

The spleen is subjectively normal in size, echotexture is homogenous, and the splenic capsule is smooth with no irregularities. The blood flow through the hilus and splenic parenchyma appears normal. No focal parenchymal abnormalities are visualized.

Liver

The liver is subjectively large in size, and echogenicity with smooth peripheral margins. The parenchyma is heterogenous in echotexture with subtle, indistinct focal mottling. The visible portions of the vasculature and biliary tract appear normal. No focal nodules or cystic lesions are observed. The gallbladder lumen is moderately distended. The wall of the gallbladder is not thickened and has a



PATIENT

Nicki Dohm

smooth mucosal surface. Luminal contents consist primarily of a small to moderate amount of hyperechoic shadowing material that is most consistent with a small amount of mineralized intraluminal. The cystic and common bile ducts are normal/not visible.

SPECIES

Canine

Gastrointestinal

The stomach is moderately dilated with fluid and irregular shadowing material most consistent with normal ingesta and gas. It measures at a normal thickness of <0.7cm with some variability due to the presence of rugal folds. The distinction of the gastric wall layering is adequate and there is no impression of reduced peristaltic activity. No masses or focal lesions were observed.

BREED

Australian Red Heeler

The visualized areas of duodenum, jejunum and ileum have a relatively uniform diameter with minimal fluid distension. Wall thickness is normal. Bowel loops follow a curvilinear path with distinct wall layering maintaining the typical 1:3 muscularis:mucosa layer ratio. The duodenum measured as normal and the jejunum measured as normal (0.35 cm). Visualized peristalsis appears appropriate. There were no focal lesions consistent with obstruction or a mass effect observed.

SEX

Spayed Female

The ileocecal junction was visualized and exhibited normal intact wall layering and is subjectively of normal thickness. Sections of colon are visualized with formed fecal material and gas shadowing distally. There is no observed focal or generalized colon wall thickening or loss of layering.

AGE

11 years

WEIGHT

20.7 kg

Pancreas

The region of the pancreas is normal and isoechoic to surrounding mesentery. There is no evidence of nodules or cystic lesions. There is no evidence of regional mesenteric inflammation or fluid.

INTERPRETED BY

Kathleen Sennello
DVM, MS, Diplomate
ACVIM (Small Animal
Internal Medicine)

Free Abdomen

Evaluation of the peritoneal cavity did not reveal any evidence of effusion, or subjective lymphadenomegaly. The Medial iliac nodes appear normal and there was no evidence of a caudal aortic thrombus at the bifurcation. The omentum is of normal uniform echogenicity.

IMAGING PERFORMED BY

Dr. Barnes

ULTRASONOGRAPHIC FINDINGS

HOSPITAL NAME

Westview VH

PRIMARY FINDINGS:

- Mildly enlarged heterogenous liver. The diffuse hepatic changes are non-specific and could be consistent with vacuolar hepatopathy, nodular hyperplasia, inflammatory/immune-mediated disease, fibrosis, extramedullary hematopoiesis, toxic hepatopathy (e.g., copper), infiltrative neoplasia (less likely) or other hepatopathy.

REFERRING VET

Dr. Barnes

- Shadowing material in the gastric lumen - correlate with feeding history and abdominal radiographs. If this patient was adequately fasted consider such differentials as delayed gastric emptying, ingested foreign material or a partial outflow tract obstruction (none observed.)

INVOICE

96044

SECONDARY FINDINGS:

- Small to moderate amount of hyperechoic debris within the gallbladder. There is no evidence of associated inflammation or obstruction.

DATE

2/14/22



PATIENT

Nicki Dohm

SPECIES

Canine

BREED

Australian Red Heeler

SEX

Spayed Female

AGE

11 years

WEIGHT

20.7 kg

INTERPRETED BY

Kathleen Sennello
DVM, MS, Diplomate
ACVIM (Small Animal
Internal Medicine)

IMAGING PERFORMED BY

Dr. Barnes

HOSPITAL NAME

Westview VH

REFERRING VET

Dr. Barnes

INVOICE

96044

DATE

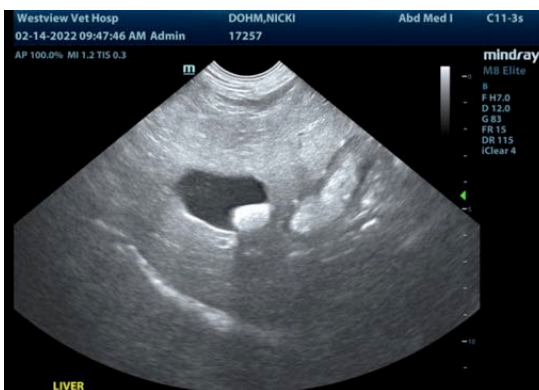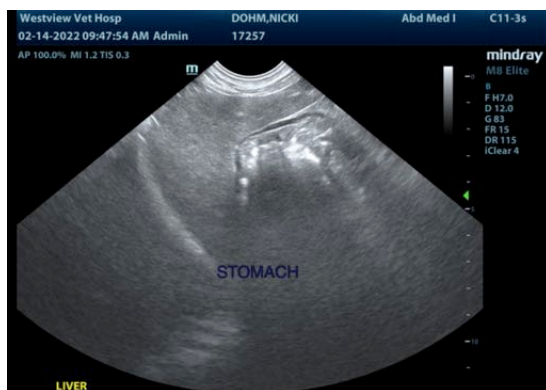
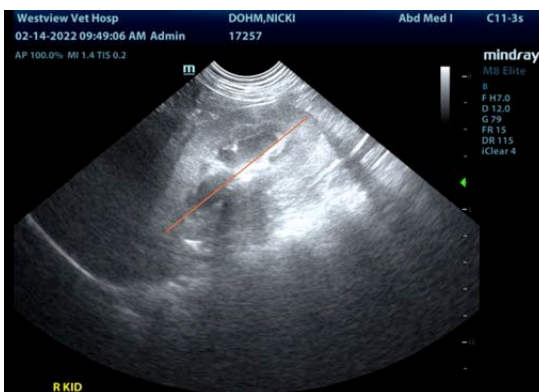
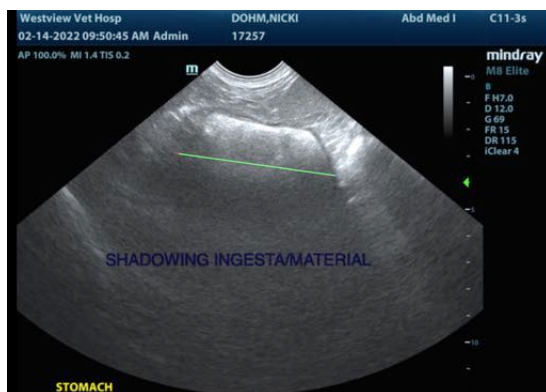2/14/22

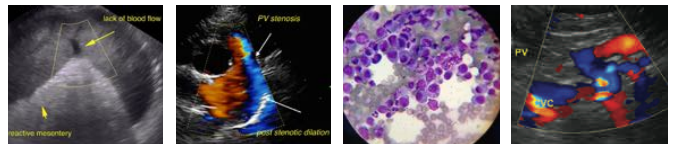
INTERPRETATION OF THE FINDINGS & FURTHER RECOMMENDATIONS

Today's scan is relatively normal. No focal lesions associated with the liver are observed and the gallbladder changes are very mild and likely insignificant. Unfortunately the ultrasonographic changes do not always reflect the severity or the cause of the hepatopathy present.

- Consider close evaluation of history for possible toxic changes examine medications, diet, dietary indiscretion etc.
- Consider PCR on urine/serum for leptospirosis (if not on antibiotics)/serology if recent antibiotic history
- If not already done, consider pre and post prandial bile acids to evaluate liver function
- Consider Fine needle aspirate if round cell neoplasia is on your differential list (25 g needle, normal coags)
- If no response to medical care (Denamarin, antibiotics,+/- Ursodiol etc...) Consider liver biopsy with samples obtained for histopathology, culture, and copper levels.

Additionally there is a moderate amount of shadowing material in the gastric lumen. Correlate with feeding history and abdominal radiographs. I suspect this is ingest, but if the patient was adequately fasted I recommend to continue monitoring for any foreign material.





PATIENT

Nicki Dohm

SPECIES

Canine

BREED

Australian Red Heeler

SEX

Spayed Female

AGE

11 years

WEIGHT

20.7 kg

INTERPRETED BY

Kathleen Sennello
DVM, MS, Diplomate
ACVIM (Small Animal
Internal Medicine)

IMAGING PERFORMED BY

Dr. Barnes

HOSPITAL NAME

Westview VH

REFERRING VET

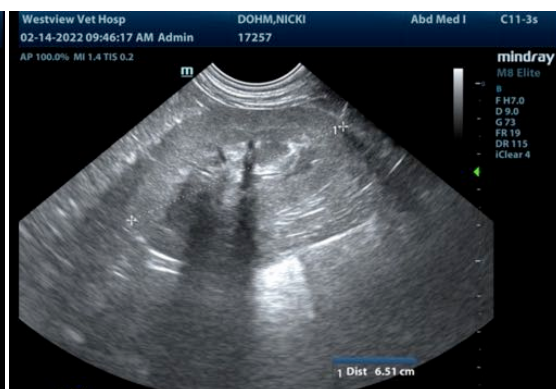
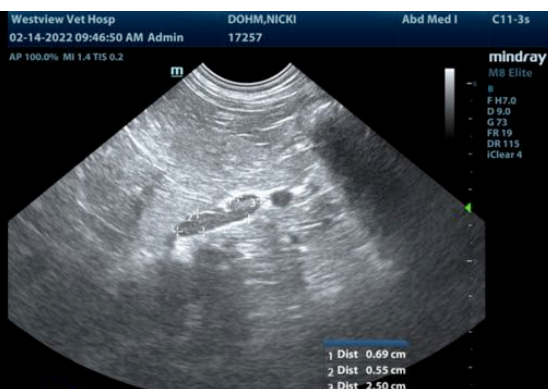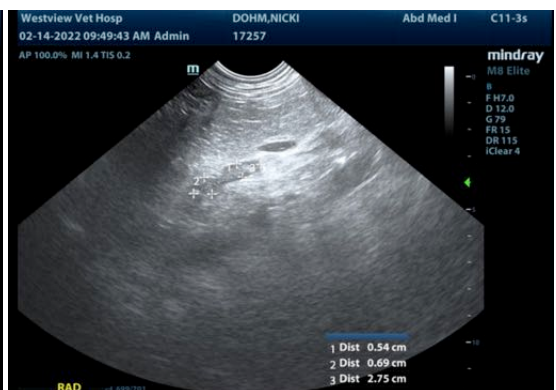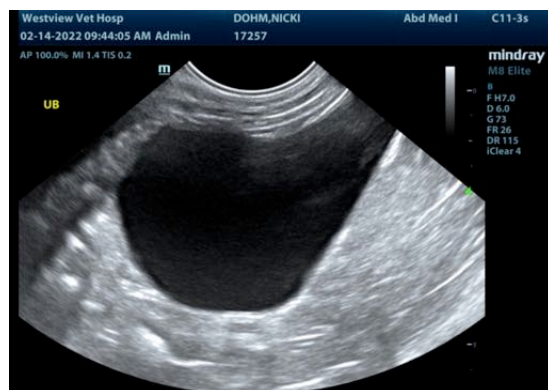
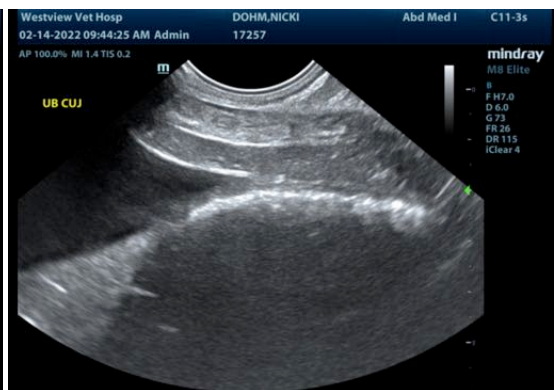
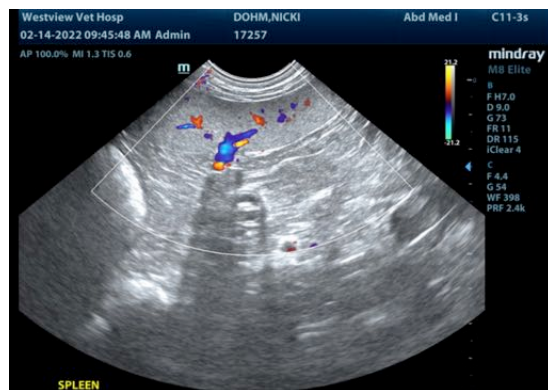
Dr. Barnes

INVOICE

96044

DATE

2/14/22



The information and recommendations provided are based on the images presented by the referring veterinarian/sonographer. No evaluation can be communicated regarding pathology that was not visible in the image/video clips provided.

Thank you for this referral. If the clinical or image interpretation does not parallel your findings or if I can be of any further assistance please contact me.

Kathleen Sennello DVM,MS, Diplomate ACVIM (Small animal Internal Medicine)
kathleen.sennello@sonopath.com