

**DATE**

2/14/22

PRESENTING CLINICAL SIGNS

History: Patient presents for evaluation of proteinuria, persistent 4+ protein, UP/CR consistent with proteinuria, no other concern or lab work abnormalities noted.

Lab Results: Attached separately.

PATIENT

Date of Previous IntraPet Ultrasound: No previous IntraPet scans.

Sedation: Dexdomitor/Torbugesic IM.

Stat Report: Not requested.

Imaging Performed By: Stephanie Pearce RDCS, RVT.

Kenwu Charintranont

SPECIES

Canine

ULTRASONOGRAPHIC EXAMINATION OF THE ABDOMEN**Urinary System**

The urinary bladder is moderately distended with anechoic urine. The Bladder wall, trigone, ureteral papillae and visible urethra (to a depth of 2cm) appear normal with no evidence of wall thickening, mucosal irregularities, masses or cystic calculi.

BREED

Pitbull Terrier

SEX

Neutered male

The prostate is normal in size (1.11 cm) and shape for this neutered male dog. The parenchyma is homogenous and the external margins are smooth. The prostatic urethra appears normal with no evidence of irregularity, invasion, mass effect or calculi.

AGE

9/29/13

The left kidney has a normal shape and size (7.32 cm). Overall echogenicity is normal with adequate corticomedullary distinction and a typical 1:3 cortex:medulla ratio. There is no evidence of perinephric inflammation or effusion. Small cortical cysts were noted. There is no evidence of pyelectasia, nephroliths, infarcts or hydronephrosis. Renal vasculature is normal.

WEIGHT

78 lbs

The right kidney has a normal shape and size (6.26 cm). Overall echogenicity is normal with adequate corticomedullary distinction and a typical 1:3 cortex:medulla ratio. There is no evidence of perinephric inflammation or effusion. Small cortical cysts were noted. There is no evidence of pyelectasia, nephroliths, infarcts or hydronephrosis. Renal vasculature is normal.

INTERPRETED BY

Kathleen Sennello
DVM, MS, Diplomate
ACVIM (Small Animal
Internal Medicine)

Adrenal Glands

The left adrenal gland is normal in size measuring 0.7 cm at the caudal pole It is observed in its normal position cranial to the left renal artery. It is normal in appearance (uniformly hypoechoic) and shape with no evidence of a mass effect.

HOSPITAL NAME

Perry Hall AH

The right adrenal gland is normal in size measuring 0.7 cm at the caudal pole It is observed in its normal position between the cranial aspect of the right kidney and the caudal vena cava. It is normal in appearance (uniformly hypoechoic) and shape with no evidence of a mass effect.

REFERRING VET

Dr. Miller

Spleen

The spleen is subjectively normal in size, echotexture is homogenous, and the splenic capsule is smooth with no irregularities. The blood flow through the hilus and splenic parenchyma appears normal. No focal parenchymal abnormalities are visualized.

INVOICE

96030

Liver

The liver is subjectively normal in size, and echogenicity with smooth peripheral margins. The parenchyma is homogenous echotexture. The visible portions of the vasculature and biliary tract appear normal. No focal nodules or cystic lesions are observed. The gallbladder lumen is moderately distended. The wall of the gallbladder is not thickened and has a smooth mucosal surface. Luminal contents are primarily anechoic. The cystic and common bile ducts are normal/not visible.

Gastrointestinal

The stomach contains minimal luminal contents. It measures at a normal thickness of <0.7cm with some variability due to the presence of rugal folds. The distinction of the gastric wall layers is adequate and there is no impression of reduced peristaltic activity. No masses or focal lesions were observed.

The visualized areas of duodenum, jejunum and ileum have a relatively uniform diameter with minimal fluid distension. Wall thickness is normal. Bowel loops follow a curvilinear path with distinct wall layering maintaining the typical 1:3 muscularis:mucosa layer ratio. The duodenum measured as normal and the jejunum measured as normal (0.32 cm). Visualized peristalsis appears appropriate. There were no focal lesions consistent with obstruction or a mass effect observed.

The ileocecal junction was visualized and exhibited normal intact wall layering and is subjectively of normal thickness. Sections of colon are visualized with formed fecal material and gas shadowing distally. There is no observed focal or generalized colon wall thickening or loss of layering.

Pancreas

The pancreas is normal and isoechoic to surrounding mesentery. There is no evidence of nodules or cystic lesions. There is no evidence of regional mesenteric inflammation or fluid.

Free Abdomen

Evaluation of the peritoneal cavity did not reveal any evidence of effusion. The sublumbar lymph nodes are slightly prominent, but isoechoic to the surrounding tissue and measured 0.67 cm, 0.85cm and 0.97 cm in cross section. The omentum is of normal uniform echogenicity.

ULTRASONOGRAPHIC FINDINGS

PRIMARY FINDINGS:

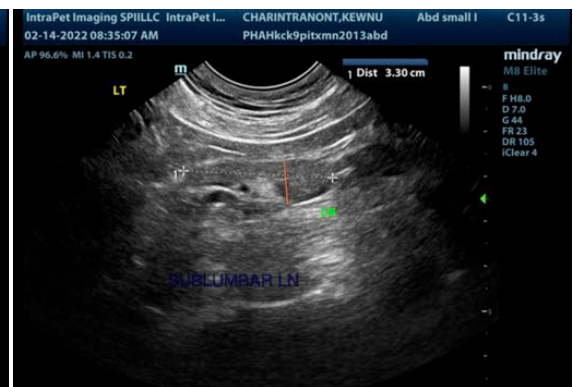
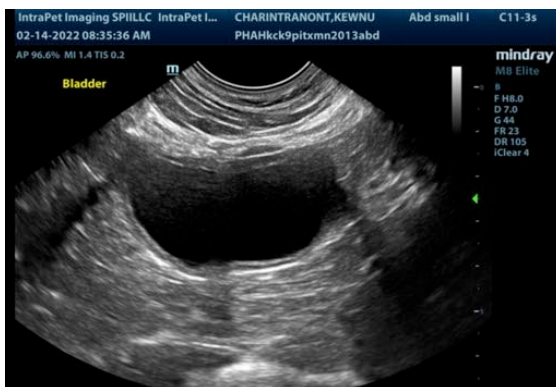
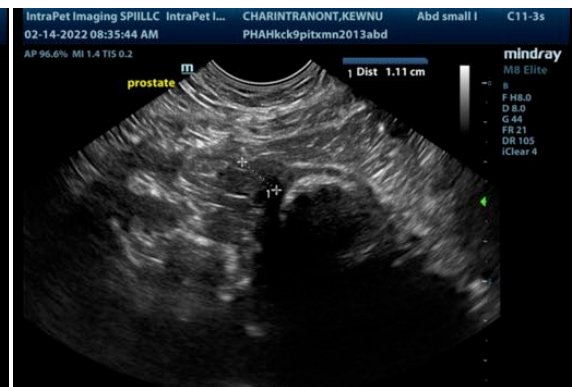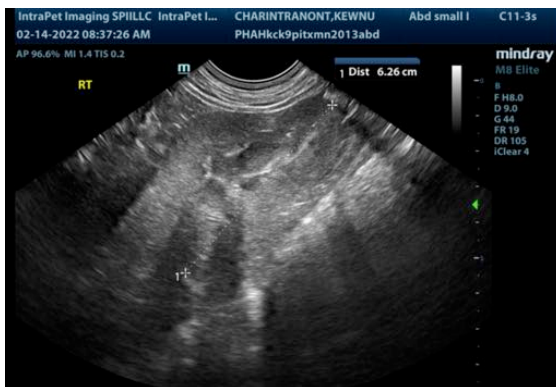
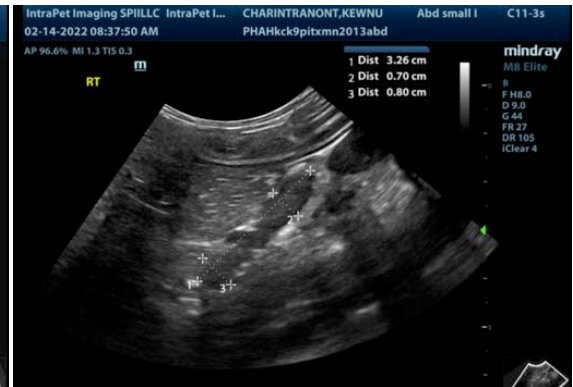
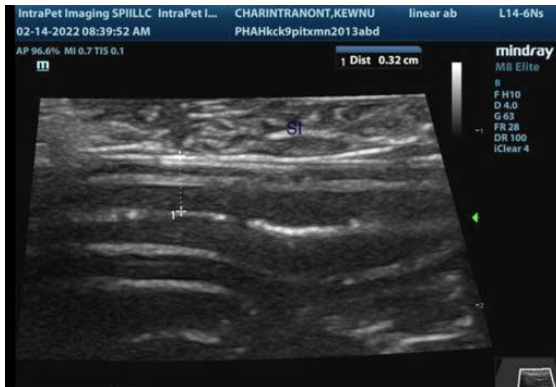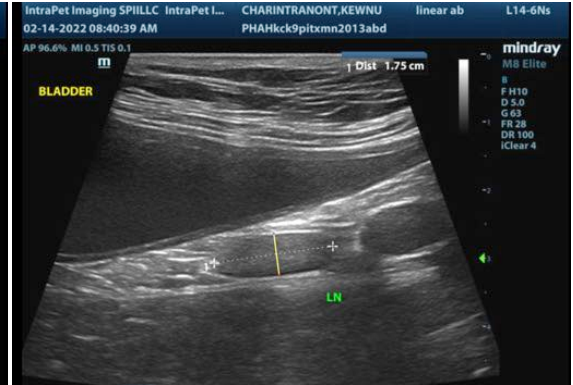
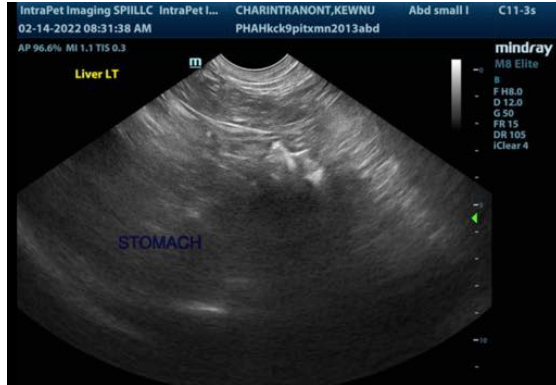- Prominent sublumbar lymph nodes. These lymph nodes are normal in echogenicity, but are somewhat prominent and plump in appearance. The findings are most consistent with reactive lymph nodes, but monitoring is strongly recommended.

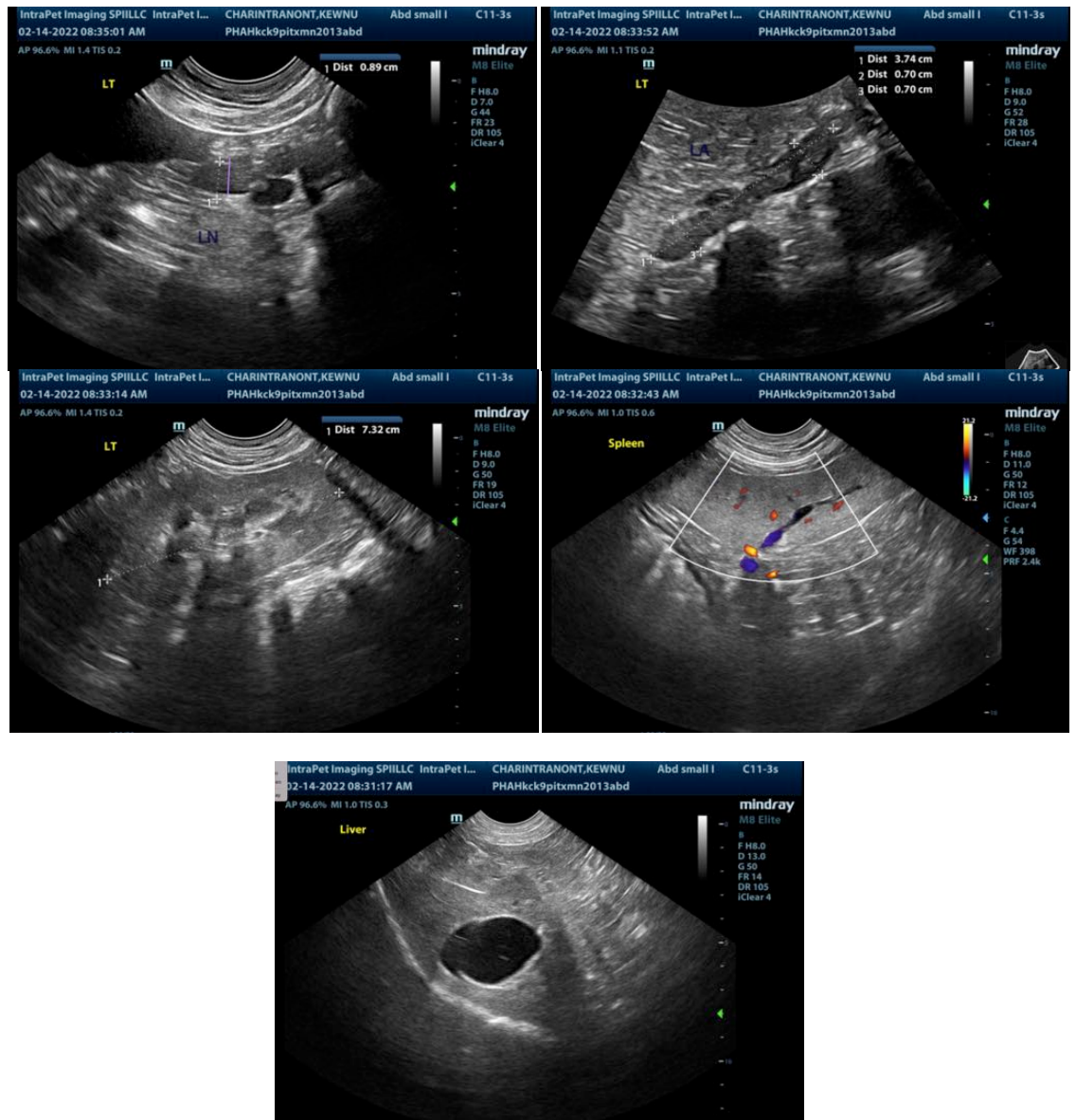
INTERPRETATION OF THE FINDINGS & FURTHER RECOMMENDATIONS

Today's scan is largely within normal limits. There were no large, focal mass lesions observed. The sublumbar lymph nodes are somewhat prominent. I recommend careful rectal exam to evaluate the anal glands and the prostate (which appeared normal on ultrasound today). I recommend to continue monitoring the lymph nodes in addition to the peripheral lymph nodes.

General recommendations for work-up of proteinuria include:

- Blood pressure evaluation.
- Imaging of the abdomen and thorax.
- Particularly in a Pit bull I would recommend Vector borne disease screening in addition to Babesia. Consider a canine comprehensive panel through NC State's Vector borne disease lab.
- Urinalysis and culture. If proteinuria persists and no obvious causes are identified then consider medical management. The ACVIM website has a good consensus statement regarding the treatment and diagnosis of proteinuria at www.ACVIM.org.





The information and recommendations provided are based on the images presented by the referring veterinarian. No evaluation can be communicated regarding pathology that was not visible in the image/video clips provided.

Thank you for this referral. If the clinical or image interpretation does not parallel your findings or if I can be of any further assistance please contact me.

Kathleen Sennello DVM,MS, Diplomate ACVIM (Small animal Internal Medicine)
 kathleen.sennello@sonopath.com