



DATE PRESENTING CLINICAL SIGNS

2/13/2026

Patient History: After last AUS, and with meds, vomiting stopped for 14 days. Vomit resumed daily after that.

PATIENT

This is a recheck ultrasound as recommended to evaluate for any changes since first done.

Winston Baran

Current Medications: Prednisolone 5 mg BID, Maropitant 24 mg 1/2 QD, Veraflox 25 mg/ml 1 1/2 QD x 10 days.

SPECIES

Labwork Results: Labwork not attached, reported as: No new diagnostics since 1st AUS.

Feline

Date of Previous IntraPet Ultrasound: 1/20/26. See attached.

BREED

Sedation: Not required to complete full diagnostic ultrasound.

DSH

Stat Report: Not requested.

SEX

Imaging Performed by: Stephanie Warga RDCS, RVT.

MN

ULTRASONOGRAPHIC EXAMINATION OF THE ABDOMEN

AGE

Urinary System

5 years

The urinary bladder is moderately distended with anechoic urine. The Bladder wall, trigone, ureteral papillae and visible urethra (to a depth of 2cm) appear normal with no evidence of wall thickening, mucosal irregularities, masses or cystic calculi.

WEIGHT

11.3 lbs

The left kidney has a normal shape and size (3.78 cm). Overall echogenicity is normal with adequate corticomedullary distinction and a typical 1:3 cortex:medulla ratio. There is no evidence of focal perinephric inflammation or effusion. There is no evidence of pyelectasia, nephroliths, infarcts or hydroureter. Renal vasculature is normal.

INTERPRETED BY

Kathleen Sennello DVM,
MS, Diplomate ACVIM
(Small Animal Internal
Medicine)

The right kidney has a normal shape and size (3.9 cm). Overall echogenicity is normal with adequate corticomedullary distinction and a typical 1:3 cortex:medulla ratio. There is no evidence of focal perinephric inflammation or effusion. There is no evidence of pyelectasia, nephroliths, infarcts or hydroureter. Renal vasculature is normal.

HOSPITAL NAME

Chadwell Animal
Hospital

Adrenal Glands

REFERRING VET

Dr. Schaupp

The left adrenal gland is normal in size measuring 0.27 cm at the caudal pole. It is observed in its normal position cranial to the left renal artery. It is normal in appearance (uniformly hypoechoic) and shape with no evidence of a mass effect.

INVOICE

11308

The right adrenal gland is normal in size measuring 0.37 cm at the caudal pole. It is observed in its normal position between the cranial aspect of the right kidney and the caudal vena cava. It is normal in appearance (uniformly hypoechoic) and shape with no evidence of a mass effect.

Spleen

The spleen is subjectively normal in size (0.71 cm), echotexture is homogenous, and the splenic capsule is smooth with no irregularities. The blood flow through the hilus and splenic parenchyma appears normal. No focal parenchymal abnormalities are visualized.

Liver

The liver is subjectively normal in size, and echogenicity with smooth peripheral margins. The parenchyma is homogenous echotexture. The visible portions of the vasculature and biliary tract appear normal. No focal nodules or cystic lesions are observed.

The gall bladder lumen is moderately distended. The wall of the gall bladder is not thickened and has a smooth mucosal surface. Luminal contents are mild and likely incidental at this time. The cystic and common bile ducts are normal/not visible.

Gastrointestinal

The stomach contains minimal luminal contents. It measures at a normal thickness of <0.36cm with some variability due to the presence of rugal folds. The distinction of the gastric wall layers is adequate and there is no impression of reduced peristaltic activity. No masses or focal lesions were observed.

The visualized areas of duodenum, jejunum and ileum have a uniform diameter with minimal fluid distension. Wall thickness is normal to slightly increased. Bowel loops follow a typical curvilinear path with distinct wall layering, but some areas display a prominent muscularis layer which does not display the typical 1:3 muscularis:mucosa layer ratio. The jejunum measured 0.26 cm in diameter. Visualized peristalsis appears appropriate. There were no focal lesions consistent with obstruction or a mass effect observed.

The ileocecal junction was visualized and exhibited normal intact wall layering and is subjectively of normal thickness. Sections of colon are visualized with formed fecal material and gas shadowing distally. There is no observed focal or generalized colon wall thickening or loss of layering.

Pancreas

The pancreas is mildly prominent and mottled in the right limb. There is no evidence of nodules or cystic lesions. There is no evidence of regional mesenteric inflammation or fluid.

Free Abdomen

Evaluation of the peritoneal cavity did not reveal any evidence of effusion. There is no evidence of a diffuse lymphadenopathy. There is a distinct, hypoechoic, rounded structure most consistent with a lymph node in the right cranial abdomen measuring 1.8 cm x 1.46 cm (previous measurement 1/20/26 – 1.28 cm x 1.88 cm) with surrounding reactive mesentery. Additionally, there is a hyperechoic structure visualized in the left cranial abdomen measuring 1.0 cm x 0.69 cm, which appears stable from the previous exam with no associated inflammation. The omentum is of normal uniform echogenicity.

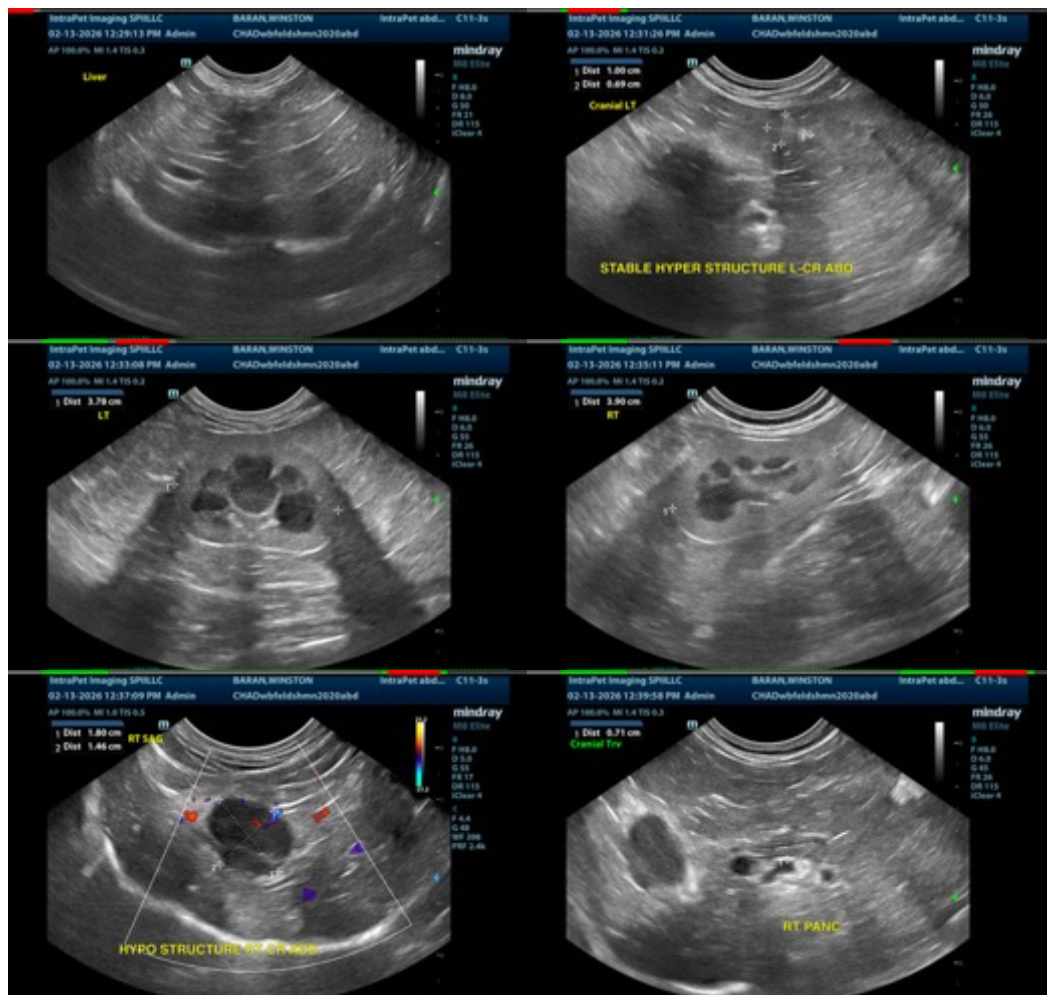
ULTRASONOGRAPHIC FINDINGS

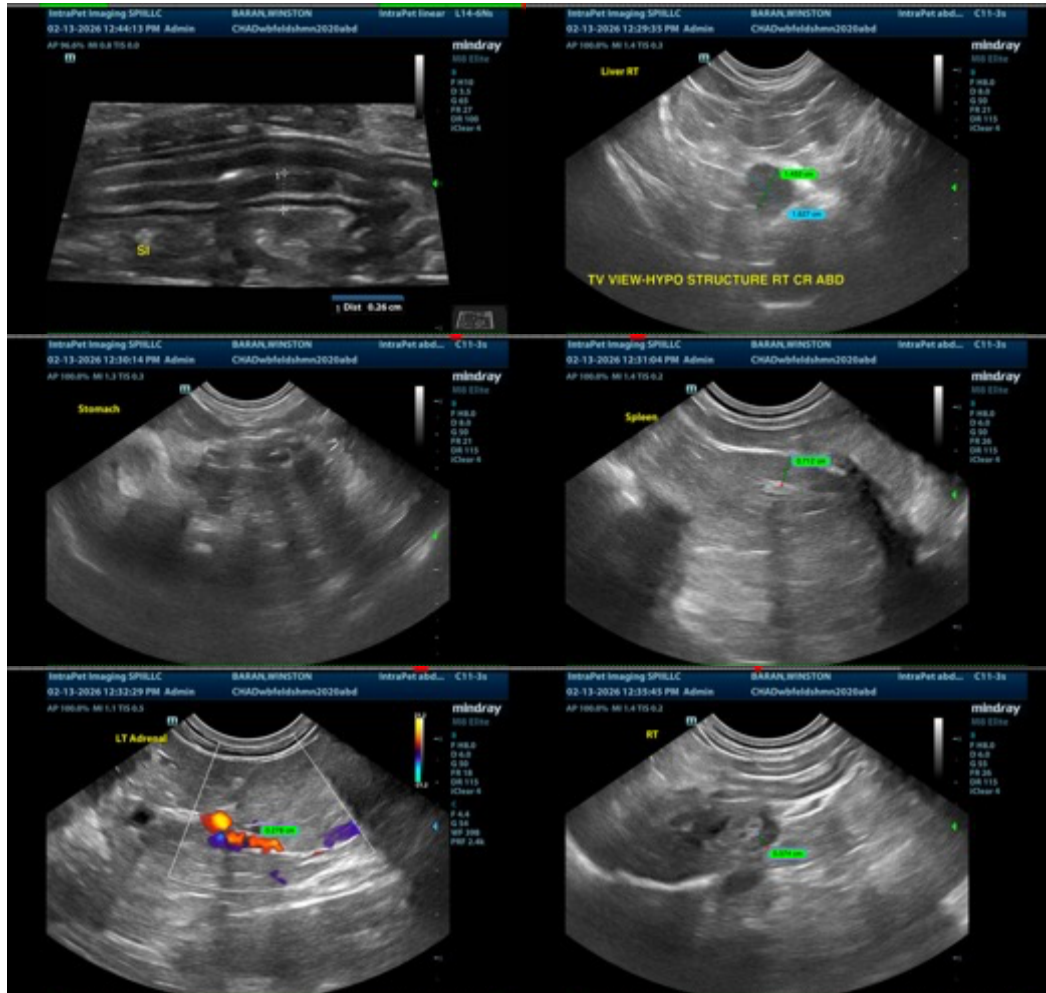
- Pancreatic changes in the right limb most consistent with chronic pancreatic remodeling.

- Mildly “ropy” small intestine with some areas exhibiting prominent muscularis layer. The small intestinal wall changes are most consistent with an inflammatory process (i.e., inflammatory bowel disease) with a low possibility of emerging lymphoma.
- Hypochoic rounded structure in the right cranial abdomen with surrounding reactive mesentery. Findings are most consistent with a lymph node, but a pancreatic cyst or abscess or a mass lesion in the region cannot be ruled out.

INTERPRETATION OF THE FINDINGS & FURTHER RECOMMENDATIONS

Today’s scan appears very similar to the previous exam on 1/20/26. The hypochoic rounded structure in the right cranial abdomen is still visible/slightly more prominent than the previous exam. The definitive nature of this structure is uncertain. The right limb of the pancreas is visible, but a direct connection is not observed. If a safe window for sampling is available, consider a fine needle aspirate (possibly with deep sedation as this may help with access?) Alternately, surgical evaluation and/or contrast CT scan to better evaluate this region are options. If surgical evaluation is pursued, recommend biopsies of the GI tract as this lesion is highly suspicious but may not be associated with the current clinical symptoms.





The information and recommendations provided are based on the images presented by the referring veterinarian/sonographer. No evaluation can be communicated regarding pathology that was not visible in the image/video clips provided.

Thank you for this referral. If the clinical or image interpretation does not parallel your findings or if I can be of any further assistance please contact me.

Kathleen Sennello DVM,MS, Diplomate ACVIM (Small animal Internal Medicine)
 info@sonopath.com