



**DATE PRESENTING CLINICAL SIGNS**

2/13/2026

**Patient History:** Presented 2/7/26 for annual PE. On PE, mild muscle wasting, otherwise PE WNL. Upon POCUS-guided cystocentesis for UA as part of annual bloodwork/UA diagnostics, large hyperechoic abnormality of bladder wall appreciated. Subsequent rads did not show any radioopaque bladder stones.

**PATIENT**

Shere Kahn Layton

**Current Medications:** Cosequin - 2 caps over food q24h

**SPECIES**

Feline

**Labwork Results:** Labwork attached, reported as: \*2V whole body rads - normal appearance of heart and lungs, no pulmonary nodules indicative of mets, liver tucked under ribcage, ingesta in stomach, stool in colon, some urine in bladder, no obvious uroliths or soft tissue opacities within bladder, spondylosis L1-2  
\*CBC/CHEM/T4: Pending, NSF on BW from 2/2025

**BREED**

DSH

**Date of Previous IntraPet Ultrasound:** No previous.

**SEX**

MN

**Sedation:** Not required to complete full diagnostic ultrasound.

**AGE**

12 years

**Stat Report:** Not requested.

**Imaging Performed by:** Stephanie Warga RDCS, RVT.

**WEIGHT**

12.88 lbs

**ULTRASONOGRAPHIC EXAMINATION OF THE ABDOMEN**

**Urinary System**

The urinary bladder is moderately distended with urine. There's a mild to moderate amount of suspended echogenic debris and a small amount of hyperechoic debris adhered to the ventral bladder wall. The region of the trigone, ureteral papillae and proximal urethra appear free of any mass lesions or calculi.

The left kidney has a normal shape and size (3.98 cm). Overall echogenicity is normal with adequate corticomedullary distinction and a typical 1:3 cortex:medulla ratio. There is no evidence of focal perinephric inflammation or effusion. There is no evidence of pyelectasia, nephroliths, infarcts or hydroureter. Renal vasculature is normal.

**INTERPRETED BY**

Kathleen Sennello DVM,  
MS, Diplomate ACVIM  
(Small Animal Internal  
Medicine)

The right kidney has a normal shape and size (4.31 cm). Overall echogenicity is normal with adequate corticomedullary distinction and a typical 1:3 cortex:medulla ratio. There is no evidence of focal perinephric inflammation or effusion. There is no evidence of pyelectasia, nephroliths, infarcts or hydroureter. Renal vasculature is normal.

**HOSPITAL NAME**

Chadwell Animal  
Hospital

**REFERRING VET**

Dr. Mengers

**Adrenal Glands**

The left adrenal gland is normal in size measuring 0.49 cm at the caudal pole. It is observed in its normal position cranial to the left renal artery. It is normal in appearance (uniformly hypoechoic) and shape with no evidence of a mass effect.

**INVOICE**

11308

The right adrenal gland is normal in size measuring 0.4 cm at the caudal pole. It is observed in its normal position between the cranial aspect of the right kidney and the caudal vena cava. It is normal in appearance (uniformly hypoechoic) and shape with no evidence of a mass effect.

**Spleen**

The spleen is subjectively normal in size (1.08 cm), echotexture is homogenous, and the splenic capsule is smooth with no irregularities. The blood flow through the hilus and splenic parenchyma appears normal. No focal parenchymal abnormalities are visualized.

### ***Liver***

The liver is subjectively normal in size, and echogenicity with smooth peripheral margins. The parenchyma is homogenous echotexture. The visible portions of the vasculature and biliary tract appear normal. No focal nodules or cystic lesions are observed.

The gall bladder lumen is moderately distended. The wall of the gall bladder is not thickened and has a smooth mucosal surface. Luminal contents are mild and likely incidental at this time. The cystic and common bile ducts are normal/not visible.

### ***Gastrointestinal***

The stomach contains minimal luminal contents. It measures at a normal thickness of <0.36cm with some variability due to the presence of rugal folds. The distinction of the gastric wall layers is adequate and there is no impression of reduced peristaltic activity. No masses or focal lesions were observed.

The visualized areas of duodenum, jejunum and ileum have a uniform diameter with minimal fluid distension. Wall thickness is normal to slightly increased. Bowel loops follow a typical curvilinear path with distinct wall layering, but some areas display a prominent muscularis layer which does not display the typical 1:3 muscularis:mucosa layer ratio. The duodenum measured 0.31 cm in diameter and the jejunum measured 0.29 cm in diameter. Visualized peristalsis appears appropriate. The small intestine appears diffusely thickened with a very prominent muscularis layer.

The ileocecal junction was visualized and exhibited normal intact wall layering and is subjectively of normal thickness. Sections of colon are visualized with formed fecal material and gas shadowing distally. There is no observed focal or generalized colon wall thickening or loss of layering.

### ***Pancreas***

The pancreas is visible/slightly hypoechoic in both limbs. There is no evidence of nodules or cystic lesions. There is no evidence of regional mesenteric inflammation or fluid.

### ***Free Abdomen***

Evaluation of the peritoneal cavity did not reveal any evidence of effusion. There is no evidence of a severe diffuse lymphadenopathy but occasional prominent lymph nodes are visualized. The pancreaticoduodenal lymph node measures 0.82 cm x 0.52 cm. A mesenteric lymph node is visualized measuring 0.47 cm x 1.08 cm. The omentum is of normal uniform echogenicity.

## **ULTRASONOGRAPHIC FINDINGS**

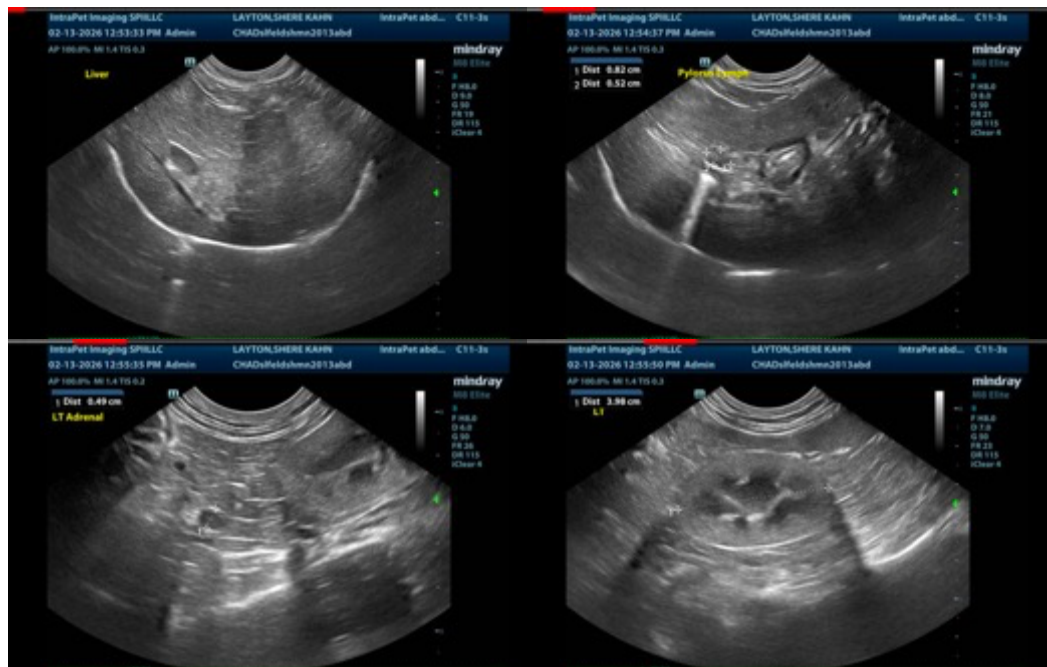
- Mild suspended and dependent echogenic debris in the urinary bladder. The echogenic debris in the bladder lumen could be consistent with cells, crystals, and/or mucus. Recommend urinalysis and culture.

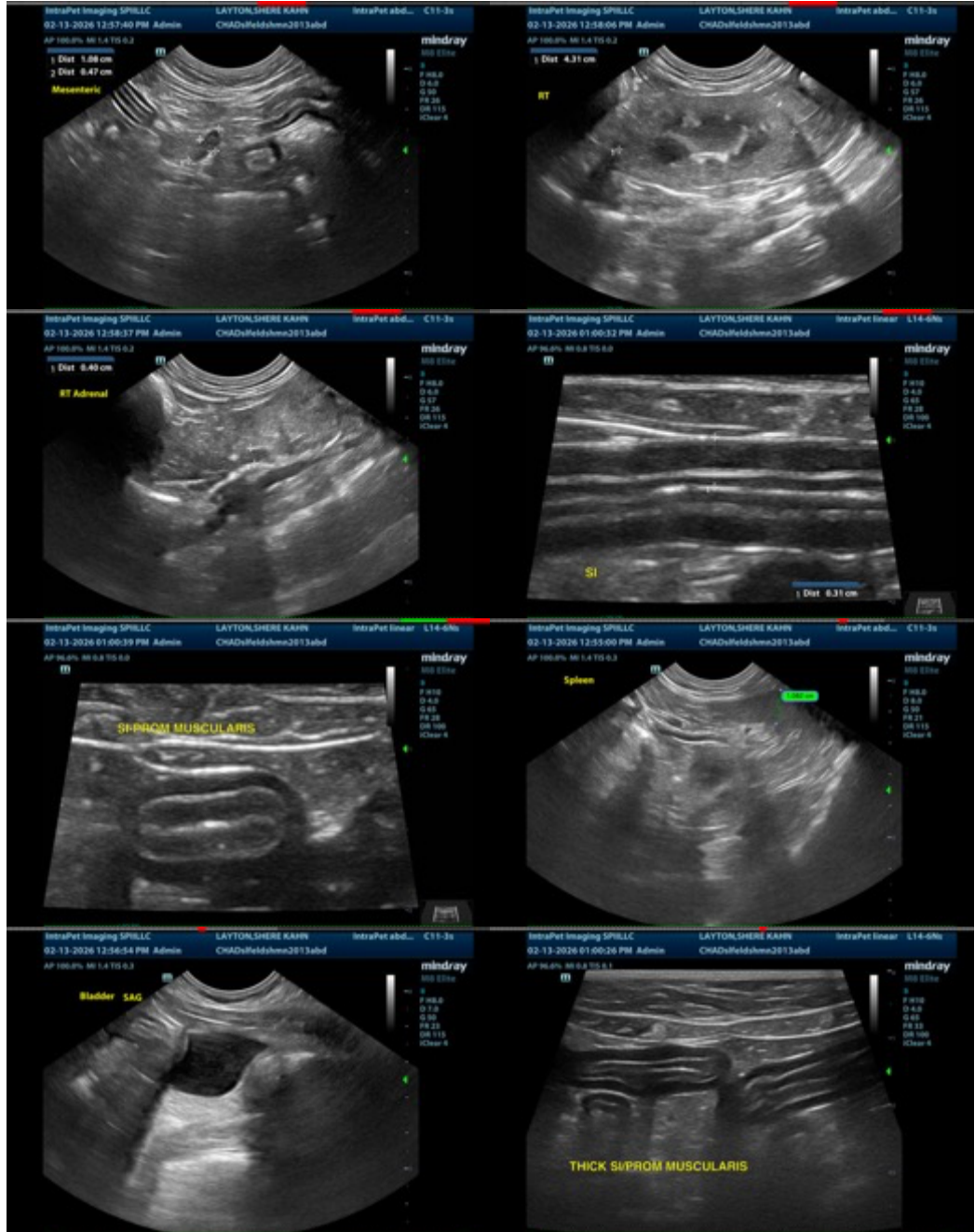
- Pancreatic changes most consistent with chronic pancreatic remodeling.
- Diffusely thickened small intestine with prominent muscularis. The small intestinal wall changes are most consistent with an inflammatory process (i.e., inflammatory bowel disease) with a low possibility of emerging lymphoma.
- Occasional prominent mesenteric lymph nodes. Findings are most consistent with reactive lymph nodes, although early neoplastic change cannot be ruled out.

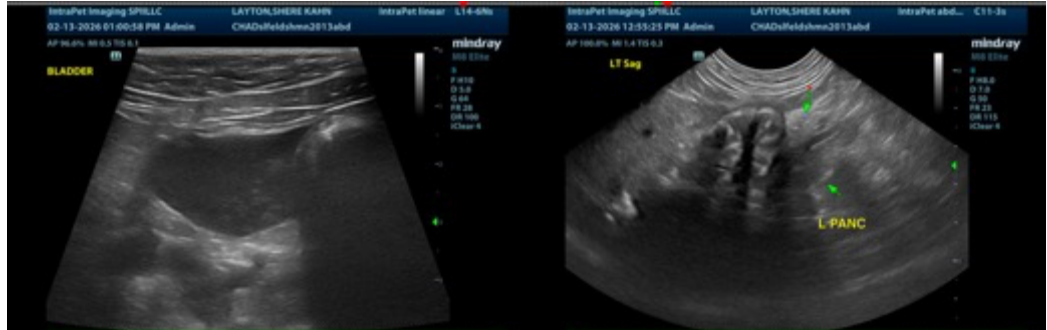### INTERPRETATION OF THE FINDINGS & FURTHER RECOMMENDATIONS

The small intestine is diffusely thickened with a very prominent muscularis layer. Given the weight loss reported, findings could be concerning for a primary enteropathy. Given the lack of overt gastrointestinal symptoms described recommend initial evaluation with a GI Panel to Texas A&M for a qualitative fPLI/TLI, cobalamin, and folate. If significant abnormalities are noted and/or weight loss is persistent, further evaluation may be warranted.

No focal lesions are visualized associated with the urinary bladder. There is some mild suspended echogenic debris, and some hyperechoic debris adhered to the ventral wall of the urinary bladder. Correlate with a urinalysis +/- culture results.







The information and recommendations provided are based on the images presented by the referring veterinarian/sonographer. No evaluation can be communicated regarding pathology that was not visible in the image/video clips provided.

Thank you for this referral. If the clinical or image interpretation does not parallel your findings or if I can be of any further assistance please contact me.

Kathleen Sennello DVM,MS, Diplomate ACVIM (Small animal Internal Medicine)  
info@sonopath.com