



## PATIENT

Porter Etchemendy

## SPECIES

Canine

## BREED

Chihuahua

## SEX

Spayed Female

## AGE

10 Years

## WEIGHT

3.6 kg

## INTERPRETED BY

Kathleen Sennello DVM,  
MS, Diplomate ACVIM  
(Small Animal Internal  
Medicine)

## IMAGING PERFORMED BY

Loetitia Saint-Jacques,  
LVT

## HOSPITAL NAME

Desert Hills Animal  
Hospital

## REFERRING VET

Dr. Brock

## INVOICE

72923

## DATE

2/12/26

## PRESENTING CLINICAL SIGNS

Patient has a history of mild elevation in ALT. Patient presented on 2/10/2026 as ADR. Not wanting to eat, not acting like herself, no vomiting/diarrhea. No travel history/change in diet. Working diagnosis. Liver disease. ALT 1502, ALP 441, T.Bilirubin 0.8 K 3.5

Meds- Milk thistle 300mg/SamE supplement 100mg, Clavamox 62.5mg BID, Entyce 0.4mls SID

Abnormal PE/Chem/CBC/UA Results: CONCLUSIONS: 1. A definitive cause of the clinical signs is not determined from this exam. 2. The mineral sediment within the stomach could be an indication of dietary indiscretion, however, no evidence of a complete mechanical obstruction is identified in this study. Pancreatitis or nonspecific gastroenteritis remain in consideration. 3. Questionable microhepatia. This could be a variant of normal for this patient. Cirrhosis is not ruled out. A portosystemic shunt is thought to be less likely based on the age of the patient

## ULTRASONOGRAPHIC EXAMINATION OF THE ABDOMEN

### Urinary System

The urinary bladder is moderately distended with anechoic urine. The Bladder wall, trigone, ureteral papillae and visible urethra (to a depth of 2cm) appear normal with no evidence of wall thickening, mucosal irregularities, masses or cystic calculi.

The left kidney has a normal shape and size (3.65 cm) with occasional small pinpoint cortical mineralizations. Overall echogenicity is normal with adequate corticomedullary distinction and a typical 1:3 cortex:medulla ratio. There is no evidence of focal perinephric inflammation or effusion. There is no evidence of pyelectasia, infarcts or hydroureter. Renal vasculature is normal.

The right kidney has a normal shape and size (3.91 cm). Overall echogenicity is normal with adequate corticomedullary distinction and a typical 1:3 cortex:medulla ratio. There is no evidence of focal perinephric inflammation or effusion. There is no evidence of pyelectasia, nephroliths, infarcts or hydroureter. Renal vasculature is normal.

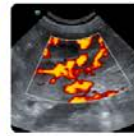
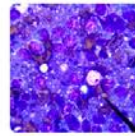
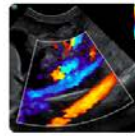
### Adrenal Glands

The left adrenal gland is normal in size measuring 0.39 cm at the cranial pole and 0.55 cm at the caudal pole. It is observed in its normal position cranial to the left renal artery. It is normal in appearance (uniformly hypoechoic) and shape with no evidence of a mass effect.

The right adrenal gland is normal in size measuring 0.50 cm at the caudal pole. It is observed in its normal position between the cranial aspect of the right kidney and the caudal vena cava. It is normal in appearance (uniformly hypoechoic) and shape with no evidence of a mass effect.

### Spleen

The spleen is subjectively normal in size (1.06 cm), echotexture is homogenous, and the splenic capsule is smooth with no irregularities. The blood flow through the hilus and splenic parenchyma appears normal. No focal parenchymal abnormalities are visualized.



## PATIENT

Porter Etchemendy

## SPECIES

Canine

## BREED

Chihuahua

## SEX

Spayed Female

## AGE

10 Years

## WEIGHT

3.6 kg

## INTERPRETED BY

Kathleen Sennello DVM,  
MS, Diplomate ACVIM  
(Small Animal Internal  
Medicine)

## IMAGING PERFORMED BY

Loetitia Saint-Jacques,  
LVT

## HOSPITAL NAME

Desert Hills Animal  
Hospital

## REFERRING VET

Dr. Brock

## INVOICE

72923

## DATE

2/12/26

## Liver

The liver is subjectively normal to borderline small in size, and normal in echogenicity with smooth peripheral margins. The parenchyma is mildly heterogenous in echotexture with subtle, indistinct focal mottling. The visible portions of the vasculature and biliary tract appear normal. No focal nodules or cystic lesions are observed.

The gall bladder lumen is moderately distended. The gallbladder wall is slightly prominent/thickened measuring at 0.24 cm. There is a moderate amount of non-organized echogenic debris. The debris appears consolidated into a "sludge ball". The cystic and common bile ducts are normal/not visible.

## Gastrointestinal

The stomach contains a large amount of fluid and shadowing ingesta. The gastric wall is prominent, with intact layering, measuring at 0.30 cm. Pyloric wall is prominent and mildly thickened at 0.48 cm with intact wall layering. The distinction of the gastric wall layers is adequate and there is no impression of reduced peristaltic activity. No masses or focal lesions were observed.

The visualized areas of duodenum, jejunum and ileum have a relatively uniform diameter with minimal fluid distension. Wall thickness is normal. Bowel loops follow a curvilinear path with distinct wall layering maintaining the typical 1:3 muscularis:mucosa layer ratio. Duodenum wall measures 0.30 cm. Jejunum wall measures 0.28 cm. Visualized peristalsis appears appropriate. There were no focal lesions consistent with obstruction or a mass effect observed.

Sections of colon are visualized with formed fecal material and gas shadowing distally. There is no observed focal or generalized colon wall thickening or loss of layering.

## Pancreas

The pancreas is normal and isoechoic to surrounding mesentery. There is no evidence of nodules or cystic lesions. There is no evidence of regional mesenteric inflammation or fluid.

## Free Abdomen

Evaluation of the peritoneal cavity did not reveal any evidence of effusion. No evidence of a diffuse lymphadenopathy. A prominent portal lymph node is visualized measuring 0.73 cm x 2.14 cm. Additionally, other smaller cystic portal lymph nodes are noted. The omentum is normal in echogenicity.

## ULTRASONOGRAPHIC FINDINGS

- Normal/borderline small, mildly heterogeneous liver – The diffuse hepatic changes are non-specific and could be consistent with vacuolar hepatopathy, nodular hyperplasia, inflammatory/immune-mediated disease, fibrosis, extramedullary hematopoiesis, toxic hepatopathy (e.g., copper), infiltrative neoplasia (less likely) or other hepatopathy.
- Moderate gallbladder debris forming a "sludge ball" with mildly thickened gallbladder wall – The significance of the aggregated gallbladder debris is unclear. This could represent an early mucocele, cholestasis, or may be secondary to fasting but seems unlikely to be causing a current issue. Recommend continued monitoring.
- Fluid/ingesta distended stomach with a prominent/mildly thickened gastric/pyloric wall – Wall layering appears intact. Findings could be consistent with gastritis.



**PATIENT**

Porter Etchemendy

**SPECIES**

Canine

**BREED**

Chihuahua

**SEX**

Spayed Female

**AGE**

10 Years

**WEIGHT**

3.6 kg

**INTERPRETED BY**

Kathleen Sennello DVM,  
MS, Diplomate ACVIM  
(Small Animal Internal  
Medicine)

**IMAGING PERFORMED BY**

Loetitia Saint-Jacques,  
LVT

**HOSPITAL NAME**

Desert Hills Animal  
Hospital

**REFERRING VET**

Dr. Brock

**INVOICE**

72923

**DATE**

2/12/26

- Prominent/cystic portal lymph nodes- Findings are most consistent with reactive lymph nodes, although early neoplastic lymph nodes cannot be ruled out.

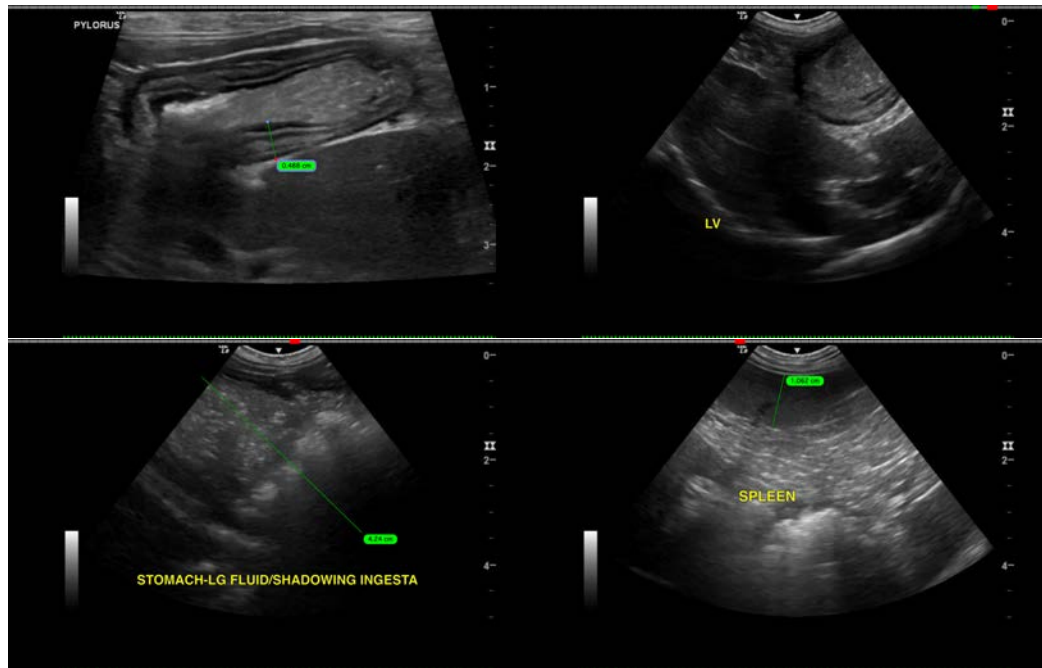
**INTERPRETATION OF THE FINDINGS & FURTHER RECOMMENDATIONS**

No focal lesions are visualized associated with the liver. No evidence of a shunting vessel is visualized. This does not rule out a shunt but makes it somewhat less likely. It is likely that ultimate evaluation of the liver would require liver biopsies with samples for histopathology, culture and copper levels. Prior to considering that, recommend the following:

- Recommend pre- and post-prandial bile acids to assess liver function.
- Consider screening for Leptospirosis.

In the interim, consider treatment for acute liver injury with a course of Ursodiol, Denamarin, and antibiotics, as the gallbladder wall is mildly thickened, and there is a moderate amount of consolidated sludge in the gallbladder, which could be an indicator of early cholecystitis.

The stomach is significantly distended with fluid and ingesta despite a moderate fast. No evidence of an obstruction is visualized at the outflow tract, although progressive motility appears somewhat subjectively reduced, and the wall appears prominent, possibly consistent with gastritis and mild ileus. If significant delayed gastric emptying is suspected, you could consider upper GI endoscopy to further evaluate for any partially obstructive lesion and to obtain biopsies of the proximal GI tract.



Imaging performed by



pawsonography@gmail.com  
530-786-8340



Clinical Sonography & Telectology  
Educational Teleconsultation Services™

# SonoPath

FOSTERING THE ART OF VETERINARY MEDICINE™

SonoPath.com info@sonopath.com 1.800.838.4268

## PATIENT

Porter Etchemendy

## SPECIES

Canine

## BREED

Chihuahua

## SEX

Spayed Female

## AGE

10 Years

## WEIGHT

3.6 kg

## INTERPRETED BY

Kathleen Sennello DVM,  
MS, Diplomate ACVIM  
(Small Animal Internal  
Medicine)

## IMAGING PERFORMED BY

Loetitia Saint-Jacques,  
LVT

## HOSPITAL NAME

Desert Hills Animal  
Hospital

## REFERRING VET

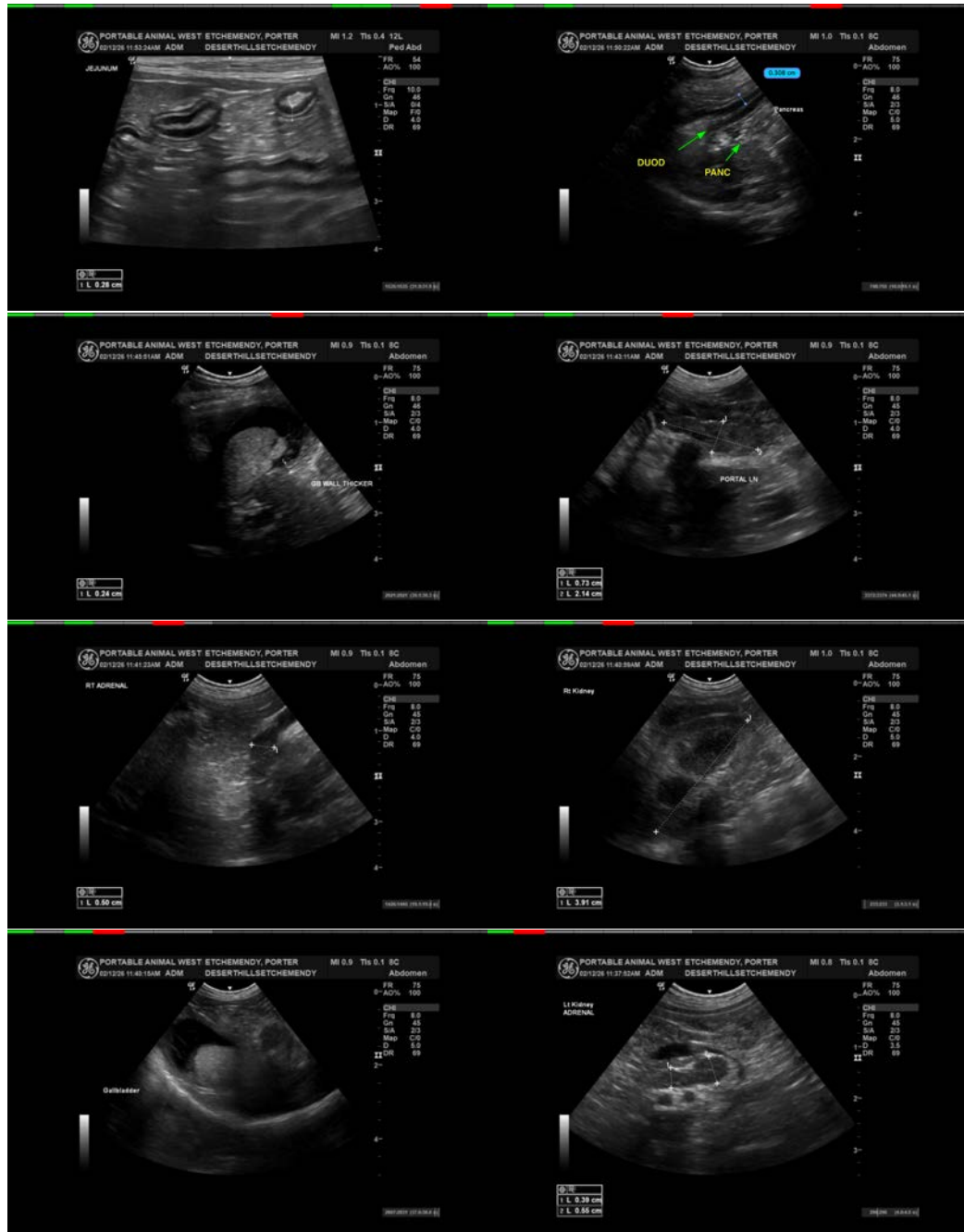
Dr. Brock

## INVOICE

72923

## DATE

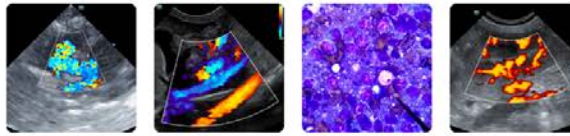
2/12/26



Imaging  
performed by



Portland Animal Hospital Sonography, Inc.  
pawsonography@gmail.com  
530-786-8340



**Clinical Sonography & Telecytology**  
Educational Teleconsultation Services™

**SonoPath**

FOSTERING THE ART OF VETERINARY MEDICINE™

SonoPath.com info@sonopath.com 1.800.838.4268

## PATIENT

Porter Etchemendy

## SPECIES

Canine

## BREED

Chihuahua

## SEX

Spayed Female

## AGE

10 Years

## WEIGHT

3.6 kg

## INTERPRETED BY

Kathleen Sennello DVM,  
MS, Diplomate ACVIM  
(Small Animal Internal  
Medicine)

## IMAGING PERFORMED BY

Loetitia Saint-Jacques,  
LVT

## HOSPITAL NAME

Desert Hills Animal  
Hospital

## REFERRING VET

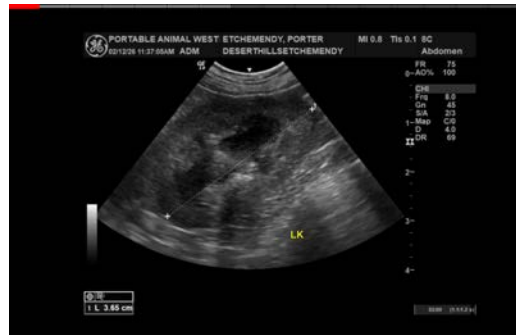Dr. Brock

## INVOICE

72923

## DATE

2/12/26



The information and recommendations provided are based on the images presented by the referring veterinarian/sonographer. No evaluation can be communicated regarding pathology that was not visible in the image/video clips provided.

Thank you for this referral. If the clinical or image interpretation does not parallel your findings or if I can be of any further assistance please contact me.

Kathleen Sennello DVM,MS, Diplomate ACVIM (Small animal Internal Medicine)

info@sonopath.com