



**PATIENT**

Faith Fleming

**SPECIES**

Canine

**BREED**

Australian Blue Heeler

**SEX**

Spayed Female

**AGE**

8 Years 11 Months

**WEIGHT**

48.7 lbs

**INTERPRETED BY**

Kathleen Sennello DVM,  
 MS, Diplomate ACVIM  
 (Small Animal Internal  
 Medicine)

**IMAGING PERFORMED BY**

Kathleen Byrnes

**HOSPITAL NAME**

Harmony Heights  
 Animal Hospital

**REFERRING VET**

Dr. Sechrist

**INVOICE**

72934

**DATE**

2/12/26

**PRESENTING CLINICAL SIGNS**

P presented for exam of firm mass on right flank. P had splenectomy a few months ago due to hemangiosarcoma. VD rad attached. Concern for intrabdominal mass and spread of hemangiosarcoma.

On Yunnan Baiyo.

**ULTRASONOGRAPHIC EXAMINATION OF THE ABDOMEN**

**Urinary System**

The urinary bladder is moderately distended with anechoic urine. The Bladder wall, trigone, ureteral papillae and visible urethra (to a depth of 2cm) appear normal with no evidence of wall thickening, mucosal irregularities, masses or cystic calculi.

The left kidney has a normal shape and size (6.48 cm). Overall echogenicity is normal with adequate corticomedullary distinction and a typical 1:3 cortex:medulla ratio. There is no evidence of focal perinephric inflammation or effusion. There is no evidence of pyelectasia, nephroliths, infarcts or hydroureter. Renal vasculature is normal.

The right kidney has a normal shape and size (5.67 cm). Overall echogenicity is normal with adequate corticomedullary distinction and a typical 1:3 cortex:medulla ratio. There is no evidence of focal perinephric inflammation or effusion. There is no evidence of pyelectasia, nephroliths, infarcts or hydroureter. Renal vasculature is normal.

**Adrenal Glands**

The left adrenal gland is normal in size measuring 0.46 cm at the cranial pole and 0.47 cm at the caudal pole. It is observed in its normal position cranial to the left renal artery. It is normal in appearance (uniformly hypoechoic) and shape with no evidence of a mass effect.

The right adrenal gland is normal in size measuring 0.75 cm at the cranial pole and 0.72 cm at the caudal pole. It is observed in its normal position between the cranial aspect of the right kidney and the caudal vena cava. It is normal in appearance (uniformly hypoechoic) and shape with no evidence of a mass effect.

**Spleen**

The spleen is surgically absent.

**Liver**

The liver is subjectively normal in size, and echogenicity with smooth peripheral margins. The parenchyma is mildly heterogenous in echotexture with subtle, indistinct focal mottling. The visible portions of the vasculature and biliary tract appear normal. No focal nodules or cystic lesions are observed.

The gall bladder lumen is moderately distended. The wall of the gall bladder is not thickened and has a smooth mucosal surface. Luminal contents are mild and likely incidental at this time. The cystic and common bile ducts are normal/not visible.



**PATIENT**

Faith Fleming

**SPECIES**

Canine

**BREED**

Australian Blue Heeler

**SEX**

Spayed Female

**AGE**

8 Years 11 Months

**WEIGHT**

48.7 lbs

**INTERPRETED BY**

Kathleen Sennello DVM,  
 MS, Diplomate ACVIM  
 (Small Animal Internal  
 Medicine)

**IMAGING PERFORMED BY**

Kathleen Byrnes

**HOSPITAL NAME**

Harmony Heights  
 Animal Hospital

**REFERRING VET**

Dr. Sechrist

**INVOICE**

72934

**DATE**

2/12/26

***Gastrointestinal***

The stomach contains minimal luminal contents. It measures at a normal thickness of <0.7cm with some variability due to the presence of rugal folds. The distinction of the gastric wall layers is adequate and there is no impression of reduced peristaltic activity. No masses or focal lesions were observed.

The visualized areas of duodenum, jejunum and ileum have a relatively uniform diameter with minimal fluid distension. Wall thickness is normal. Bowel loops follow a curvilinear path with distinct wall layering maintaining the typical 1:3 muscularis:mucosa layer ratio. Jejunum wall measures 0.26 cm. Visualized peristalsis appears appropriate. There were no focal lesions consistent with obstruction or a mass effect observed.

Sections of colon are visualized with formed fecal material and gas shadowing distally. There is no observed focal or generalized colon wall thickening or loss of layering.

***Pancreas***

The area of the pancreas is normal and isoechoic to surrounding mesentery. There is no evidence of nodules or cystic lesions. There is no evidence of regional mesenteric inflammation or fluid.

***Free Abdomen***

Evaluation of the peritoneal cavity did not reveal any evidence of effusion. No significant lymphadenopathy noted. The omentum is hyperechoic around the right abdominal mass lesion.

***Other***

In the caudal right aspect of the abdomen there is a hypoechoic, heterogeneous, somewhat cystic/cavitated mass effect possibly associated with the body wall (?), measuring 11.64 cm x 6.99 cm.

The right auricle and pericardium were visualized and were unremarkable. No obvious pathology is visualized. If cardiac function evaluation is desired a full echocardiogram is warranted.

**ULTRASONOGRAPHIC FINDINGS**

- Surgically absent spleen (previously diagnosed with hemangiosarcoma).
- Mildly heterogeneous liver – The diffuse hepatic changes are non-specific and could be consistent with vacuolar hepatopathy, nodular hyperplasia, inflammatory/immune-mediated disease, fibrosis, extramedullary hematopoiesis, toxic hepatopathy (e.g., copper), infiltrative neoplasia (less likely) or other hepatopathy.
- Hypoechoic, heterogeneous, cystic/cavitated mass effect in the right abdomen – The appearance is concerning for a possible metastatic lesion. Recommend a fine needle aspirate.

**INTERPRETATION OF THE FINDINGS & FURTHER RECOMMENDATIONS**

The right mass effect is suspected to be associated with the body wall. A contrast CT scan would likely be necessary to definitively determine its location. Recommend a fine needle aspirate with a fine gauge needle for cytologic evaluation. Based on the history provided, the primary differential would be metastatic hemangiosarcoma, but other differentials are possible.



**PATIENT**

Faith Fleming

**SPECIES**

Canine

**BREED**

Australian Blue Heeler

**SEX**

Spayed Female

**AGE**

8 Years 11 Months

**WEIGHT**

48.7 lbs

**INTERPRETED BY**

Kathleen Sennello DVM,  
 MS, Diplomate ACVIM  
 (Small Animal Internal  
 Medicine)

**IMAGING  
 PERFORMED BY**

Kathleen Byrnes

**HOSPITAL NAME**

Harmony Heights  
 Animal Hospital

**REFERRING VET**

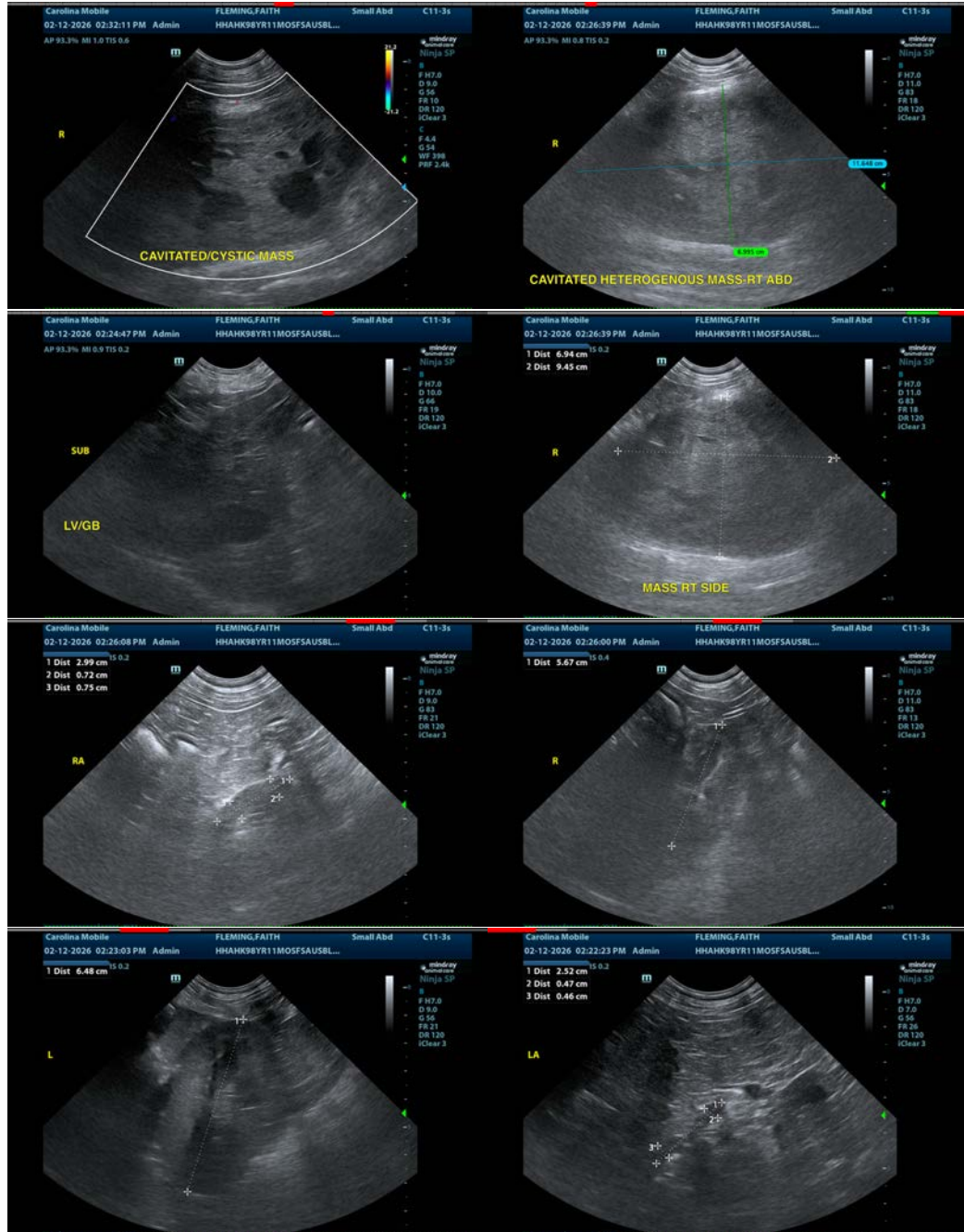
Dr. Sechrist

**INVOICE**

72934

**DATE**

2/12/26



The information and recommendations provided are based on the images presented by the referring veterinarian/sonographer. No evaluation can be communicated regarding pathology that was not visible in the image/video clips provided.

Thank you for this referral. If the clinical or image interpretation does not parallel your findings or if I can be of any further assistance please contact me.

Kathleen Sennello DVM,MS, Diplomate ACVIM (Small animal Internal Medicine) info@sonopath.com