

**DATE PRESENTING CLINICAL SIGNS**

2/11/22

PATIENT

History: Vomiting clear liquid, decreased app., 12/11/21 treated with fluids, Cerenia & Convenia. 1/28/22 Temp. 103 bloated belly, distended abdomen, fluid filled abdomen upon x ray. Abd. tap was done, fluid sent in for culture and cytology. Sent home on meds.

Sylvester Brady

SPECIES

Current Medications: Mirataz ear gel SID, Lasix 10 mg BID, Prednisolone 5 mg BID (All Started 1/28/22).

Lab Results: Cytology results suspicious for neoplasia. Attached separately.

Radiographs: Attached separately.

Feline

Date of Previous IntraPet Ultrasound: No previous IntraPet scans.

Sedation: Not required to complete full diagnostic ultrasound.

BREED

Stat Report: Not requested.

DSH

Imaging Performed By: Stephanie Pearce RDCS, RVT.

SEX**ULTRASONOGRAPHIC EXAMINATION OF THE ABDOMEN**

Neutered Male

Urinary System

The urinary bladder is moderately distended with anechoic urine. The Bladder wall, trigone, ureteral papillae and visible urethra (to a depth of 2cm) appear normal with no evidence of wall thickening, mucosal irregularities, masses or cystic calculi.

2/7/08

The left kidney has a normal shape and size (4.66 cm). Overall echogenicity is normal with adequate corticomedullary distinction and a typical 1:3 cortex:medulla ratio. There is no evidence of perinephric inflammation. There is no evidence of pyelectasia, nephroliths, infarcts or hydroureter. Renal vasculature is normal.

WEIGHT

2/7/08

The right kidney has a normal shape and size (4.84 cm). Overall echogenicity is normal with adequate corticomedullary distinction and a typical 1:3 cortex:medulla ratio. There is no evidence of perinephric inflammation. There is no evidence of pyelectasia, nephroliths, infarcts or hydroureter. Renal vasculature is normal.

INTERPRETED BY

Kathleen Sennello DVM,
MS, Diplomate ACVIM
(Small Animal Internal
Medicine)

Adrenal Glands

The left adrenal gland is normal in size measuring 0.63 cm at the caudal pole. It is observed in its normal position cranial to the left renal artery. It is normal in appearance (uniformly hypoechoic) and shape with no evidence of a mass effect.

HOSPITAL NAME

Animal Medical Clinic
of Dulaney Valley

The region of the right adrenal (between right cranial kidney and vena cava) is unremarkable, but the adrenal is not distinctly visualized. No evidence of a mass effect.

REFERRING VET

Dr. Chrest

Spleen

The spleen is subjectively normal in size, echotexture is homogenous, and the splenic capsule is smooth with no irregularities. The blood flow through the hilus and splenic parenchyma appears normal. No focal parenchymal abnormalities are visualized.

INVOICE

13900

Liver

The liver is subjectively large in size with smooth peripheral margins. The parenchyma is hyperechoic and homogenous in echotexture. The visible portions of the vasculature and biliary tract appear normal. No focal nodules or cystic lesions are observed.

The gall bladder lumen is moderately distended. The wall of the gall bladder is not thickened and has a smooth mucosal surface. Luminal contents are primarily anechoic. The cystic and common bile ducts are normal/not visible.

Gastrointestinal

The stomach is moderately dilated with fluid and irregular shadowing material most consistent with mild ingesta and gas. It measures at a normal thickness of <0.36 cm with some variability due to the presence of rugal folds. The distinction of the gastric wall layering is adequate and there is no impression of reduced peristaltic activity. No masses or focal lesions were observed.

The visualized areas of duodenum, jejunum and ileum have a relatively uniform diameter with minimal fluid distension. Wall thickness is normal. Bowel loops follow a curvilinear path with distinct wall layering maintaining the typical 1:3 muscularis:mucosa layer ratio. The jejunum measured as normal (0.35 cm). Visualized peristalsis appears appropriate. There were no focal lesions consistent with obstruction or a mass effect observed.

The colon is visible with shadowing fecal material within the lumen. There is a distinct shadowing area of bowel contained within the accumulation of abnormal mid abdominal tissue, most consistent with normal colon. There is a direct association with this abnormal tissue, but no distinct colonic mass effect is observed.

Pancreas

The pancreas is difficult to clearly visualize. The mesentery is severely irregular and inflamed with surrounding fluid. There is an adhered ball of abnormal tissue in the mid abdomen, which I suspect has an irregular hypoechoic pancreas contained within these tissues, but it cannot be distinctly delineated from the other abnormal tissue. The findings are concerning for severe pancreatitis or pancreatic neoplasia.

Free Abdomen

There is a large volume of somewhat echogenic fluid. No lymphadenomegaly visualized. In the mid abdomen, there is a very large accumulation of what appears to be adhered, irregular, mixed echogenicity, almost nodular omentum. Within this area, I suspect, is the pancreas, colon and some sections of bowel. The omentum is very abnormal with surrounding fluid- the findings are most consistent with peritonitis.

Other

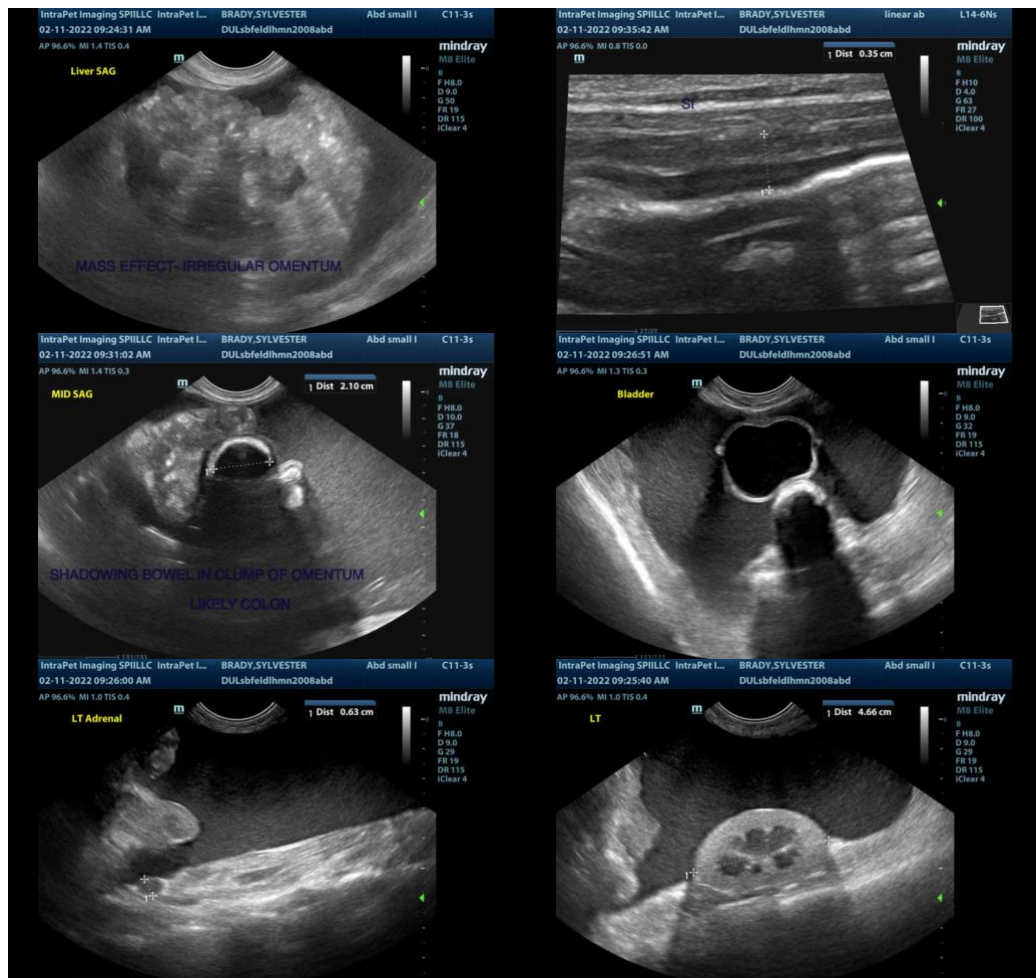No significant pericardial effusion.

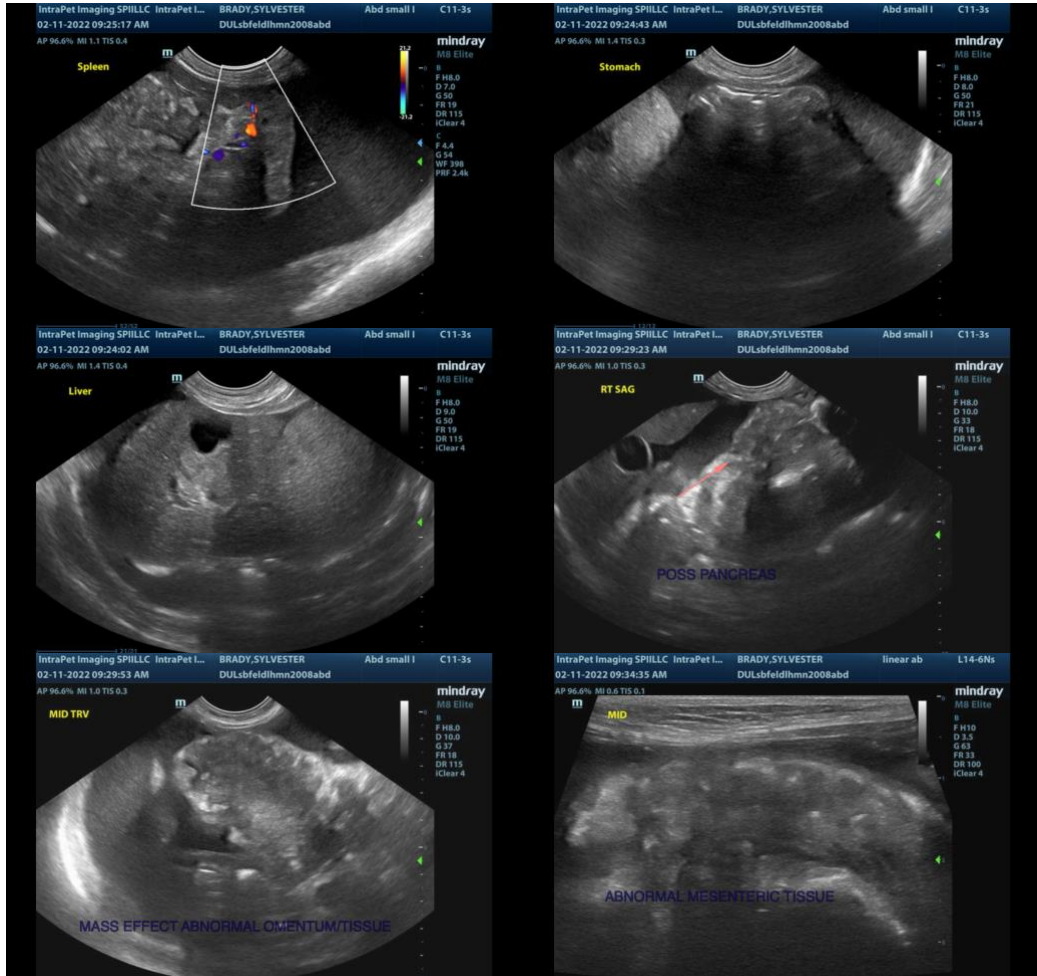
ULTRASONOGRAPHIC FINDINGS

- Focal accumulation of severely abnormal mesentery containing colon, likely abnormal pancreas, etc. Findings are most consistent with a mass effect and secondary peritonitis (likely sterile). This could represent adhered, inflammatory tissue or a neoplastic process.
- Large hyperechoic liver. Hepatic changes are non-specific and could be consistent with hepatic lipidosis, inflammatory/infectious disease, infiltrative neoplasia, or other hepatopathy.
- Suspect severe pancreatitis. While I cannot distinctly delineate the pancreas in the mass effect, I see glimpses of what appear to be a large hypoechoic irregular pancreas.

INTERPRETATION OF THE FINDINGS & FURTHER RECOMMENDATIONS

There is a large volume of echogenic fluid with a large mid abdominal mass effect, which appears to be very abnormal, inflamed almost nodular mesentery, the colon, abnormal pancreas, etc. This could represent a primary neoplasm of either the mesentery, pancreas, etc. and secondary peritonitis or this could represent a primary inflammatory lesion with adhesions, peritonitis, etc. Fluid analysis was submitted, which does identify some atypical cells. Moving forward, options include a fine needle aspirate of the mass effect, possibly a CT scan of the abdomen, three-view thoracic radiographs (if not already done), and you could even consider exploratory surgery to try and evaluate this mass effect, break down adhesions and obtain biopsies. Prognosis is guarded.





The information and recommendations provided are based on the images presented by the referring veterinarian. No evaluation can be communicated regarding pathology that was not visible in the image/video clips provided.

Thank you for this referral. If the clinical or image interpretation does not parallel your findings or if I can be of any further assistance please contact me.

Kathleen Sennello DVM,MS, Diplomate ACVIM (Small animal Internal Medicine)
 kathleen.sennello@sonopath.com