

**DATE**

2/11/22

PRESENTING CLINICAL SIGNS

History: Hx hyporexia, weight loss over 4 weeks, jaundice. PE: Severe icterus, dorsal muscle wasting, dehydrated.

Current Medications: Convenia on 1/28/22, Mirtaz gel SID, Prednisolone 5 mg PO SID.

Lab Results: 1/28/22: HCT 40%, WBC 25K, neutro 23K, USG >1.050, inactive sediment, ALT 970 ALP 480, tBili 16, GGT 22.

Radiographs: TXR pending.

Date of Previous IntraPet Ultrasound: No previous IntraPet scans.

Sedation: Not required to complete full diagnostic ultrasound.

Stat Report: Not requested.

Imaging Performed By: Andi Parkinson, RDMS.

PATIENT

Oscar Hackett

SPECIES

Feline

BREED

Domestic Shorthair

SEX

Neutered male

AGE

7/1/08

WEIGHT

12.9 lbs

INTERPRETED BY

Kathleen Sennello
DVM, MS, Diplomate
ACVIM (Small Animal
Internal Medicine)

ULTRASONOGRAPHIC EXAMINATION OF THE ABDOMEN**Urinary System**

The urinary bladder is moderately distended with anechoic urine. The Bladder wall, trigone, ureteral papillae and visible urethra (to a depth of 2cm) appear normal with no evidence of wall thickening, mucosal irregularities, masses or cystic calculi.

The left kidney has a normal shape and size (4.8 cm). Overall echogenicity is normal with adequate corticomedullary distinction and a typical 1:3 cortex:medulla ratio. There is no evidence of perinephric inflammation or effusion. There is no evidence of pyelectasia, nephroliths, infarcts or hydroureter. Renal vasculature is normal.

The right kidney has a normal shape and size (4.7 cm). Overall echogenicity is normal with adequate corticomedullary distinction and a typical 1:3 cortex:medulla ratio. There is no evidence of perinephric inflammation or effusion. There is no evidence of pyelectasia, nephroliths, infarcts or hydroureter. Renal vasculature is normal.

Adrenal Glands

The region of left adrenal (Cranial to left renal artery) is unremarkable but the adrenal is not distinctly visualized. No evidence of a mass effect.

The region of the right adrenal (between right cranial kidney and vena cava) is unremarkable, but the adrenal is not distinctly visualized. No evidence of a mass effect.

HOSPITAL NAME

Timonium AH

Spleen

The normal splenic parenchyma is small and appears somewhat hypovolemic. There are two large hyperechoic, rounded mass effects in the region of the spleen, which appear to be arising from the spleen. The smaller, more distal nodule measures 1.2 x 0.84 cm. The second larger hyperechoic nodule measures 2.5 x 1.51 cm.

REFERRING VET

Dr. Kauder

INVOICE

96023

Liver

The liver is subjectively normal in size, and echogenicity with smooth peripheral margins. The parenchyma is heterogenous in echotexture with subtle, indistinct focal mottling. No focal nodules or cystic lesions are observed. The gallbladder is distended with mildly echogenic liquid bile. The bile duct is severely tortuous and distended and approximately measured 0.5 cm in diameter and it can be followed to the level of the duodenal papilla where it measures 0.94 cm in diameter. The findings are most consistent with an obstruction at the level of the duodenal papilla with either severely inflamed pancreatic tissue or a pancreatic or duodenal mass effect.

Gastrointestinal

The stomach contains minimal luminal contents. It measures at a normal thickness of <0.36cm with some variability due to the presence of rugal folds. The distinction of the gastric wall layers is adequate and there is no impression of reduced peristaltic activity. No masses or focal lesions were observed.

The visualized areas of duodenum, jejunum and ileum have a relatively uniform diameter with minimal fluid distension. Wall thickness is normal. Bowel loops follow a curvilinear path with distinct wall layering maintaining the typical 1:3 muscularis:mucosa layer ratio. The jejunum measured as normal (between 0.15-0.36cm.) Visualized peristalsis appears appropriate. The duodenum at the level of the duodenal papilla appears thickened and abnormal. The wall thickness in that area is 0.48 cm with decreased detailed wall layering. The findings are most consistent with either focal duodenitis secondary to pancreatitis or a duodenal mass at the level of the duodenal papilla causing a biliary obstruction.

The ileocecal junction was visualized and exhibited normal intact wall layering and is subjectively of normal thickness. Sections of colon are visualized with formed fecal material and gas shadowing distally. There is no observed focal or generalized colon wall thickening or loss of layering.

Pancreas

The pancreas is large and hypoechoic to surrounding mesentery. In the area of the duodenal papilla near the right limb of the pancreas there is a focal, ill-defined, hypoechoic mass effect that is surrounded by hyperechoic mesentery. This area is most consistent with an area of focal severe pancreatitis or duodenal or pancreatic mass. This area obstructs the common bile duct. This is consistent with severe pancreatitis and/or possible pancreatic neoplasia.

Free Abdomen

Evaluation of the peritoneal cavity did not reveal any evidence of effusion, or subjective lymphadenomegaly. The Medial iliac nodes appear normal and there was no evidence of a caudal aortic thrombus at the bifurcation. The omentum is severely hyperechoic particularly in the area around the pancreas.

ULTRASONOGRAPHIC FINDINGS

PRIMARY FINDINGS:

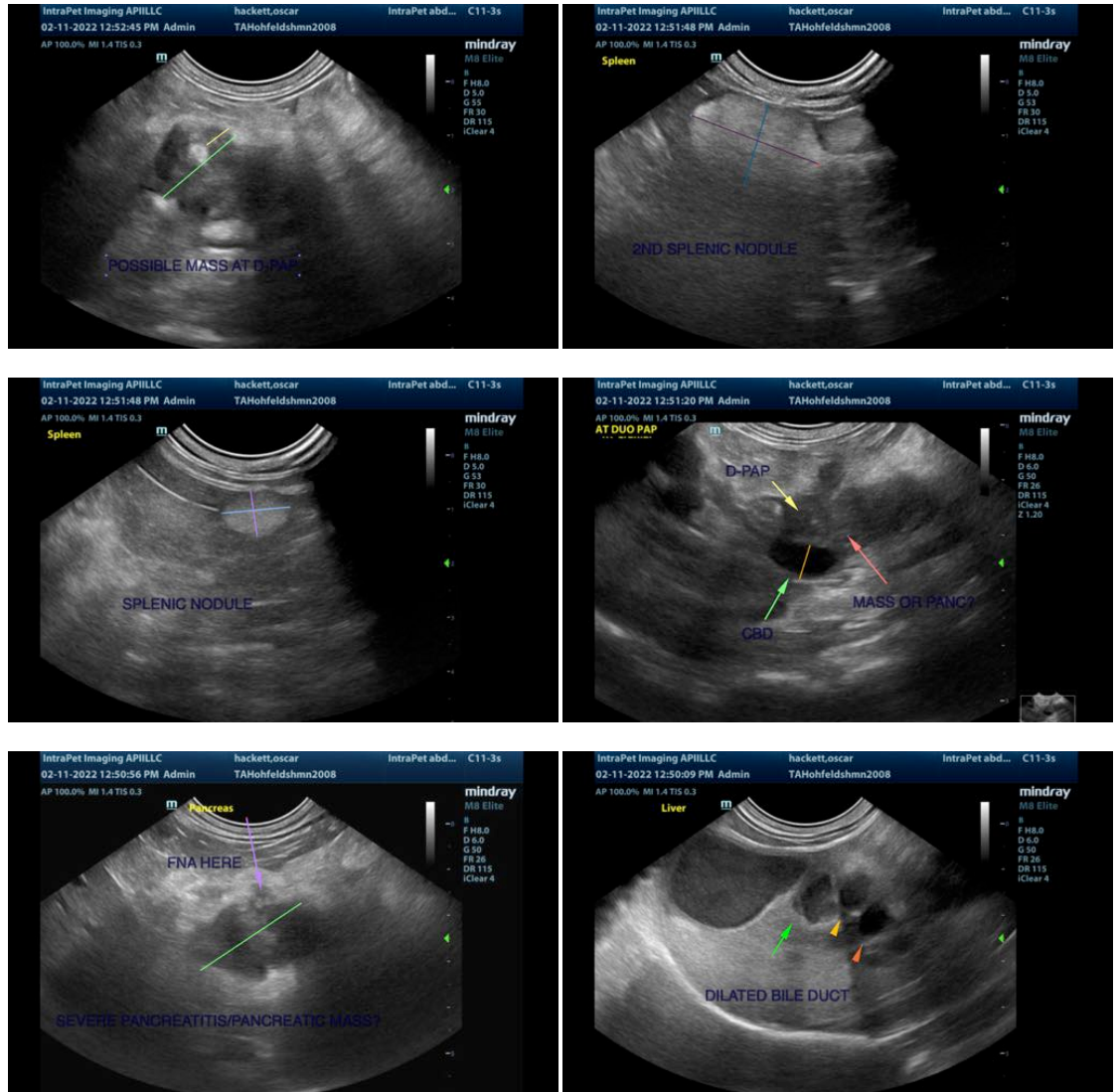
- There is severe pancreatic disease present along with a biliary obstruction. The bile duct can be followed to the level of the duodenal papilla where it ends at an area of focal, hypoechoic, irregular tissue surrounded by hyperechoic mesentery. These changes are most consistent with either severe focal pancreatitis causing a biliary obstruction and duodenitis/focal peritonitis or with a mass effect (either pancreatic or duodenal) causing an obstruction.

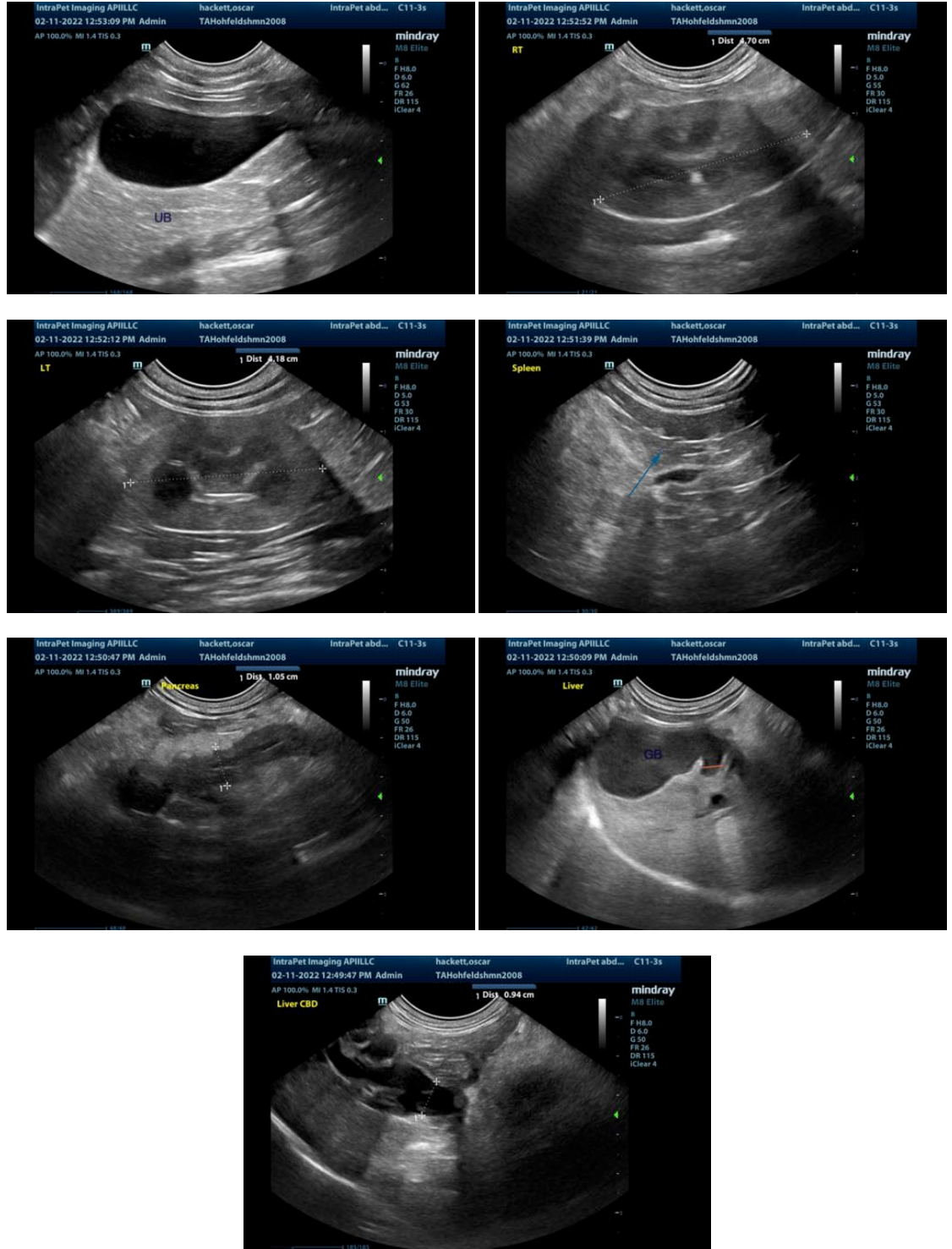
INTERPRETATION OF THE FINDINGS & FURTHER RECOMMENDATIONS

If ample time has been given for the current treatment to take effect and there has been no response then consider either a FNA of the abnormal tissue in the area of the termination of the common bile duct (in the area of the duodenal papilla) or consider exploratory surgery +/- preoperative CT scan to further evaluate the area. Cats with bilirubin this high are at high risk under anesthesia so if this can be approached non-invasively or with a short surgical procedure (possible stent placement?) then the prognosis may be better. The most conservative approach possible would be treatment for pancreatitis and more time on steroid therapy, but the prognosis is guarded.

Consider three view thoracic radiographs to rule out concurrent thoracic disease/involvement.

Ensure normal coagulation parameters before considering any invasive procedures. Consider starting Vitamin K therapy and giving a plasma transfusion. Additionally there are two atypical lesions in the area of the spleen. They may be arising from the spleen or just in an area in contact with the spleen. Consider a FNA of these hyperechoic lesions.





The information and recommendations provided are based on the images presented by the referring veterinarian. No evaluation can be communicated regarding pathology that was not visible in the image/video clips provided.

Thank you for this referral. If the clinical or image interpretation does not parallel your findings or if I can be of any further assistance please contact me.

Kathleen Sennello DVM,MS, Diplomate ACVIM (Small animal Internal Medicine)
kathleen.sennello@sonopath.com