

**DATE**

2/11/22

PRESENTING CLINICAL SIGNS

Presenting Complaint: Dehydrated / Lethargic / Anemia.

History: Date: 02-09-2022 Notes: Patient was seen by RDVM today for being sluggish since yesterday. Was worse this morning. Went to RDVM, was diagnosed with AG infection and enlarged prostate (possibly BPH since intact). Was given Convenia injection and full bloodwork was sent to reference lab, in house cPL was normal per owner. Patient also had xrays that were unremarkable per owner. Patient was still very lethargic through the afternoon and owner noticed when he urinated, it was bright orange. Owner called RDVM, who checked PCV and told them patient was anemic and they should go to ER ASAP for further care.

Assessments: Lethargy, probable bilirubinuria, anemia, suspect IMHA.

Current Medications: Prednisone Tablets 20mg, Sucralfate Tablets 1gm, Famotidine Tablets 10mg, Doxycycline Suspension 100mg/ml, Mycophenolate Suspension 100mg/mL, Prednisone Tablets 5mg, and Dexamethasone SP 4mg/mL Injection (Per mL).

Lab Results: Attached.

Date of Previous IntraPet Ultrasound: No previous.

Sedation: Not required to complete full diagnostic ultrasound.

Stat Report: Not requested.

Imaging Performed By: Rachel Brillhart, RDMS.

PATIENT

Andy Buck

SPECIES

Canine

BREED

Shih Tzu Mix

SEX

Intact male

AGE

2020

WEIGHT

17.4 lbs

ULTRASONOGRAPHIC EXAMINATION OF THE ABDOMEN**Urinary System**

The urinary bladder is moderately distended with anechoic urine. The bladder wall, trigone, ureteral papillae and visible urethra (to a depth of 2cm) appear normal with no evidence of wall thickening, mucosal irregularities, masses or cystic calculi.

The prostate is large and measured 2.5 cm in height on the sagittal view and is hyperechoic. No discrete focal lesions are present. The prostatic urethra appears normal with no evidence of irregularity, invasion, mass effect or calculi. Both testicles are visualized and appear within normal limits.

INTERPRETED BY

Kathleen Sennello
DVM, MS, Diplomate
ACVIM (Small Animal
Internal Medicine)

The left kidney has a normal shape and size (4.83 cm). Overall echogenicity is normal with adequate corticomedullary distinction and a typical 1:3 cortex:medulla ratio. There is no evidence of perinephric inflammation or effusion. There is no evidence of pyelectasia, nephroliths, infarcts or hydroureter. Renal vasculature is normal.

The right kidney has a normal shape and size (4.61 cm). Overall echogenicity is normal with adequate corticomedullary distinction and a typical 1:3 cortex:medulla ratio. There is no evidence of perinephric inflammation or effusion. There is no evidence of pyelectasia, nephroliths, infarcts or hydroureter. Renal vasculature is normal.

HOSPITAL NAME

Animal Emergency
Hospital

Adrenal Glands

The left adrenal gland is normal in size measuring 0.46 cm at the caudal pole It is observed in its normal position cranial to the left renal artery. It is normal in appearance (uniformly hypoechoic) and shape with no evidence of a mass effect.

REFERRING VET

Dr. Martinoli

INVOICE

95995

The right adrenal gland is normal in size measuring 0.43 cm at the caudal pole It is observed in its normal position between the cranial aspect of the right kidney and the caudal vena cava. It is normal in appearance (uniformly hypoechoic) and shape with no evidence of a mass effect.

Spleen

The spleen is subjectively large in size. The spleen echotexture is heterogenous and mottled, the splenic capsule is smooth with no irregularities. The blood flow through the hilus and splenic parenchyma appears normal. There are no focal lesions visualized, but the spleen folds over itself in the abdomen.

Liver

The liver is subjectively normal in size, and echogenicity with smooth peripheral margins. The parenchyma is homogenous echotexture. The visible portions of the vasculature and biliary tract appear normal. No focal nodules or cystic lesions are observed. The gallbladder lumen is moderately distended. The wall of the gallbladder is not thickened and has a smooth mucosal surface. Luminal contents are primarily anechoic. The cystic and common bile ducts are normal/not visible.

Gastrointestinal

The stomach contains minimal luminal contents. It measures at a normal thickness of <0.7cm with some variability due to the presence of rugal folds. The distinction of the gastric wall layers is adequate and there is no impression of reduced peristaltic activity. No masses or focal lesions were observed.

The visualized areas of duodenum, jejunum and ileum have a relatively uniform diameter with minimal fluid distension. Wall thickness is normal. Bowel loops follow a curvilinear path with distinct wall layering maintaining the typical 1:3 muscularis:mucosa layer ratio. The duodenum measured as normal (between 0.3-0.5cm in wall thickness) and the jejunum measured as normal (between 0.2-0.47cm.) Visualized peristalsis appears appropriate. There were no focal lesions consistent with obstruction or a mass effect observed.

The ileocecal junction was visualized and exhibited normal intact wall layering and is subjectively of normal thickness. Sections of colon are visualized with formed fecal material and gas shadowing distally. There is no observed focal or generalized colon wall thickening or loss of layering.

Pancreas

The pancreas is normal and isoechoic to surrounding mesentery. There is no evidence of nodules or cystic lesions. There is no evidence of regional mesenteric inflammation or fluid.

Free Abdomen

Evaluation of the peritoneal cavity did not reveal any evidence of effusion, or subjective lymphadenomegaly. The Medial iliac nodes appear normal and there was no evidence of a caudal aortic thrombus at the bifurcation. The omentum is of normal uniform echogenicity.

ULTRASONOGRAPHIC FINDINGS

PRIMARY FINDINGS:

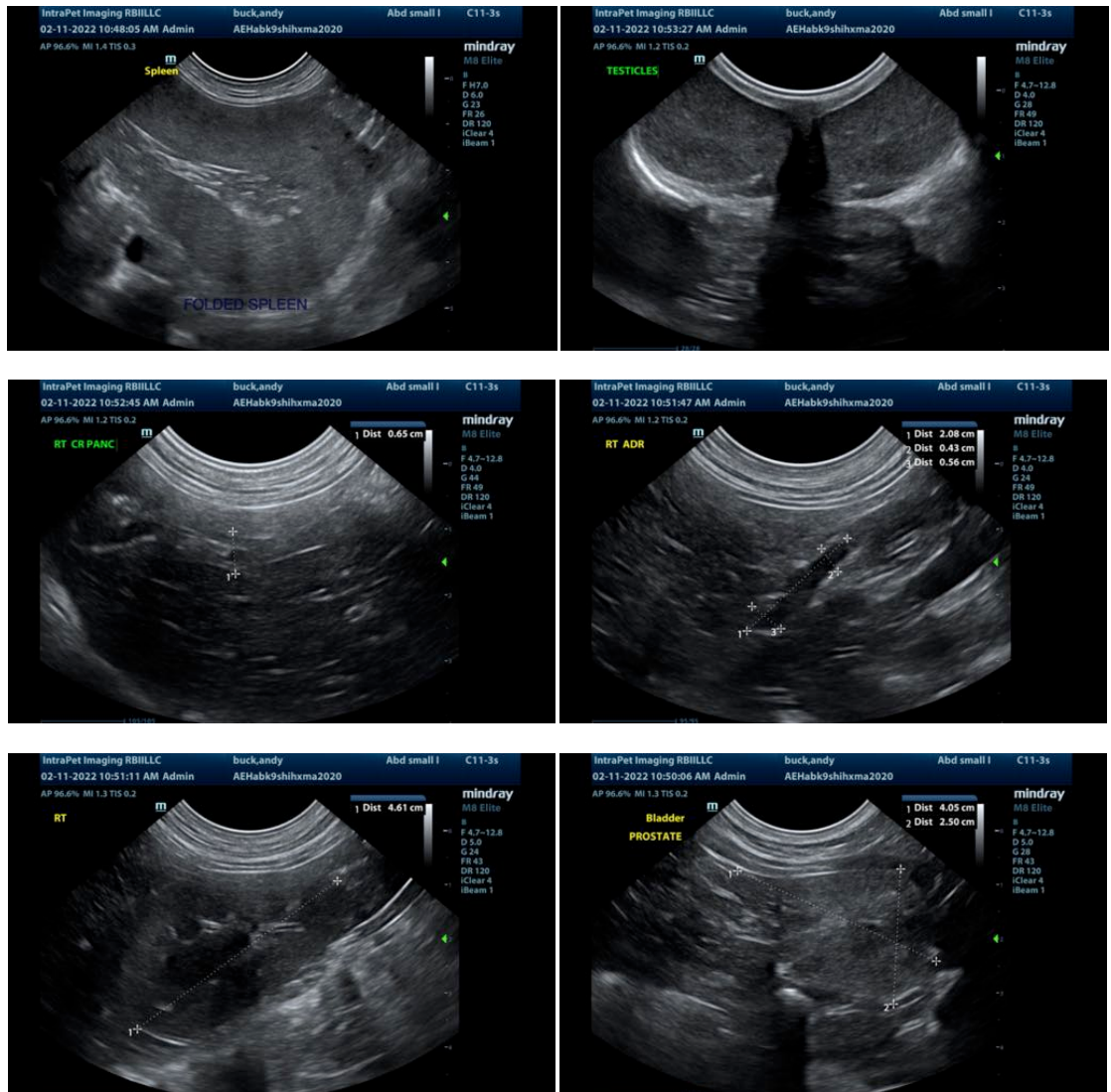
- Large, mottled folded spleen. The diffuse splenic changes are non-specific and could be consistent with lymphoid hyperplasia, extramedullary hematopoiesis, infiltrative neoplasia, inflammation, other. Cytology or histopathology would be necessary to get a definitive diagnosis.
- Hyperechoic, large prostate. Prostatic changes are most consistent with benign prostatic hyperplasia. Other differentials include bacterial prostatitis and prostatic neoplasia. However, given the lack of lower urinary tract symptoms, these differentials are considered less likely in this patient.

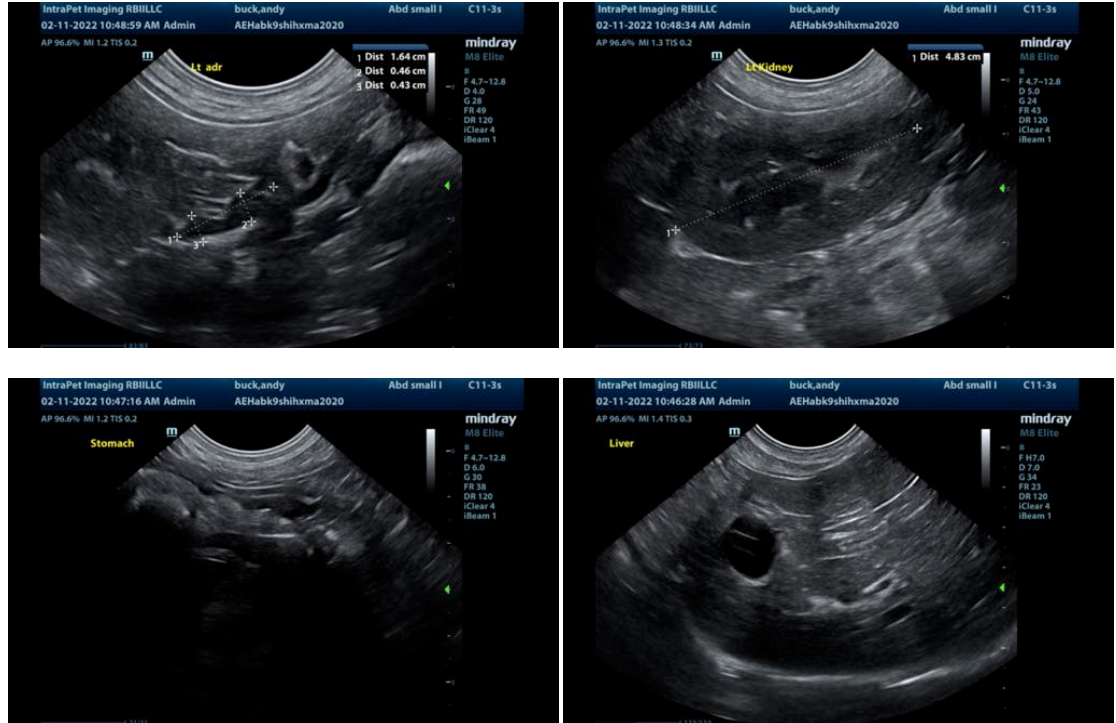
INTERPRETATION OF THE FINDINGS & FURTHER RECOMMENDATIONS

There is no evidence of a bowel lesion or free fluid in the abdomen. There is no evidence of lymphadenomegaly or mass effects. The spleen is somewhat large and mottled. This is a non-specific finding that could be normal in this patient or could be consistent with regeneration or hemolysis.

Based on lab work a slide agglutination test, pathologist review of the blood smear with reticulocyte count, etc. you can try and determine if this is a non-regenerative or regenerative anemia, determine the severity of the anemia and look for evidence of spherocytes, autoagglutination, etc. which can be an indicator of autoimmune disease versus other causes of hemolysis (zinc toxicity, intracellular parasites, etc.). There are no lesions observed to explain the anemia present. If there is a strong suspicion of round cell neoplasia based on your test results, a FNA of the spleen can be considered.

Recommend three view thoracic radiographs.





The information and recommendations provided are based on the images presented by the referring veterinarian. No evaluation can be communicated regarding pathology that was not visible in the image/video clips provided.

Thank you for this referral. If the clinical or image interpretation does not parallel your findings or if I can be of any further assistance please contact me.

Kathleen Sennello DVM,MS, Diplomate ACVIM (Small animal Internal Medicine)
 kathleen.sennello@sonopath.com