

PATIENT

Kairos De Soto

SPECIES

Canine

BREED

Lab Mix

SEX

Spayed Female

AGE

7 years 1 month

WEIGHT

57.6

INTERPRETED BY

Kathleen Sennello DVM,
MS, Diplomate ACVIM
(Small Animal Internal
Medicine)

IMAGING PERFORMED BY

Dr. Sarah Green

HOSPITAL NAME

Healing Spirit Animal
Wellness

REFERRING VET

Dr. Sarah Green

INVOICE

11277

DATE

2/10/2026

PRESENTING CLINICAL SIGNS

- History of enterotomies in June and July 2025 to remove foreign bodies from the mid jejunum (nectarine pit) and proximal duodenum (rubber toy), respectively. Ongoing lip smacking and excessive play bow/ downward dog stretching as reported at the time of previous scan in November 2025. No vomiting or loss of appetite, bowel movements are reported to be of regular frequency, normal diameter and consistency.

Abnormal PE/Chem/CBC/UA Results: No abnormal findings.

ULTRASONOGRAPHIC EXAMINATION OF THE ABDOMEN

Urinary System

The urinary bladder is moderately distended with anechoic urine. The Bladder wall, trigone, ureteral papillae and visible urethra (to a depth of 2cm) appear normal with no evidence of wall thickening, mucosal irregularities, masses or cystic calculi.

The left kidney has a normal shape and size (5.65 cm). Overall echogenicity is normal with adequate corticomedullary distinction and a typical 1:3 cortex:medulla ratio. There is no evidence of focal perinephric inflammation or effusion. There is no evidence of pyelectasia, nephroliths, infarcts or hydroureter. Renal vasculature is normal.

The right kidney has a normal shape and size (5.69 cm). Overall echogenicity is normal with adequate corticomedullary distinction and a typical 1:3 cortex:medulla ratio. There is no evidence of focal perinephric inflammation or effusion. There is no evidence of pyelectasia, nephroliths, infarcts or hydroureter. Renal vasculature is normal.

Adrenal Glands

The region of left adrenal (Cranial to left renal artery) is unremarkable but the adrenal is not distinctly visualized. No evidence of a mass effect.

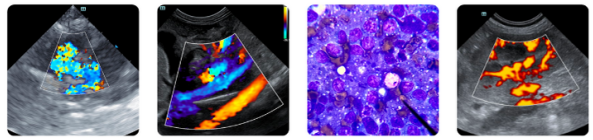
The right adrenal gland is normal in size measuring 0.57 cm at the cranial pole and 0.59 cm at the caudal pole. It is observed in its normal position between the cranial aspect of the right kidney and the caudal vena cava. It is normal in appearance (uniformly hypoechoic) and shape with no evidence of a mass effect.

Spleen

The spleen is subjectively normal in size (3.2 cm) and the echotexture is homogenous. The splenic capsule is smooth with no visible irregularities. The blood flow through the hilus and splenic parenchyma appears normal. No focal parenchymal abnormalities are visualized.

Liver

The liver is normal/borderline small in size, and echogenicity with smooth peripheral margins. The parenchyma is homogenous echotexture. The visible portions of the vasculature and biliary tract appear normal. No focal nodules or cystic lesions are observed.



PATIENT

Kairos De Soto

The gall bladder lumen is moderately distended. The wall of the gall bladder is not thickened and has a smooth mucosal surface. Luminal contents are mild and likely incidental at this time. The cystic and common bile ducts are normal/not visible.

SPECIES

Canine

Gastrointestinal

The stomach contains minimal luminal contents. It measures at a normal thickness of <0.7cm with some variability due to the presence of rugal folds. The distinction of the gastric wall layers is adequate and there is no impression of reduced peristaltic activity. No masses or focal lesions were observed.

BREED

Lab Mix

The visualized areas of duodenum, jejunum and ileum have a relatively uniform diameter with minimal fluid distension. Wall thickness is normal. Bowel loops follow a curvilinear path with distinct wall layering maintaining the typical 1:3 muscularis:mucosa layer ratio. The duodenum measured as normal (0.37 cm in wall thickness) and the jejunum measured as normal (0.32 cm.) Visualized peristalsis appears appropriate. There were no focal lesions consistent with obstruction or a mass effect observed.

SEX

Spayed Female

AGE

7 years 1 month

Sections of colon are visualized with formed fecal material and gas shadowing distally. There is no observed focal or generalized colon wall thickening or loss of layering.

WEIGHT

57.6

Pancreas

The area of the pancreas is normal and isoechoic to surrounding mesentery. There is no evidence of nodules or cystic lesions. There is no evidence of regional mesenteric inflammation or fluid.

INTERPRETED BY

Kathleen Sennello DVM,
MS, Diplomate ACVIM
(Small Animal Internal
Medicine)

Free Abdomen

Evaluation of the peritoneal cavity did not reveal any evidence of effusion, or subjective lymphadenomegaly. The Medial iliac nodes appear normal and there was no evidence of a caudal aortic thrombus at the bifurcation. The omentum is of normal uniform echogenicity.

IMAGING PERFORMED BY

Dr. Sarah Green

ULTRASONOGRAPHIC FINDINGS

- No significant ultrasonographic lesions visualized.

HOSPITAL NAME

Healing Spirit Animal
Wellness

INTERPRETATION OF THE FINDINGS & FURTHER RECOMMENDATIONS

No focal lesions were visualized associated with the GI tract on today's exam. This does not rule out the possibility of adhesions playing a role in this patient's discomfort as ultrasound can be relatively insensitive in visualization of these structures. There's no evidence of significant inflammation, free fluid, etc.

REFERRING VET

Dr. Sarah Green

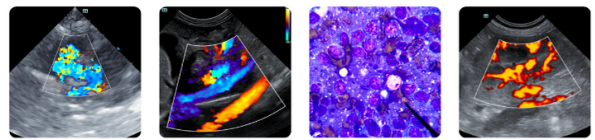
If patient discomfort is significant you could consider a contrast CT scan, or even exploratory to reevaluate.

INVOICE

11277

DATE

2/10/2026



PATIENT

Kairos De Soto

SPECIES

Canine

BREED

Lab Mix

SEX

Spayed Female

AGE

7 years 1 month

WEIGHT

57.6

INTERPRETED BY

Kathleen Sennello DVM,
MS, Diplomate ACVIM
(Small Animal Internal
Medicine)

IMAGING PERFORMED BY

Dr. Sarah Green

HOSPITAL NAME

Healing Spirit Animal
Wellness

REFERRING VET

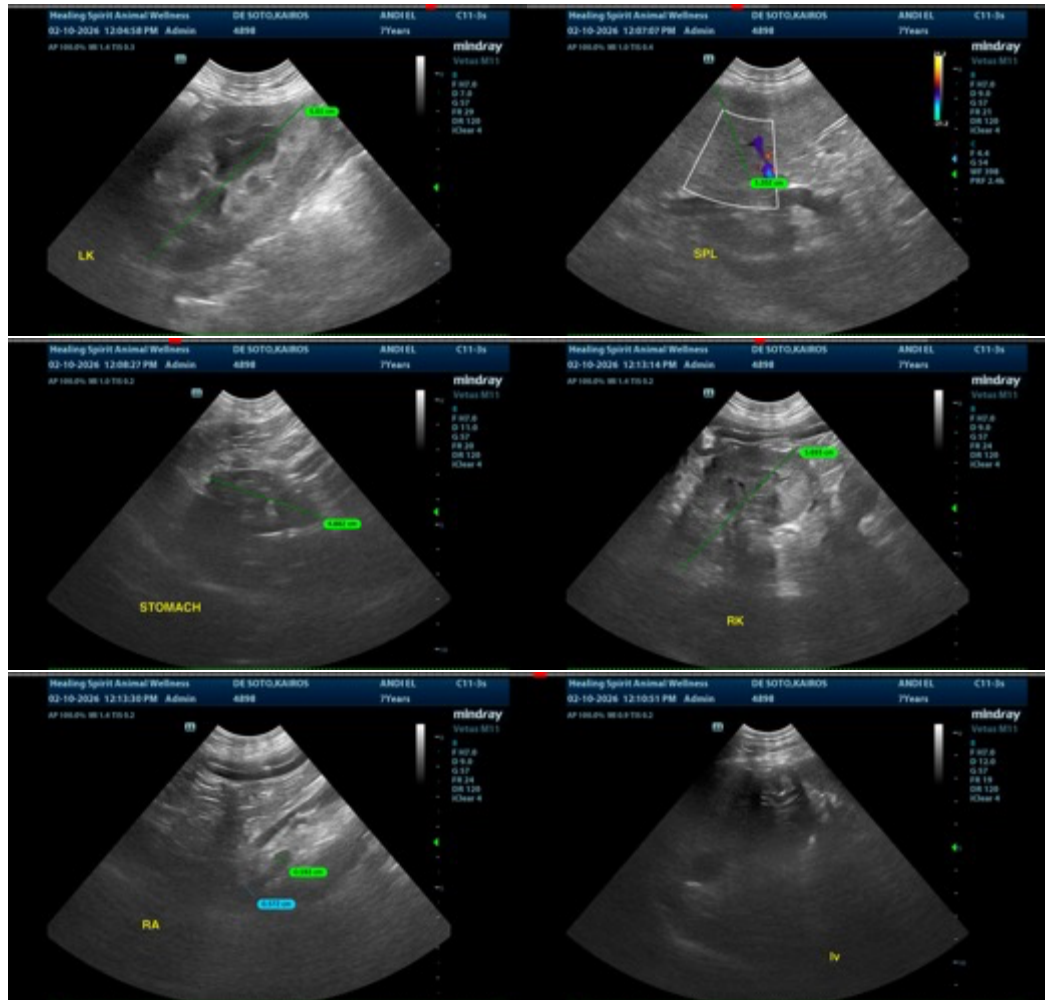
Dr. Sarah Green

INVOICE

11277

DATE

2/10/2026



The information and recommendations provided are based on the images presented by the referring veterinarian/sonographer. No evaluation can be communicated regarding pathology that was not visible in the image/video clips provided.

Thank you for this referral. If the clinical or image interpretation does not parallel your findings or if I can be of any further assistance please contact me.

Kathleen Sennello DVM,MS, Diplomate ACVIM (Small animal Internal Medicine)

info@sonopath.com