



DATE PRESENTING CLINICAL SIGNS

2/10/26 **Patient History:** Weight loss/ palpable abdominal mass.

PATIENT Current Medications: Mirataz.

Gidget Batton **Labwork Results:** Labwork attached. Rads- abdominal mass.

Date of Previous IntraPet Ultrasound: No previous.

Sedation: Not required to complete full diagnostic ultrasound.

Stat Report: Not requested.

SPECIES Imaging Performed by: Stephanie Warga RDCS, RVT.

Feline

ULTRASONOGRAPHIC EXAMINATION OF THE ABDOMEN

BREED *Urinary System*

DSH The urinary bladder is moderately distended with anechoic urine. The Bladder wall, trigone, ureteral papillae and visible urethra (to a depth of 2cm) appear normal with no evidence of wall thickening, mucosal irregularities, masses or cystic calculi.

SEX

Spayed Female

The left kidney is borderline small and irregular (likely due to previous infarcts), measuring 2.92 cm, with mild pyelectasia at 0.26 cm and occasional small cortical cysts. Overall echogenicity is slightly hyperechoic with poor corticomedullary distinction and a typical 1:3 cortex:medulla ratio. There is no evidence of focal perinephric inflammation or effusion. There is no evidence of nephroliths or hydroureter. Renal vasculature is normal.

AGE

7/7/07

WEIGHT

7.28 lbs

The right kidney is borderline small and irregular (likely due to previous infarcts), measuring 2.93 cm, with mild pyelectasia at 0.08 cm and occasional small cortical cysts. Overall echogenicity is slightly hyperechoic with poor corticomedullary distinction and a typical 1:3 cortex:medulla ratio. There is no evidence of focal perinephric inflammation or effusion. There is no evidence of nephroliths or hydroureter. Renal vasculature is normal.

INTERPRETED BY

Kathleen Sennello DVM,
MS, Diplomate ACVIM
(Small Animal Internal
Medicine)

Adrenal Glands

The left adrenal gland is normal in size measuring 0.39 cm at the caudal pole. It is observed in its normal position cranial to the left renal artery. It is normal in appearance (uniformly hypoechoic) and shape with no evidence of a mass effect.

HOSPITAL NAME

Chadwell Animal
Hospital

The right adrenal gland is normal in size measuring 0.43 cm at the caudal pole. It is observed in its normal position between the cranial aspect of the right kidney and the caudal vena cava. It is normal in appearance (uniformly hypoechoic) and shape with no evidence of a mass effect.

REFERRING VET

Dr. Gold

Spleen

The spleen is subjectively normal in size (0.62 cm), echotexture is homogenous, and the splenic capsule is smooth with no irregularities. The blood flow through the hilus and splenic parenchyma appears normal. No focal parenchymal abnormalities are visualized.

INVOICE

72855

Liver

The liver is subjectively normal in size, and echogenicity with smooth peripheral margins. The parenchyma is homogenous echotexture. The visible portions of the vasculature and biliary tract appear normal. No focal nodules or cystic lesions are observed.

The gall bladder lumen is moderately distended. The wall of the gall bladder is not thickened and has a smooth mucosal surface. Luminal contents are mild and likely incidental at this time. The cystic and common bile ducts are normal/not visible.

Gastrointestinal

The stomach contains minimal luminal contents. It measures at a normal thickness of <0.36cm with some variability due to the presence of rugal folds. The distinction of the gastric wall layers is adequate and there is no impression of reduced peristaltic activity. No masses or focal lesions were observed.

The visualized areas of duodenum, jejunum and ileum have a uniform diameter with minimal fluid distension. Wall thickness is increased. Bowel loops follow a typical curvilinear path. Some areas have reduced detail of wall layering. Jejunum wall measures 0.34 cm. Visualized peristalsis appears appropriate. The small intestine appears diffusely thickened with a severely thickened/prominent muscularis layer. In these areas the bowel measures up to 0.47 cm. Additionally, there is a focal section of small intestine with severe thickening at 0.51 cm and complete loss of layering, most consistent with a focal mass effect.

The ileocecal junction was visualized and exhibited normal intact wall layering and is subjectively of normal thickness. Sections of colon are visualized with formed fecal material and gas shadowing distally. There is no observed focal or generalized colon wall thickening or loss of layering.

Pancreas

The pancreas is prominent and hypoechoic as compared to the surrounding isoechoic mesentery. There is no evidence of nodules or cystic lesions. There is no evidence of regional mesenteric inflammation or fluid.

Free Abdomen

There is scant free fluid. There is a significant lymphadenopathy with a large, hypoechoic, irregular mass effect in the mid abdomen, most consistent with a large mesenteric lymph node measuring 2.32 cm x 4.83 cm. Additionally, there are large, hypoechoic, irregular lymph nodes adjacent to the ileocecal junction. Examples measure 1.36 cm x 1.4 cm and 0.47 cm x 0.66 cm. The omentum is hyperechoic around the enlarged lymph nodes and the focal bowel mass lesion.

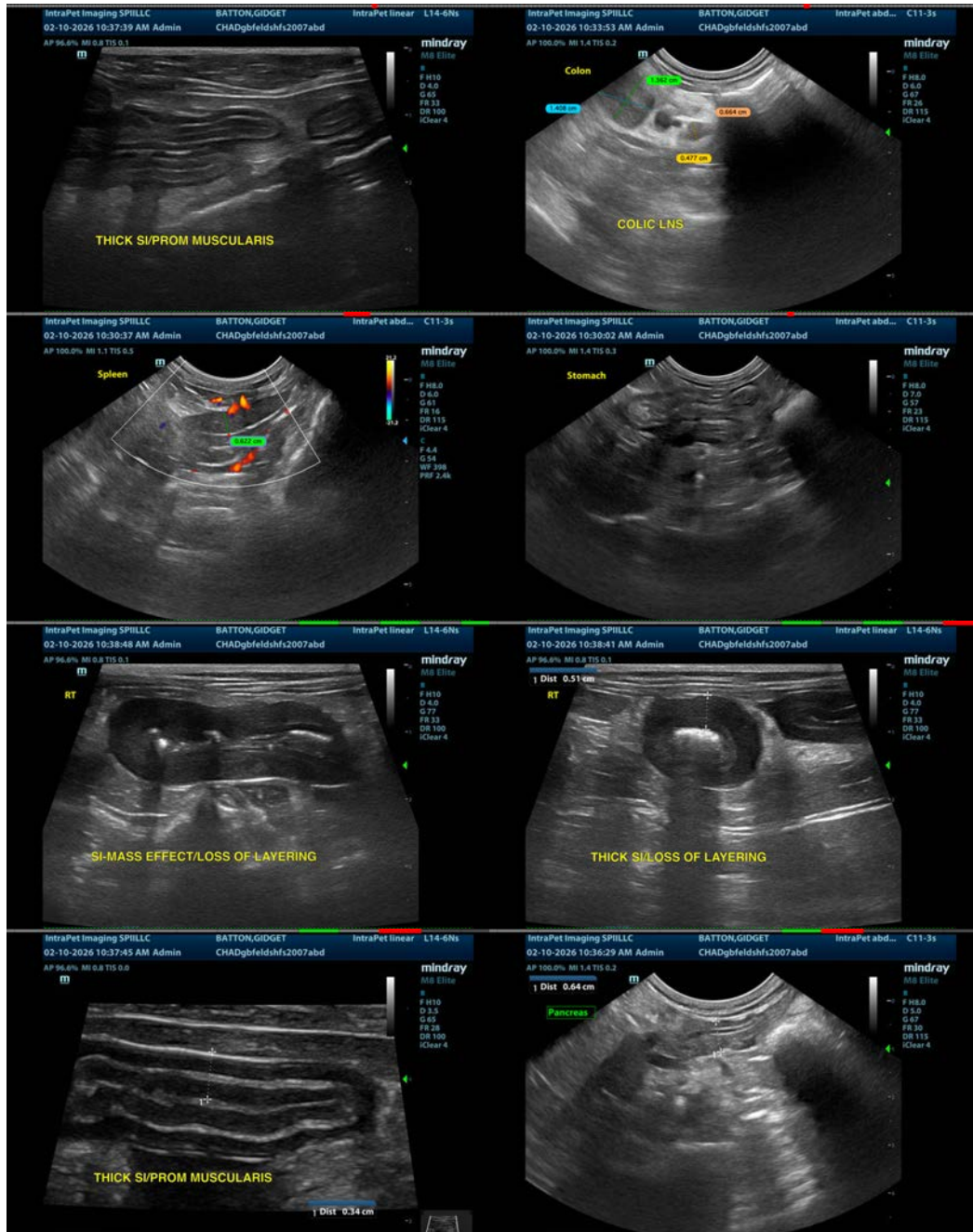
ULTRASONOGRAPHIC FINDINGS

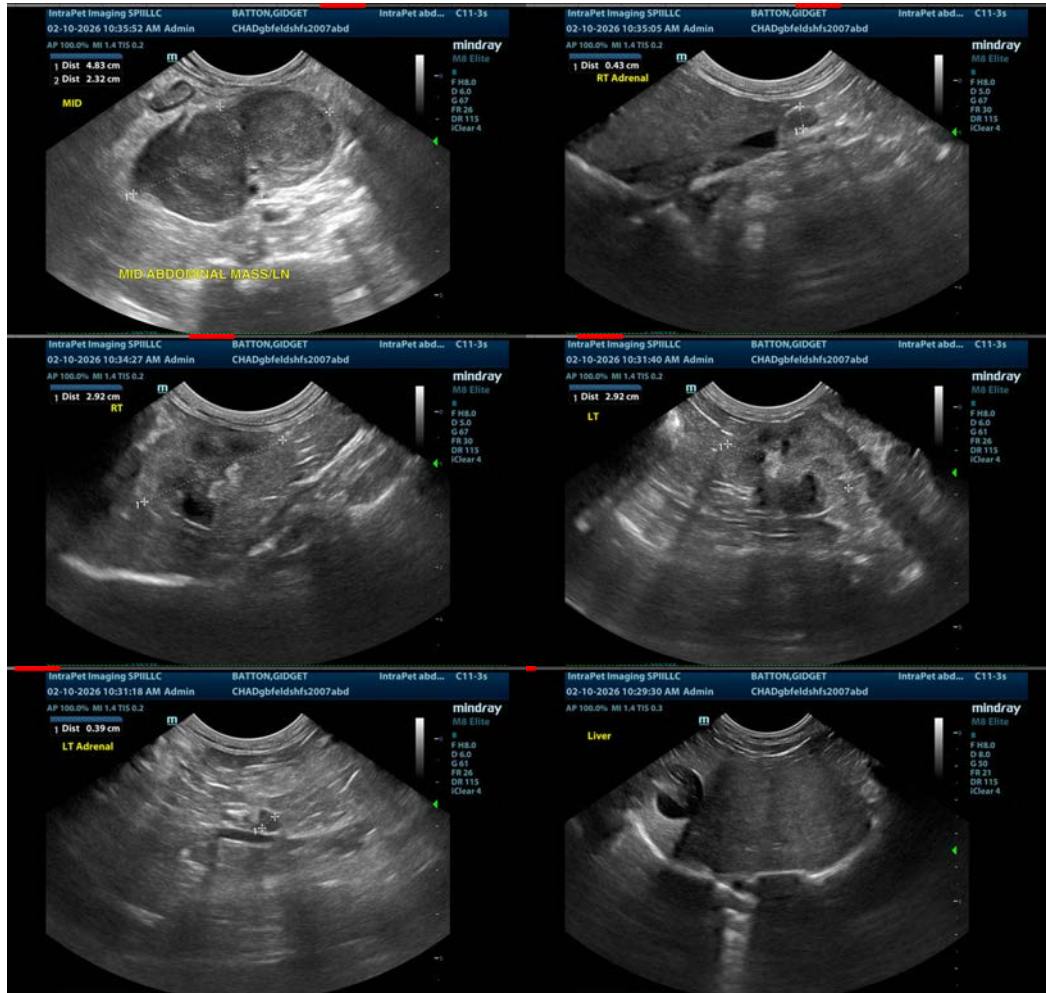
- Small, irregular kidneys with decreased corticomedullary distinction and mild pyelectasia – Mild loss of corticomedullary distinction in both kidneys could be consistent with chronic degenerative disease or interstitial nephrosis.
- Pancreatic changes most consistent with chronic pancreatic remodeling +/- chronic pancreatitis.
- Diffusely thickened small intestine with a prominent muscularis layer and a focal area with complete loss of layering – Findings are most consistent with an infiltrative lesion. Neoplasia would be most likely (round cell neoplasia, carcinoma, other), although other differentials are possible.
- Severely enlarged mesenteric lymph nodes – Findings are most consistent with metastatic lymph nodes.

INTERPRETATION OF THE FINDINGS & FURTHER RECOMMENDATIONS

There is severe diffuse thickening of the small intestine with a prominent muscularis layer, as well as a focal bowel mass lesion. There are numerous large mesenteric lymph nodes, some have the appearance of mass

like lesions. Primary differential would be infiltrative neoplasia to the bowel with metastatic lymph nodes (round cell neoplasia, carcinoma, other). Other differentials are possible. Recommend a fine needle aspirate of the focal mass and a large mesenteric lymph node for cytologic evaluation. If a diagnosis cannot be obtained, surgical biopsies may need to be considered. If a diagnosis can be obtained, recommend consultation with a veterinary oncologist, as medical therapy may be most desirable in this situation.





The information and recommendations provided are based on the images presented by the referring veterinarian/sonographer. No evaluation can be communicated regarding pathology that was not visible in the image/video clips provided.

Thank you for this referral. If the clinical or image interpretation does not parallel your findings or if I can be of any further assistance please contact me.

Kathleen Sennello DVM,MS, Diplomate ACVIM (Small animal Internal Medicine)
 info@sonopath.com