SonoPath
Clinical Sonography & Telecytology

EDUCATIONAL TELECONSULTATION SERVICES™

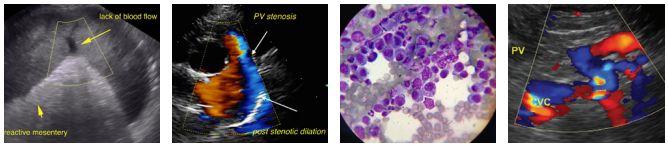

SonoPath.com™
1-800-838-4268 info@sonopath.com

PATIENT
Smoochie Opalenik

SPECIES
Feline

BREED
DSH

SEX
Spayed Female

AGE
14 Years

WEIGHT
11.75 Pounds

INTERPRETED BY
Kathleen Sennello DVM, MS, Diplomate ACVIM (Small Animal Internal Medicine)

IMAGING PERFORMED BY
Kelly Vazquez

HOSPITAL NAME
Cresskill AH

REFERRING VET
Dr. Khodari

INVOICE
35589

DATE
2/10/22

PRESENTING CLINICAL SIGNS

Hematemesis, weight loss, thickened intestines on radiographs, inappetence. History of cutaneous MCT (incomplete margins). Current meds: sucralfate, Pepcid, and Benadryl. Bloods WNL, T4 WNL.

ULTRASONOGRAPHIC EXAMINATION OF THE ABDOMEN

Urinary System

The urinary bladder is moderately distended with mild primarily suspended echogenic debris present. The Bladder wall, trigone, ureteral papillae and visible urethra (to a depth of 2cm) appear normal with no evidence of wall thickening, mucosal irregularities, masses or calculi. Echogenic debris of this type can be associated with small crystals, cellular debris and proteinaceous debris.

The left kidney has a normal shape and size (3.5 cm). Overall echogenicity is normal with adequate corticomedullary distinction and a typical 1:3 cortex:medulla ratio. There is no evidence of perinephric inflammation or effusion. There is no evidence of pyelectasia, nephroliths, infarcts or hydroureter. Renal vasculature is normal.

The right kidney has a normal shape and size (4.12 cm). Overall echogenicity is normal with adequate corticomedullary distinction and a typical 1:3 cortex:medulla ratio. There is no evidence of perinephric inflammation or effusion. There is no evidence of pyelectasia, nephroliths, infarcts or hydroureter. Renal vasculature is normal.

Adrenal Glands

The left adrenal gland is normal in size measuring 0.45 cm at the caudal pole. It is observed in its normal position cranial to the left renal artery. It is normal in appearance (uniformly hypoechoic) and shape with no evidence of a mass effect.

The region of the right adrenal (between right cranial kidney and vena cava) is unremarkable, but the adrenal is not distinctly visualized. No evidence of a mass effect.

Spleen

The spleen is subjectively normal in size (0.61 cm in width at the level of the hilus), echotexture is homogenous, and the splenic capsule is smooth with no irregularities. The blood flow through the hilus and splenic parenchyma appears normal. No focal parenchymal abnormalities are visualized.

Liver

The liver is subjectively normal in size, and echogenicity with smooth peripheral margins. The parenchyma is homogenous echotexture. The visible portions of the vasculature and biliary tract appear normal. No focal nodules or cystic lesions are observed.

The gallbladder lumen is moderately distended. The wall of the gall bladder is not thickened and has a smooth mucosal surface. Luminal contents are primarily anechoic. The cystic and common bile ducts are normal/not visible.

Gastrointestinal

The stomach is moderately dilated with fluid and irregular shadowing material most consistent with normal ingesta and gas. It measures at a normal thickness of <0.36cm with some variability due to the presence of rugal folds. The distinction of the gastric wall layering is adequate and there is no impression of reduced peristaltic activity. While no focal mass effects are visualized, retention of material within the gastric lumen is concerning. A definitive obstruction is not visualized.

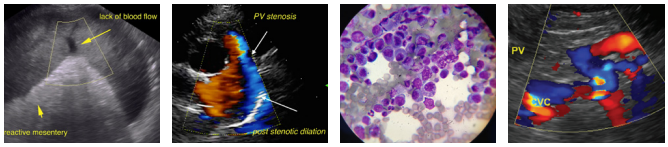

SonoPath.com™
1-800-838-4268 info@sonopath.com

PATIENT
Smoochie Opalenik

SPECIES
Feline

BREED
DSH

SEX
Spayed Female

AGE
14 Years

WEIGHT
11.75 Pounds

INTERPRETED BY
Kathleen Sennello DVM, MS, Diplomate ACVIM (Small Animal Internal Medicine)

IMAGING PERFORMED BY
Kelly Vazquez

HOSPITAL NAME
Cresskill AH

REFERRING VET
Dr. Khodari

INVOICE
35589

DATE
2/10/22

The visualized areas of duodenum, jejunum and ileum have a uniform diameter with minimal fluid distension. Wall thickness is normal to slightly increased. Bowel loops follow a typical curvilinear path with distinct wall layering, but some areas display a prominent muscularis layer which does not display the typical 1:3 muscularis:mucosa layer ratio. Jejunum wall measured 0.34, 0.37 cm. Visualized peristalsis appears appropriate. There were no focal lesions consistent with obstruction or a mass effect observed.

The ileocecal junction was visualized and exhibited normal intact wall layering and is subjectively of normal thickness. Sections of colon are visualized with formed fecal material and gas shadowing distally. There is no observed focal or generalized colon wall thickening or loss of layering.

Pancreas

The pancreas is large and hypoechoic to surrounding mesentery. There is no evidence of nodules or cystic lesions. There is evidence of regional mesenteric inflammation. Consistent with mild pancreatitis. Prominent pancreatic duct noted.

Free Abdomen

Evaluation of the peritoneal cavity did not reveal any evidence of effusion, or subjective lymphadenomegaly. The Medial iliac nodes appear normal and there was no evidence of a caudal aortic thrombus at the bifurcation. The omentum is of normal uniform echogenicity.

ULTRASONOGRAPHIC FINDINGS

- Mildly thickened small intestine with prominent muscularis layer – The small intestinal wall changes are most consistent with an inflammatory process (i.e., inflammatory bowel disease) with a low possibility of emerging lymphoma.
- Moderately dilated stomach with fluid/ingesta – Correlate with feeding history and abdominal radiographs. If the patient is adequately fasted, there could be concern for ileus or a partial gastric outflow tract obstruction (none clearly visualized).
- Hypoechoic, prominent pancreas – The pancreatic changes are most consistent with mild pancreatitis/pancreatic inflammation. Recommend fPLI testing and continued monitoring for improvement or possible development of a pancreatic abscess. Consider fine needle aspirate if not improving.

INTERPRETATION OF THE FINDINGS & FURTHER RECOMMENDATIONS

The small intestine is subjectively thickened with prominent muscularis layer. This is a non-specific finding in older cats, but can be consistent with primary GI disease. Additionally, the pancreas is prominent. Recommend running a GI panel to Texas A&M for a qualitative fPLI, TLI, cobalamin and folate to further evaluate the pancreas and small intestine.

The stomach is moderately distended with fluid and ingesta. This is concerning if the patient is adequately fasted, as this could be an indicator of a partial gastric outflow tract obstruction or gastric ileus. I was unable to see a pointed obstruction, but these can sometimes be difficult to visualize.

- Consider the aforementioned GI panel.
- Consider symptomatic therapy with anti-ulcer medications and correlate findings with radiographs in the case of possible acute gastroenteritis/pancreatitis.
- If symptoms persist, consider explore or upper GI endoscopy to obtain biopsies and further

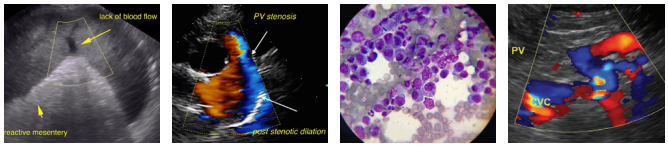

SonoPath.com™
1-800-838-4268 info@sonopath.com

PATIENT

Smoochie Opalenik

SPECIES

Feline

BREED

DSH

SEX

Spayed Female

AGE

14 Years

WEIGHT

11.75 Pounds

INTERPRETED BY

Kathleen Sennello DVM, MS, Diplomate ACVIM (Small Animal Internal Medicine)

IMAGING PERFORMED BY

Kelly Vazquez

HOSPITAL NAME

Cresskill AH

REFERRING VET

Dr. Khodari

INVOICE

35589

DATE

2/10/22

evaluate for evidence of an obstruction, mass effect, etc., and to biopsy the small intestine.

- Recommend urinalysis and culture to further evaluate the echogenic debris in the urinary bladder.

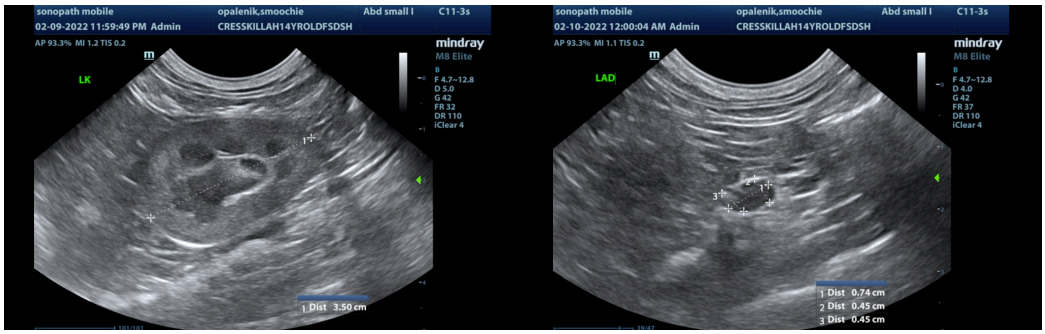

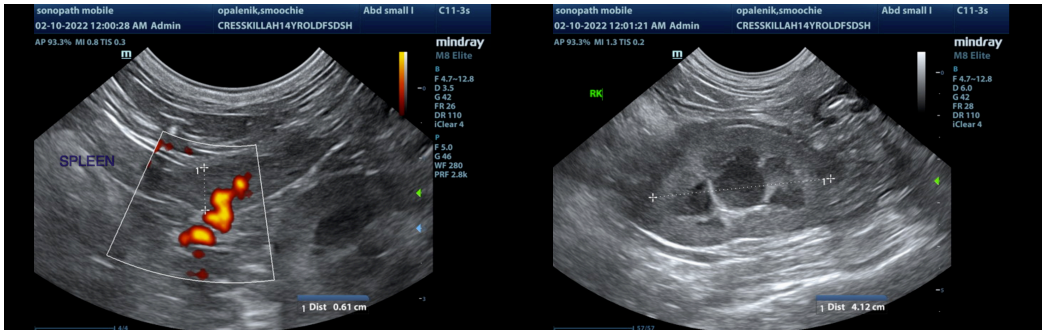

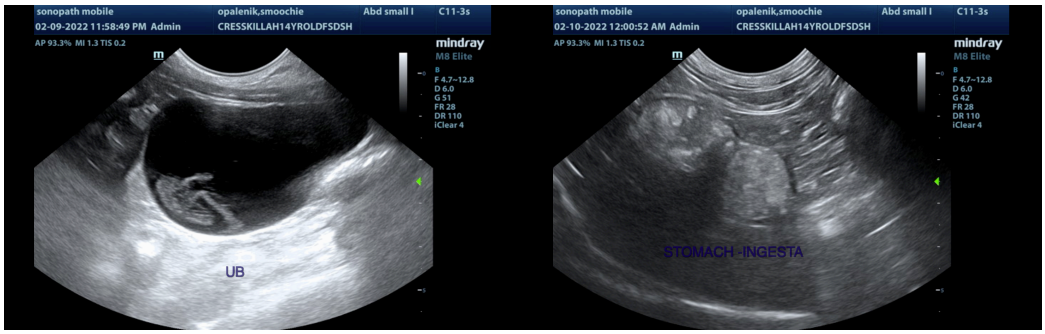

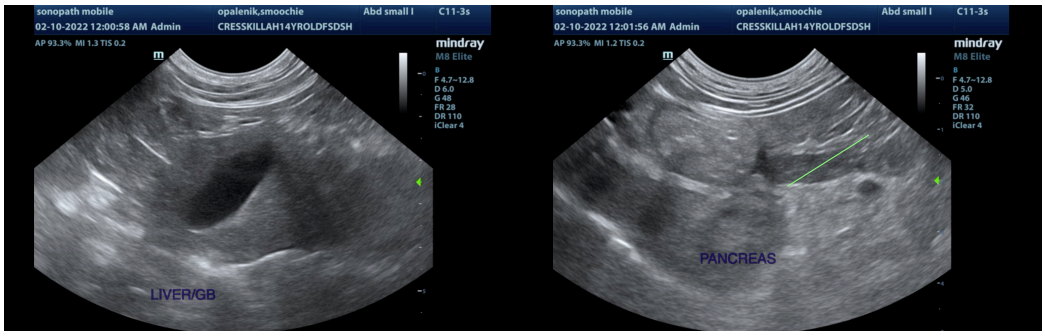

SonoPath
Clinical Sonography & Telecytology

EDUCATIONAL TELECONSULTATION SERVICES™

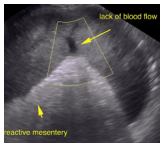

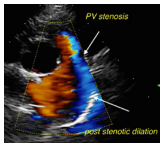

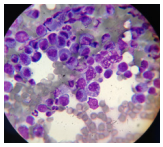
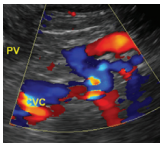

SonoPath.com™
1-800-838-4268 info@sonopath.com

PATIENT

Smoochie Opalenik

SPECIES

Feline

BREED

DSH

SEX

Spayed Female

AGE

14 Years

WEIGHT

11.75 Pounds

INTERPRETED BY

Kathleen Sennello DVM, MS, Diplomate ACVIM (Small Animal Internal Medicine)

IMAGING PERFORMED BY

Kelly Vazquez

HOSPITAL NAME

Cresskill AH

REFERRING VET

Dr. Khodari

INVOICE

35589

DATE

2/10/22

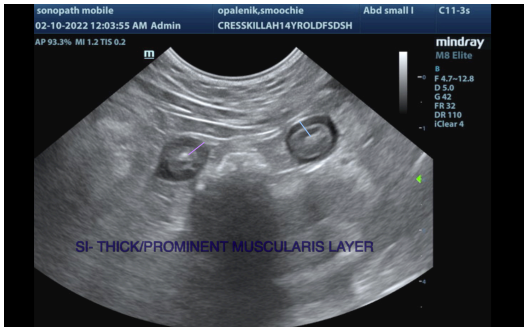

The information and recommendations provided are based on the images presented by the referring veterinarian/sonographer. No evaluation can be communicated regarding pathology that was not visible in the image/video clips provided.

Thank you for this referral. If the clinical or image interpretation does not parallel your findings or if I can be of any further assistance please contact me.

Kathleen Sennello DVM,MS, Diplomate ACVIM (Small animal Internal Medicine)

kathleen.sennello@sonopath.com