



PATIENT

Georgia Kalembe

SPECIES

Canine

BREED

Mixed

SEX

Spayed Female

AGE

11 Years

WEIGHT

76.5 Pounds

INTERPRETED BY

Kathleen Sennello DVM,
MS, Diplomate ACVIM
(Small Animal Internal
Medicine)

**IMAGING
PERFORMED BY**

Marco and Dr.
Ammeraal

HOSPITAL NAME

Sova Animal Hospital

REFERRING VET

Dr. John Ammeraal

INVOICE

35584

DATE

2/10/22

PRESENTING CLINICAL SIGNS

Presenting for PU/PD, Polyphagia over past month. R/O ADH vs PDH
Abnormal PE/Chem/CBC/UA Results: ALKP: 1126U/L, ALT 123 U/L LDDST: 4.1 ug/dL, 4 hour 3.7 ug/dL. 8 hour: 3.9 ug/dL

ULTRASONOGRAPHIC EXAMINATION OF THE ABDOMEN

Urinary System

The urinary bladder is moderately distended with anechoic urine. The Bladder wall, trigone, ureteral papillae and visible urethra (to a depth of 2cm) appear normal with no evidence of wall thickening, mucosal irregularities, masses or cystic calculi.

The left kidney has a normal shape and size (7.74 cm). Overall echogenicity is normal with adequate corticomedullary distinction and a typical 1:3 cortex:medulla ratio. There is no evidence of perinephric inflammation or effusion. There is no evidence of pyelectasia, nephroliths, infarcts or hydroureter. Renal vasculature is normal.

The right kidney has a normal shape and size (6.98 cm). Overall echogenicity is normal with adequate corticomedullary distinction and a typical 1:3 cortex:medulla ratio. There is no evidence of perinephric inflammation or effusion. There is no evidence of pyelectasia, nephroliths, infarcts or hydroureter. Renal vasculature is normal.

Adrenal Glands

The left adrenal gland is normal in size measuring 0.65 cm at the cranial pole and 0.73 cm at the caudal pole, and 2.2 cm in length. It is observed in its normal position cranial to the left renal artery. It is normal in appearance (uniformly hypoechoic) and shape with no evidence of a mass effect.

The right adrenal gland is large in size measuring 2.01 cm at the cranial pole, 1.83 cm at the caudal pole, and 3.54 cm in length. It is observed in its normal position between the cranial aspect of the right kidney and the caudal vena cava. It is somewhat abnormal in appearance in that it is large and ovoid in shape. There is no obvious evidence of vascular invasion.

Spleen

The spleen is subjectively normal in size, echotexture is homogenous, and the splenic capsule is smooth with no irregularities. The blood flow through the hilus and splenic parenchyma appears normal. No focal parenchymal abnormalities are visualized.

Liver

The liver is large in size, and normal in echogenicity with smooth peripheral margins. The parenchyma is heterogenous in echotexture with subtle, indistinct focal mottling. The visible portions of the vasculature and biliary tract appear normal. No focal nodules or cystic lesions are observed.

The gall bladder lumen is moderately distended. The wall of the gall bladder is not thickened and has a smooth mucosal surface. There is a moderate amount of non-organized echogenic debris. The cystic and common bile ducts are normal/not visible.

Gastrointestinal

The stomach contains minimal luminal contents. It measures at a normal thickness of <0.7cm with some variability due to the presence of rugal folds. The distinction of the gastric wall layers is adequate and there is no impression of reduced peristaltic activity. No masses or focal lesions were observed.



PATIENT

Georgia Kalembo

SPECIES

Canine

BREED

Mixed

SEX

Spayed Female

AGE

11 Years

WEIGHT

76.5 Pounds

INTERPRETED BY

Kathleen Sennello DVM,
MS, Diplomate ACVIM
(Small Animal Internal
Medicine)

**IMAGING
PERFORMED BY**

Marco and Dr.
Ammeraal

HOSPITAL NAME

Sova Animal Hospital

REFERRING VET

Dr. John Ammeraal

INVOICE

35584

DATE

2/10/22

The visualized areas of duodenum, jejunum and ileum have a relatively uniform diameter with minimal fluid distension. Wall thickness is normal. Bowel loops follow a curvilinear path with distinct wall layering maintaining the typical 1:3 muscularis:mucosa layer ratio. The duodenum measured as normal (between 0.3-0.5cm in wall thickness) and the jejunum measured as normal (between 0.2-0.47cm.) Visualized peristalsis appears appropriate. There were no focal lesions consistent with obstruction or a mass effect observed.

The ileocecal junction was visualized and exhibited normal intact wall layering and is subjectively of normal thickness. Sections of colon are visualized with formed fecal material and gas shadowing distally. There is no observed focal or generalized colon wall thickening or loss of layering.

Pancreas

The pancreas is normal and isoechoic to surrounding mesentery. There is no evidence of nodules or cystic lesions. There is no evidence of regional mesenteric inflammation or fluid.

Free Abdomen

Evaluation of the peritoneal cavity did not reveal any evidence of effusion, or subjective lymphadenomegaly. The Medial iliac nodes appear normal and there was no evidence of a caudal aortic thrombus at the bifurcation. The omentum is of normal uniform echogenicity.

PRIMARY FINDINGS

- Large right adrenal gland – Right adrenomegaly could be consistent with neoplasia (e.g., adenoma, carcinoma, pheochromocytoma), hyperplasia, inflammation, other.
- Large, heterogeneous liver – The diffuse hepatic changes are non-specific and could be consistent with vacuolar hepatopathy, nodular hyperplasia, inflammatory/immune-mediated disease, fibrosis, extramedullary hematopoiesis, toxic hepatopathy (e.g., copper), infiltrative neoplasia (less likely) or other hepatopathy.

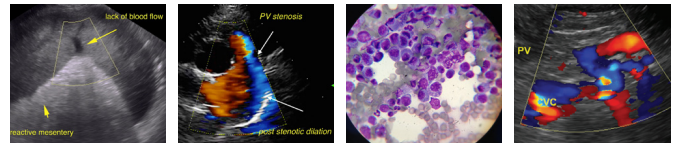
SECONDARY FINDINGS

- Moderate gallbladder debris – The significance of the aggregated gallbladder sludge is unclear. This could represent an early mucocele, cholestasis, or may be secondary to fasting.

INTERPRETATION OF THE FINDINGS & FURTHER RECOMMENDATIONS

The right adrenal gland appears large and somewhat irregular in shape. I do not see clear evidence of vascular invasion, but it is still a possibility. This is most consistent with a mass effect, which could be benign or malignant, and could secrete hormones or be non-active. Options moving forward include:

- If signs of cushings are present, consider adrenal function testing. I prefer an ACTH stimulation test combined with an adrenal panel to the University of Tennessee's endocrine lab to look for atypical adrenal hormones as well as cortisol. (other testing can suffice)
- If adrenal dependent cushings is suspected and supported by adrenal function testing consider medical therapy with lysodren or trilostane and/or consider surgical removal (recommend referral to a board certified veterinary surgeon and possible pre op CT)-This can be a challenging surgery with significant risk for complication
- Recommend blood pressure evaluation-if hypertensive consider testing catecholamine levels for a possible pheochromocytoma
- Due to the invasive nature of these masses a CT scan is recommended to evaluate for metastasis and vascular invasion.



PATIENT

Georgia Kalemba

- If no symptoms of Cushings are present, consider either referral for surgery or if surgery is not an option consultation with a veterinary oncologist regarding chemotherapeutic options and continued monitoring with ultrasound (in 4-6 weeks) can be considered.
- Some aggressive adrenal tumors can grow quickly and there is risk for acute hemorrhage from vascular invasion.

SPECIES

Canine

Although the right adrenal gland is approximately twice the size of the left adrenal gland, it does not appear irregular or invasive in nature. The changes observed in the liver are most likely associated with a steroid hepatopathy/vacuolar hepatopathy.

BREED

Mixed

Recommend 3-view thoracic radiographs.

SEX

Spayed Female

AGE

11 Years

WEIGHT

76.5 Pounds

INTERPRETED BY

Kathleen Sennello DVM, MS, Diplomate ACVIM (Small Animal Internal Medicine)

IMAGING PERFORMED BY

Marco and Dr. Ammeraal

HOSPITAL NAME

Sova Animal Hospital

REFERRING VET

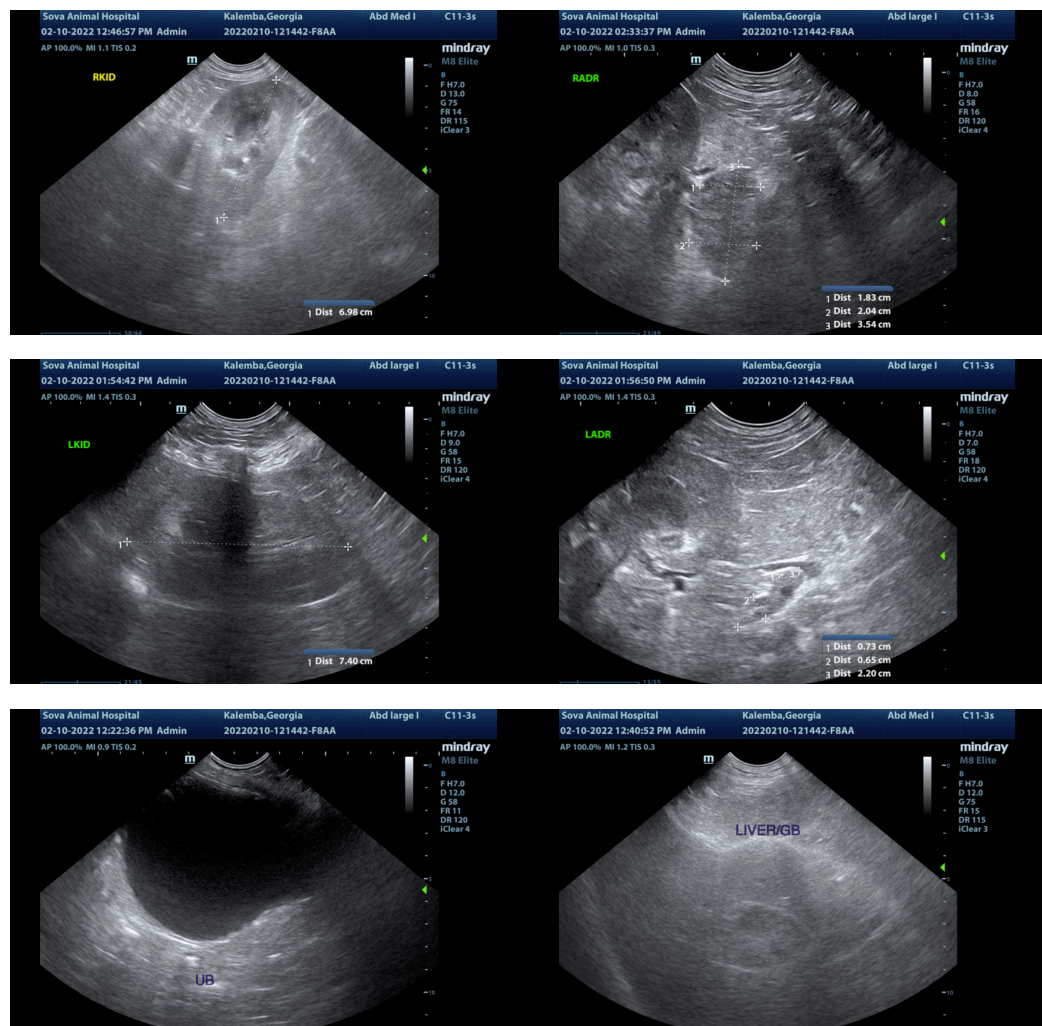
Dr. John Ammeraal

INVOICE

35584

DATE

2/10/22





PATIENT

Georgia Kalembo

The information and recommendations provided are based on the images presented by the referring veterinarian/sonographer. No evaluation can be communicated regarding pathology that was not visible in the image/video clips provided.

SPECIES

Canine

Thank you for this referral. If the clinical or image interpretation does not parallel your findings or if I can be of any further assistance please contact me.

Kathleen Sennello DVM,MS, Diplomate ACVIM (Small animal Internal Medicine)

kathleen.sennello@sonopath.com

BREED

Mixed

SEX

Spayed Female

AGE

11 Years

WEIGHT

76.5 Pounds

INTERPRETED BY

Kathleen Sennello DVM,
MS, Diplomate ACVIM
(Small Animal Internal
Medicine)

**IMAGING
PERFORMED BY**

Marco and Dr.
Ammeraal

HOSPITAL NAME

Sova Animal Hospital

REFERRING VET

Dr. John Ammeraal

INVOICE

35584

DATE

2/10/22