



**PATIENT**

Ellie Heller

**SPECIES**

Feline

**BREED**

DSH

**SEX**

Spayed Female

**AGE**

8 Years 5 Months

**WEIGHT**

5.2 lbs

**INTERPRETED BY**

Kathleen Sennello DVM,  
MS, Diplomate ACVIM  
(Small Animal Internal  
Medicine)

**IMAGING PERFORMED BY**

Shari Reffi, CVT

**HOSPITAL NAME**

VCA Northside Animal  
Hospital

**REFERRING VET**

Dr. Fusselman

**INVOICE**

72444

**DATE**

12/9/25

**PRESENTING CLINICAL SIGNS**

Wt. loss, diarrhea, ravenous appetite. Dehydration, persistent leukocytosis in face of Abx trial. Meds: Gabapentin.

Abnormal PE/Chem/CBC/UA Results: BUN 65; Crea 1.7; WBC 22.7; Neut 152136; Mono 1816; Eos 1816. UA: USG 1.019

**ULTRASONOGRAPHIC EXAMINATION OF THE ABDOMEN**

**Urinary System**

The urinary bladder is moderately distended with anechoic urine. The Bladder wall, trigone, ureteral papillae and visible urethra (to a depth of 2cm) appear normal with no evidence of wall thickening, mucosal irregularities, masses or cystic calculi.

The left kidney has a normal shape and size (2.7 cm). Overall echogenicity is slightly hyperechoic with poor corticomedullary distinction and a typical 1:3 cortex:medulla ratio. There is no evidence of focal perinephric inflammation or effusion. There is no evidence of pyelectasia, nephroliths, infarcts or hydroureter. Renal vasculature is normal.

The right kidney has a normal shape and size (2.82 cm). Overall echogenicity is slightly hyperechoic with poor corticomedullary distinction and a typical 1:3 cortex:medulla ratio. There is no evidence of focal perinephric inflammation or effusion. There is no evidence of pyelectasia, nephroliths, infarcts or hydroureter. Renal vasculature is normal.

**Adrenal Glands**

The left adrenal gland is normal/borderline "plump" measuring 0.52 cm at the caudal pole. It is observed in its normal position cranial to the left renal artery. It is normal in appearance (uniformly hypoechoic) and shape with no evidence of a mass effect.

The right adrenal gland is normal in size measuring 0.47 cm at the caudal pole. It is observed in its normal position between the cranial aspect of the right kidney and the caudal vena cava. It is normal in appearance (uniformly hypoechoic) and shape with no evidence of a mass effect.

**Spleen**

The spleen is subjectively normal in size (0.55 cm), echotexture is homogenous, and the splenic capsule is smooth with no irregularities. The blood flow through the hilus and splenic parenchyma appears normal. No focal parenchymal abnormalities are visualized.

**Liver**

The liver is subjectively normal in size, and echogenicity with smooth peripheral margins. The parenchyma is homogenous echotexture. The visible portions of the vasculature and biliary tract appear normal. No focal nodules or cystic lesions are observed.

The gall bladder lumen is moderately distended. The wall of the gall bladder is not thickened and has a smooth mucosal surface. Luminal contents are mild and likely incidental at this time. The cystic and common bile ducts are normal/not visible.



**PATIENT**

Ellie Heller

**SPECIES**

Feline

**BREED**

DSH

**SEX**

Spayed Female

**AGE**

8 Years 5 Months

**WEIGHT**

5.2 lbs

**INTERPRETED BY**

Kathleen Sennello DVM,  
MS, Diplomate ACVIM  
(Small Animal Internal  
Medicine)

**IMAGING PERFORMED BY**

Shari Reffi, CVT

**HOSPITAL NAME**

VCA Northside Animal  
Hospital

**REFERRING VET**

Dr. Fusselman

**INVOICE**

72444

**DATE**

12/9/25

***Gastrointestinal***

The stomach contains minimal luminal contents. It measures at a normal thickness of <0.36cm with some variability due to the presence of rugal folds. The distinction of the gastric wall layers is adequate and there is no impression of reduced peristaltic activity. No masses or focal lesions were observed.

The visualized areas of duodenum, jejunum and ileum have a uniform diameter with minimal fluid distension. Wall thickness is normal to slightly increased. Bowel loops follow a typical curvilinear path with distinct wall layering, but some areas display a prominent muscularis layer which does not display the typical 1:3 muscularis:mucosa layer ratio. Jejunum wall measures 0.25 cm. Visualized peristalsis appears appropriate. There were no focal lesions consistent with obstruction or a mass effect observed.

The ileocecal junction was visualized and exhibited normal intact wall layering and is subjectively of normal thickness. Sections of colon are visualized with non-formed fecal material and gas shadowing distally. The descending colon wall appears prominent and thickened at 0.32 cm with intact wall layering.

***Pancreas***

The pancreas is normal and isoechoic to surrounding mesentery. There is no evidence of nodules or cystic lesions. There is no evidence of regional mesenteric inflammation or fluid.

***Free Abdomen***

Evaluation of the peritoneal cavity did not reveal any evidence of effusion. There is no significant lymphadenopathy. A prominent mesenteric lymph node is visualized measuring 0.36 cm. The omentum is of normal echogenicity.

**ULTRASONOGRAPHIC FINDINGS**

- Decreased corticomedullary distinction in both kidneys – Mild loss of corticomedullary distinction in both kidneys could be consistent with chronic degenerative disease or interstitial nephrosis.
- Diffusely prominent/ropey small intestine with some areas exhibiting a prominent muscularis layer – The small intestinal wall changes are most consistent with an inflammatory process (i.e., inflammatory bowel disease) with a low possibility of emerging lymphoma.
- Thickened colon wall with intact wall layering – Findings are most consistent with colitis. Other differentials are possible.

**INTERPRETATION OF THE FINDINGS & FURTHER RECOMMENDATIONS**

There is general evidence of inflammatory type change involving the small and large bowel. An early neoplastic process cannot be ruled out but seems less likely. Consider the following for further evaluation:

- Recommend a combination hydrolyzed protein prescription and renal diet (I believe Royal Canin has one).



**PATIENT**

Ellie Heller

- Consider a GI panel to Texas A&M for evaluation of B12 levels, folate, PLI/TLI etc.. to further evaluate for pancreatic/small intestinal disease (this will evaluate for exocrine pancreatic insufficiency, a low B12 level, etc.).

**SPECIES**

Feline

- If not already done, recommend parasite screening and empirical deworming.

**BREED**

DSH

- Consider screening for infectious causes of diarrhea (if clinically appropriate).

**SEX**

Spayed Female

- Recommend chronic probiotic therapy.

If empirical therapy doesn't work, it is possible that upper and lower GI endoscopy may be warranted to further evaluate and obtain biopsies for histopathology.

Both kidneys have changes consistent with chronic renal disease. If not already done, recommend a blood pressure, urinalysis, culture, and a urine protein to creatinine ratio as a baseline.

**AGE**

8 Years 5 Months

**WEIGHT**

5.2 lbs

**INTERPRETED BY**

Kathleen Sennello DVM,  
MS, Diplomate ACVIM  
(Small Animal Internal  
Medicine)

**IMAGING  
PERFORMED BY**

Shari Reffi, CVT

**HOSPITAL NAME**

VCA Northside Animal  
Hospital

**REFERRING VET**

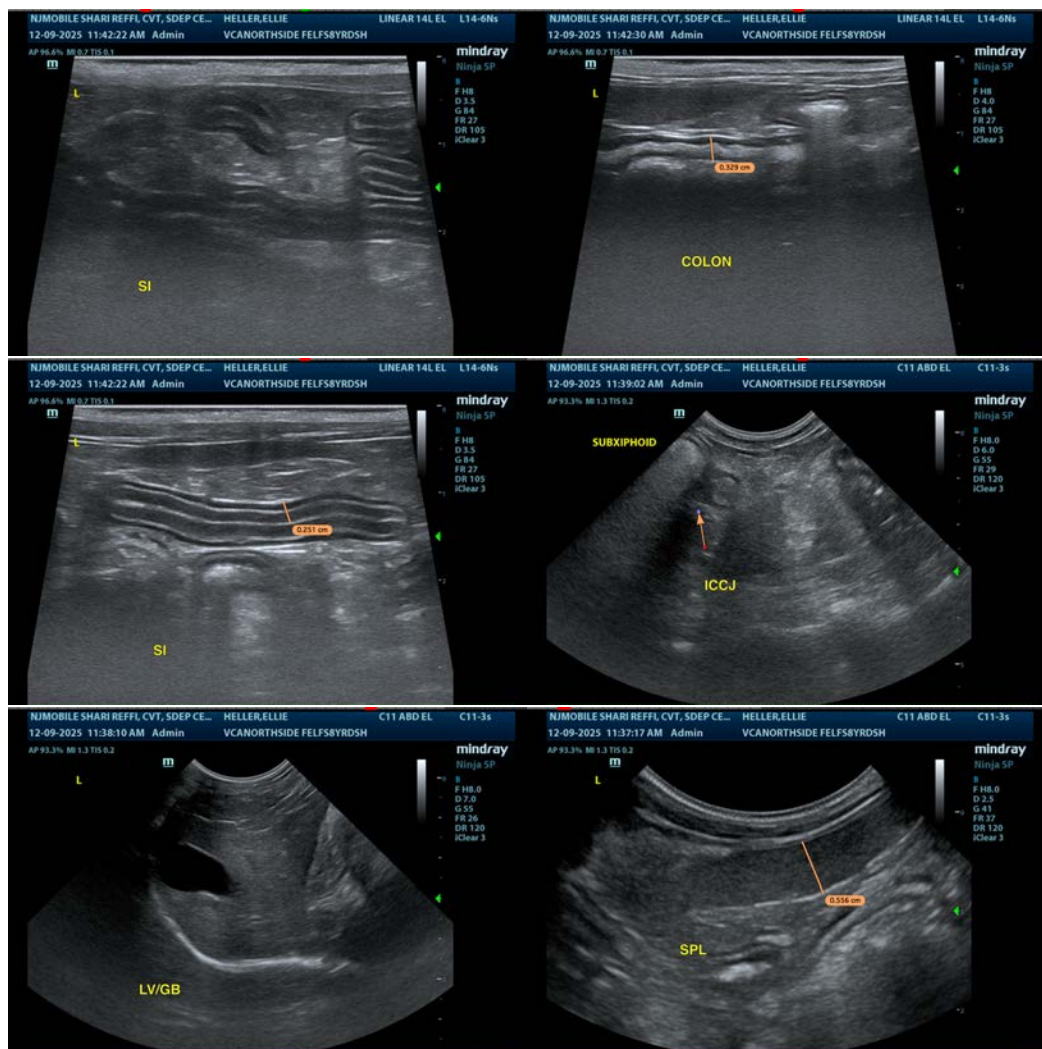
Dr. Fusselman

**INVOICE**

72444

**DATE**

12/9/25





**PATIENT**

Ellie Heller

**SPECIES**

Feline

**BREED**

DSH

**SEX**

Spayed Female

**AGE**

8 Years 5 Months

**WEIGHT**

5.2 lbs

**INTERPRETED BY**

Kathleen Sennello DVM,  
 MS, Diplomate ACVIM  
 (Small Animal Internal  
 Medicine)

**IMAGING  
 PERFORMED BY**

Shari Reffi, CVT

**HOSPITAL NAME**

VCA Northside Animal  
 Hospital

**REFERRING VET**

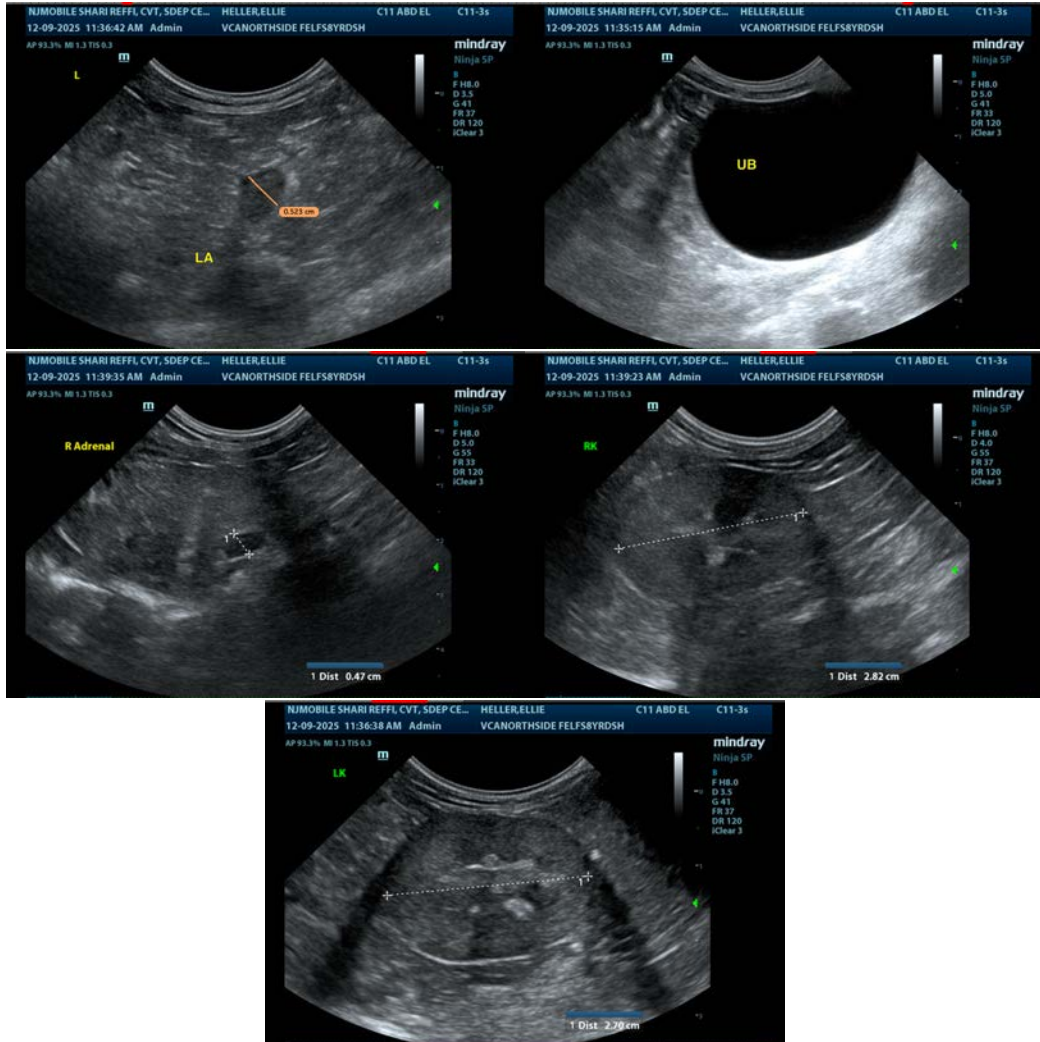
Dr. Fusselman

**INVOICE**

72444

**DATE**

12/9/25



The information and recommendations provided are based on the images presented by the referring veterinarian/sonographer. No evaluation can be communicated regarding pathology that was not visible in the image/video clips provided.

Thank you for this referral. If the clinical or image interpretation does not parallel your findings or if I can be of any further assistance please contact me.

Kathleen Sennello DVM, MS, Diplomate ACVIM (Small animal Internal Medicine)

info@sonopath.com