



PATIENT

Sophie Shaika

SPECIES

Feline

BREED

DLH

SEX

Spayed Female

AGE

12 Years

WEIGHT

7.2 Pounds

INTERPRETED BY

Kathleen Sennello DVM,
MS, Diplomate ACVIM
(Small Animal Internal
Medicine)

**IMAGING
PERFORMED BY**

Dr. Tam Mengine

HOSPITAL NAME

Stoney Creek VH

REFERRING VET

Dr. Tam Mengine

INVOICE

33376

DATE

12/9/21

PRESENTING CLINICAL SIGNS

Diagnosed with IRIS Stage 2 renal dz in 10/20 on routine wellness bloodwork. Recheck renal values at wellness exam in 10/21 were stable, but now ALT 452, AST 126, ALP 221. Liver values were rechecked in 11/21 and ALT 517, AST 216, ALP 252, TBili0.4 . Bile acids pending. Pet has no symptoms at home but has lost 1 pound over the last year.

ULTRASONOGRAPHIC EXAMINATION OF THE ABDOMEN

Urinary System

The urinary bladder is moderately distended with anechoic urine. The Bladder wall, trigone, ureteral papillae and visible urethra (to a depth of 2cm) appear normal with no evidence of wall thickening, mucosal irregularities, masses or cystic calculi.

The left kidney has a normal shape and size (3.03 cm). Overall echogenicity is slightly hyperechoic with poor corticomedullary distinction and a typical 1:3 cortex:medulla ratio. There is no evidence of perinephric inflammation or effusion. There is no evidence of pyelectasia, nephroliths, infarcts or hydroureter. Renal vasculature is normal.

The right kidney has a normal shape and size (4.11 cm). Overall echogenicity is slightly hyperechoic with poor corticomedullary distinction and a typical 1:3 cortex:medulla ratio. There is no evidence of perinephric inflammation or effusion. There is no evidence of pyelectasia, nephroliths, infarcts or hydroureter. Renal vasculature is normal.

Adrenal Glands

The left adrenal gland is normal in size measuring 0.24 cm at the caudal pole. It is observed in its normal position cranial to the left renal artery. It is normal in appearance (uniformly hypoechoic) and shape with no evidence of a mass effect.

The right adrenal gland is normal in size measuring 0.30 cm at the caudal pole. It is observed in its normal position between the cranial aspect of the right kidney and the caudal vena cava. It is normal in appearance (uniformly hypoechoic) and shape with no evidence of a mass effect.

Spleen

The spleen is subjectively normal in size (0.72 cm in width at the level of the hilus), echotexture is homogenous, and the splenic capsule is smooth with no irregularities. The blood flow through the hilus and splenic parenchyma appears normal. No focal parenchymal abnormalities are visualized.

Liver

The liver is subjectively normal in size, and echogenicity with smooth peripheral margins. The parenchyma is heterogenous in echotexture with subtle, indistinct focal mottling. The visible portions of the vasculature and biliary tract appear normal. No focal nodules or cystic lesions are observed.

The gallbladder lumen is moderately distended. The wall of the gall bladder is not thickened and has a smooth mucosal surface. Luminal contents are primarily anechoic. The cystic and common bile ducts are normal/not visible.

Gastrointestinal

The stomach contains minimal luminal contents. It measures at a normal thickness of <0.36cm with some variability due to the presence of rugal folds. The distinction of the gastric wall layers is adequate and there is no impression of reduced peristaltic activity. No masses or focal lesions were observed.



PATIENT

Sophie Shaika

The visualized areas of duodenum, jejunum and ileum have a uniform diameter with minimal fluid distension. Wall thickness is normal to slightly increased. Bowel loops follow a typical curvilinear path with distinct wall layering, but some areas display a prominent muscularis layer which does not display the typical 1:3 muscularis:mucosa layer ratio. Duodenum wall measured 0.28 cm. Jejunum wall measured 0.26 cm. Visualized peristalsis appears appropriate. There were no focal lesions consistent with obstruction or a mass effect observed.

SPECIES

Feline

The ileocecal junction was visualized and exhibited normal intact wall layering and is subjectively of normal thickness. Sections of colon are visualized with formed fecal material and gas shadowing distally. There is no observed focal or generalized colon wall thickening or loss of layering. Wall measures 0.17 cm.

BREED

DLH

Pancreas

SEX

Spayed Female

The pancreas is normal and isoechoic to surrounding mesentery. There is no evidence of nodules or cystic lesions. There is no evidence of regional mesenteric inflammation or fluid.

Free Abdomen

AGE

12 Years

Evaluation of the peritoneal cavity did not reveal any evidence of effusion. There are occasional enlarged mesenteric lymph nodes visualized, measuring 0.56, 0.37, and 0.41 cm. The omentum is generally of normal echogenicity.

ULTRASONOGRAPHIC FINDINGS

WEIGHT

7.2 Pounds

- Heterogeneous liver – Hepatic changes are non-specific and could be consistent with inflammation/infection (cholangiohepatitis), infiltrative neoplasia, lipidosis or other hepatopathy.
- Decreased corticomedullary distinction in both kidneys – Mild loss of corticomedullary distinction in both kidneys could be consistent with chronic degenerative disease or interstitial nephrosis.
- Prominent muscularis layer to the small intestine – The small intestinal wall changes are most consistent with an inflammatory process (i.e., inflammatory bowel disease) with a low possibility of emerging lymphoma.
- Mild mesenteric lymphadenopathy – The prominent abdominal lymph nodes are most consistent with reactive lymphadenitis or lymphoid hyperplasia. Neoplastic infiltration is considered less likely.

INTERPRETED BY

Kathleen Sennello DVM,
MS, Diplomate ACVIM
(Small Animal Internal
Medicine)

IMAGING PERFORMED BY

Dr. Tam Mengine

HOSPITAL NAME

Stoney Creek VH

INTERPRETATION OF THE FINDINGS & FURTHER RECOMMENDATIONS

REFERRING VET

Dr. Tam Mengine

The liver is very heterogeneous and borderline large in size with indistinct mottling, almost consistent with poorly defined nodules. It is excellent that you have a bile acids pending, as this will be important information to have.

INVOICE

33376

The renal changes observed are consistent with the chronic renal disease reported. Additionally, there is some thickening in the muscularis layer to the small intestine, which could be an indicator of concurrent underlying small intestinal disease, although this can be a normal finding in some older cats.

DATE

12/9/21

- Recommend pre- and post-prandial bile acids (already done).
- Consider a GI panel to Texas A&M University with a qualitative fPLI, TLI, cobalamin and folate to further evaluate for small intestinal disease.
- If coags normal and clinically appropriate, consider a fine needle aspirate of the liver.



PATIENT

Sophie Shaika

- You could consider empirical treatment for inflammatory liver disease if the aspirate are relatively benign, with Ursodiol, Denamarin, and a course of antibiotics (Clavamox?), but if liver values continue to rise, and liver function is abnormal, a biopsy of the liver and small bowel would be the optimal course.
- Recommend 3-view thoracic radiographs to look for evidence of concurrent intrathoracic disease.
- If not already done, make sure you have current thyroid levels.

SPECIES

Feline

BREED

DLH

SEX

Spayed Female

AGE

12 Years

WEIGHT

7.2 Pounds

INTERPRETED BY

Kathleen Sennello DVM, MS, Diplomate ACVIM (Small Animal Internal Medicine)

IMAGING PERFORMED BY

Dr. Tam Mengine

HOSPITAL NAME

Stoney Creek VH

REFERRING VET

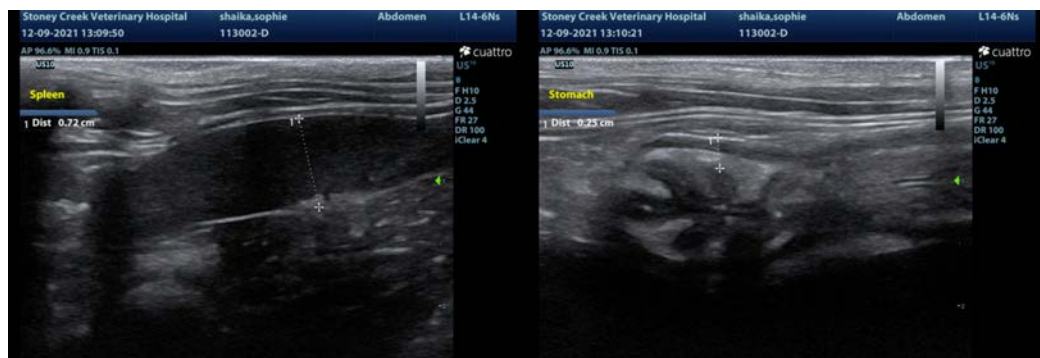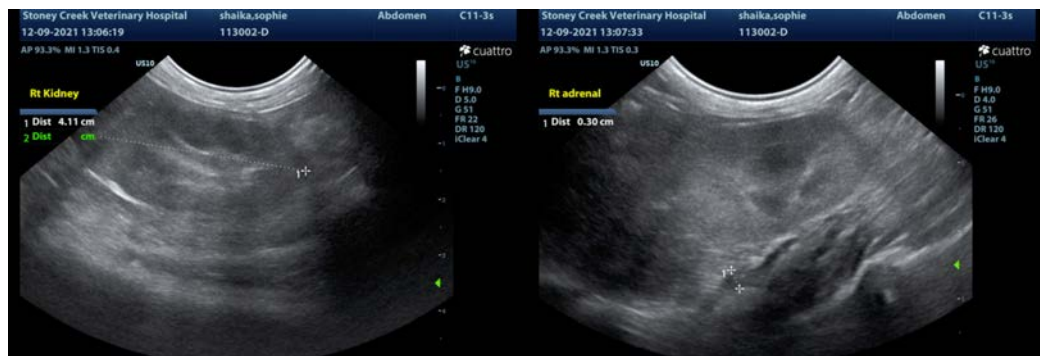
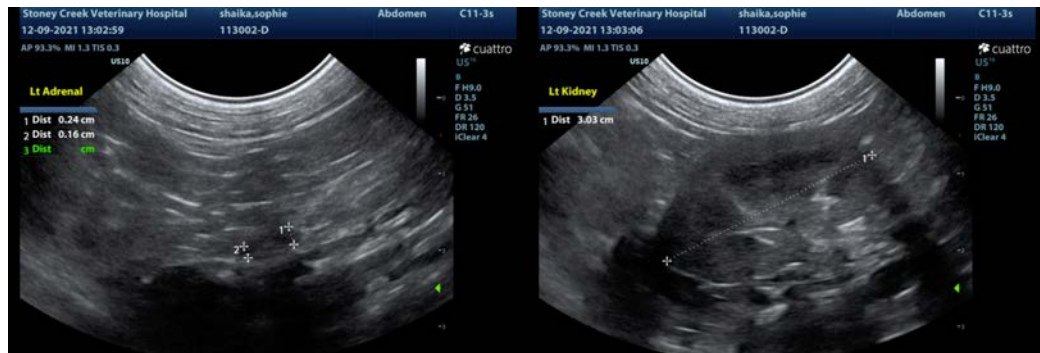
Dr. Tam Mengine

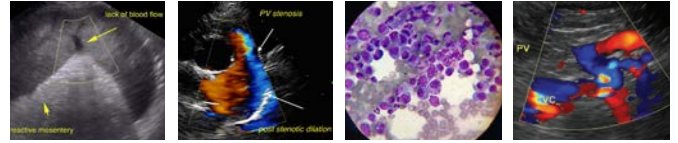
INVOICE

33376

DATE

12/9/21





PATIENT

Sophie Shaika

SPECIES

Feline

BREED

DLH

SEX

Spayed Female

AGE

12 Years

WEIGHT

7.2 Pounds

INTERPRETED BY

Kathleen Sennello DVM,
MS, Diplomate ACVIM
(Small Animal Internal
Medicine)

**IMAGING
PERFORMED BY**

Dr. Tam Mengine

HOSPITAL NAME

Stoney Creek VH

REFERRING VET

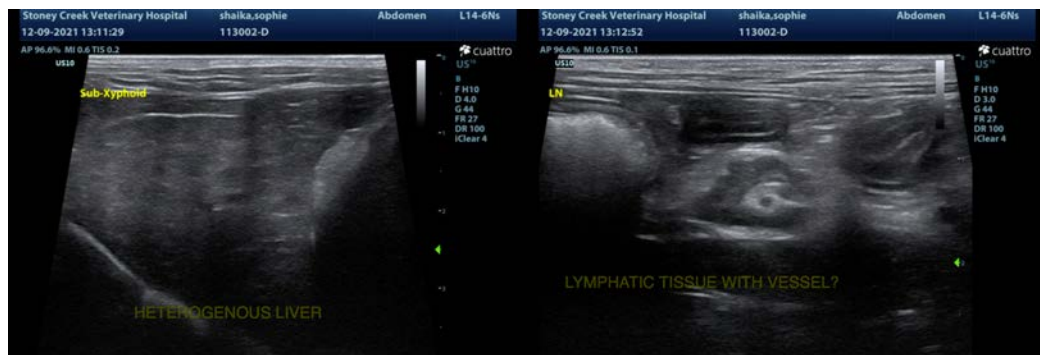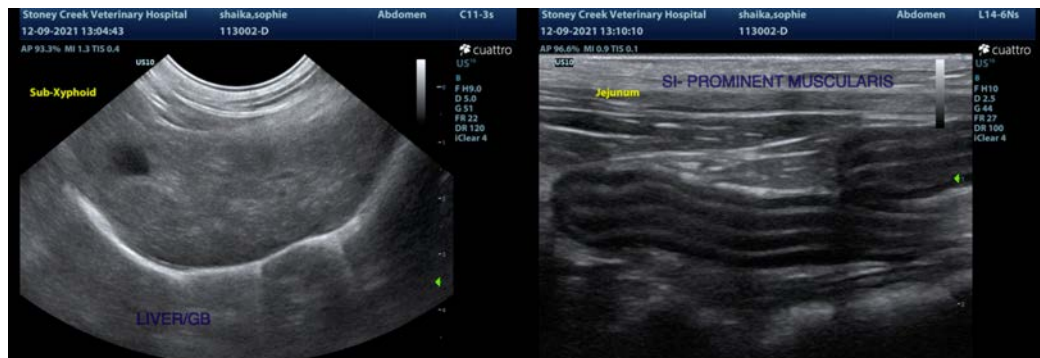
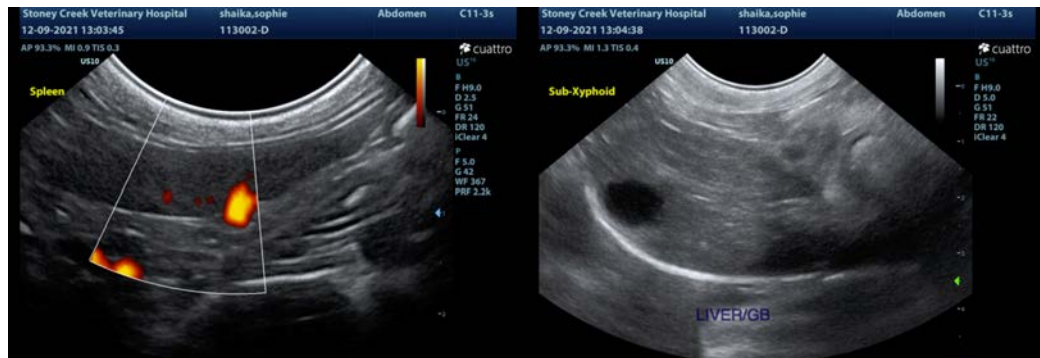
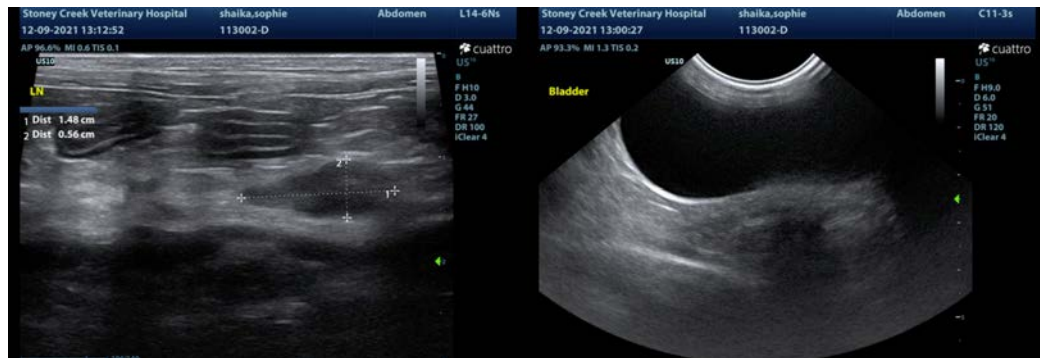
Dr. Tam Mengine

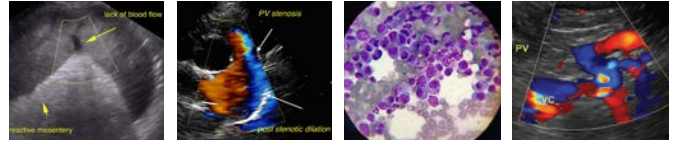
INVOICE

33376

DATE

12/9/21





PATIENT

Sophie Shaika

The information and recommendations provided are based on the images presented by the referring veterinarian. No evaluation can be communicated regarding pathology that was not visible in the image/video clips provided.

SPECIES

Feline

Thank you for this referral. If the clinical or image interpretation does not parallel your findings or if I can be of any further assistance please contact me.

BREED

DLH

Kathleen Sennello DVM,MS, Diplomate ACVIM (Small animal Internal Medicine)
kathleen.sennello@sonopath.com

SEX

Spayed Female

AGE

12 Years

WEIGHT

7.2 Pounds

INTERPRETED BY

Kathleen Sennello DVM,
MS, Diplomate ACVIM
(Small Animal Internal
Medicine)

**IMAGING
PERFORMED BY**

Dr. Tam Mengine

HOSPITAL NAME

Stoney Creek VH

REFERRING VET

Dr. Tam Mengine

INVOICE

33376

DATE

12/9/21