



**PATIENT**

Marley Sterner

**SPECIES**

Canine

**BREED**

Labrador Retriever

**SEX**

Neutered Male

**AGE**

9 Years

**WEIGHT**

82 Pounds

**INTERPRETED BY**

Kathleen Sennello DVM,  
MS, Diplomate ACVIM  
(Small Animal Internal  
Medicine)

**IMAGING  
PERFORMED BY**

Dr. Tiffany Brady

**HOSPITAL NAME**

Shiloh Vet Hospital

**REFERRING VET**

Dr. Tiffany Brady

**INVOICE**

33358

**DATE**

12/8/21

**PRESENTING CLINICAL SIGNS**

Patient experiencing signs of DJD but otherwise healthy. Geriatric blood work to evaluate to start NSAID included an ECG which revealed occasional VPC. Abdominal ultrasound recommended to assess for intrabdominal masses or lesions.

**ULTRASONOGRAPHIC EXAMINATION OF THE ABDOMEN**

**Urinary System**

The urinary bladder is significantly distended with anechoic urine. The Bladder wall, trigone, ureteral papillae and visible urethra (to a depth of 2cm) appear normal with no evidence of wall thickening, mucosal irregularities, masses or cystic calculi.

The visualized areas of prostate and surrounding tissue appear normal. Unfortunately, the prostate is not fully visualized likely due to its intrapelvic location. Correlate with rectal exam findings.

The left kidney has a normal shape and size (6.2 cm). Overall echogenicity is normal with adequate corticomedullary distinction and a typical 1:3 cortex:medulla ratio. There is no evidence of perinephric inflammation or effusion. There is no evidence of pyelectasia, nephroliths, infarcts or hydroureter. Renal vasculature is normal.

The right kidney has a normal shape and size (6.69 cm). Overall echogenicity is normal with adequate corticomedullary distinction and a typical 1:3 cortex:medulla ratio. There is no evidence of perinephric inflammation or effusion. There is no evidence of pyelectasia, nephroliths, infarcts or hydroureter. Renal vasculature is normal.

**Adrenal Glands**

The left adrenal gland is normal/borderline enlarged in size measuring 1.0 cm at the caudal pole. It is observed in its normal position cranial to the left renal artery. It is normal in appearance (uniformly hypoechoic) and shape with no evidence of a mass effect.

The right adrenal gland is normal/borderline enlarged in size measuring 1.2 cm at the caudal pole. It is observed in its normal position between the cranial aspect of the right kidney and the caudal vena cava. It is normal in appearance (uniformly hypoechoic) and shape with no evidence of a mass effect.

**Spleen**

The spleen is subjectively normal in size, echotexture is homogenous, and the splenic capsule is smooth with no irregularities. The blood flow through the hilus and splenic parenchyma appears normal. No focal parenchymal abnormalities are visualized.

**Liver**

The liver is subjectively normal in size, and echogenicity with smooth peripheral margins. The parenchyma is heterogenous in echotexture with subtle, indistinct focal mottling. The visible portions of the vasculature and biliary tract appear normal. No focal nodules or cystic lesions are observed.

The gallbladder was not clearly visualized.

**Gastrointestinal**

The stomach contains minimal luminal contents. It measures at a normal thickness of <0.7cm with some variability due to the presence of rugal folds. The distinction of the gastric wall layers is adequate and there is no impression of reduced peristaltic activity. No masses or focal lesions were observed.



## PATIENT

Marley Sterner

The visualized areas of duodenum, jejunum and ileum have a relatively uniform diameter with minimal fluid distension. Wall thickness is normal. Bowel loops follow a curvilinear path with distinct wall layering maintaining the typical 1:3 muscularis:mucosa layer ratio. The duodenum measured as normal (between 0.3-0.5cm in wall thickness) and the jejunum measured as normal (between 0.2-0.47cm.)

## SPECIES

Canine

Visualized peristalsis appears appropriate. There were no focal lesions consistent with obstruction or a mass effect observed.

## BREED

Labrador Retriever

The ileocecal junction was visualized and exhibited normal intact wall layering and is subjectively of normal thickness. Sections of colon are visualized with formed fecal material and gas shadowing distally. There is no observed focal or generalized colon wall thickening or loss of layering.

## SEX

Neutered Male

### **Pancreas**

The area of the pancreas is normal and isoechoic to surrounding mesentery. There is no evidence of nodules or cystic lesions. There is no evidence of regional mesenteric inflammation or fluid.

### **Free Abdomen**

Evaluation of the peritoneal cavity did not reveal any evidence of effusion, or subjective lymphadenomegaly. The Medial iliac nodes appear normal and there was no evidence of a caudal aortic thrombus at the bifurcation. The omentum is of normal uniform echogenicity.

## AGE

9 Years

## ULTRASONOGRAPHIC FINDINGS

## WEIGHT

82 Pounds

- Subjective borderline bilateral adrenomegaly – The bilateral adrenomegaly could be consistent with bilateral hyperplasia (e.g., secondary to pituitary-dependent hyperadrenocorticism), bilateral infiltrative neoplasia, inflammatory adrenal disease, other. Correlation with clinical findings is recommended.
- Heterogeneous liver – The diffuse hepatic changes are non-specific and could be consistent with vacuolar hepatopathy, nodular hyperplasia, inflammatory/immune-mediated disease, fibrosis, extramedullary hematopoiesis, toxic hepatopathy (e.g., copper), infiltrative neoplasia (less likely) or other hepatopathy.

## INTERPRETED BY

Kathleen Sennello DVM,  
MS, Diplomate ACVIM  
(Small Animal Internal  
Medicine)

## INTERPRETATION OF THE FINDINGS & FURTHER RECOMMENDATIONS

No focal large mass lesions were visualized. This is a big dog, and images were dark in the deeper portions of the abdomen, making visualization difficult. There is the possibility of bilateral adrenomegaly and a heterogeneous liver. Correlate with blood work and current symptoms. This would be unlikely to be related to a cardiac arrhythmia. Recommend 3-view thoracic radiographs and a cardiac consultation and echo.

## IMAGING PERFORMED BY

Dr. Tiffany Brady

## HOSPITAL NAME

Shiloh Vet Hospital

## REFERRING VET

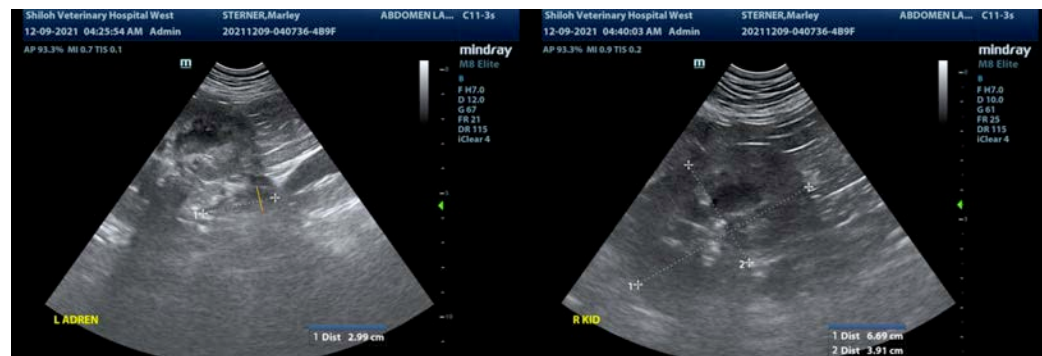Dr. Tiffany Brady

## INVOICE

33358

## DATE

12/8/21





**PATIENT**

Marley Sterner

**SPECIES**

Canine

**BREED**

Labrador Retriever

**SEX**

Neutered Male

**AGE**

9 Years

**WEIGHT**

82 Pounds

**INTERPRETED BY**

Kathleen Sennello DVM,  
MS, Diplomate ACVIM  
(Small Animal Internal  
Medicine)

**IMAGING  
PERFORMED BY**

Dr. Tiffany Brady

**HOSPITAL NAME**

Shiloh Vet Hospital

**REFERRING VET**

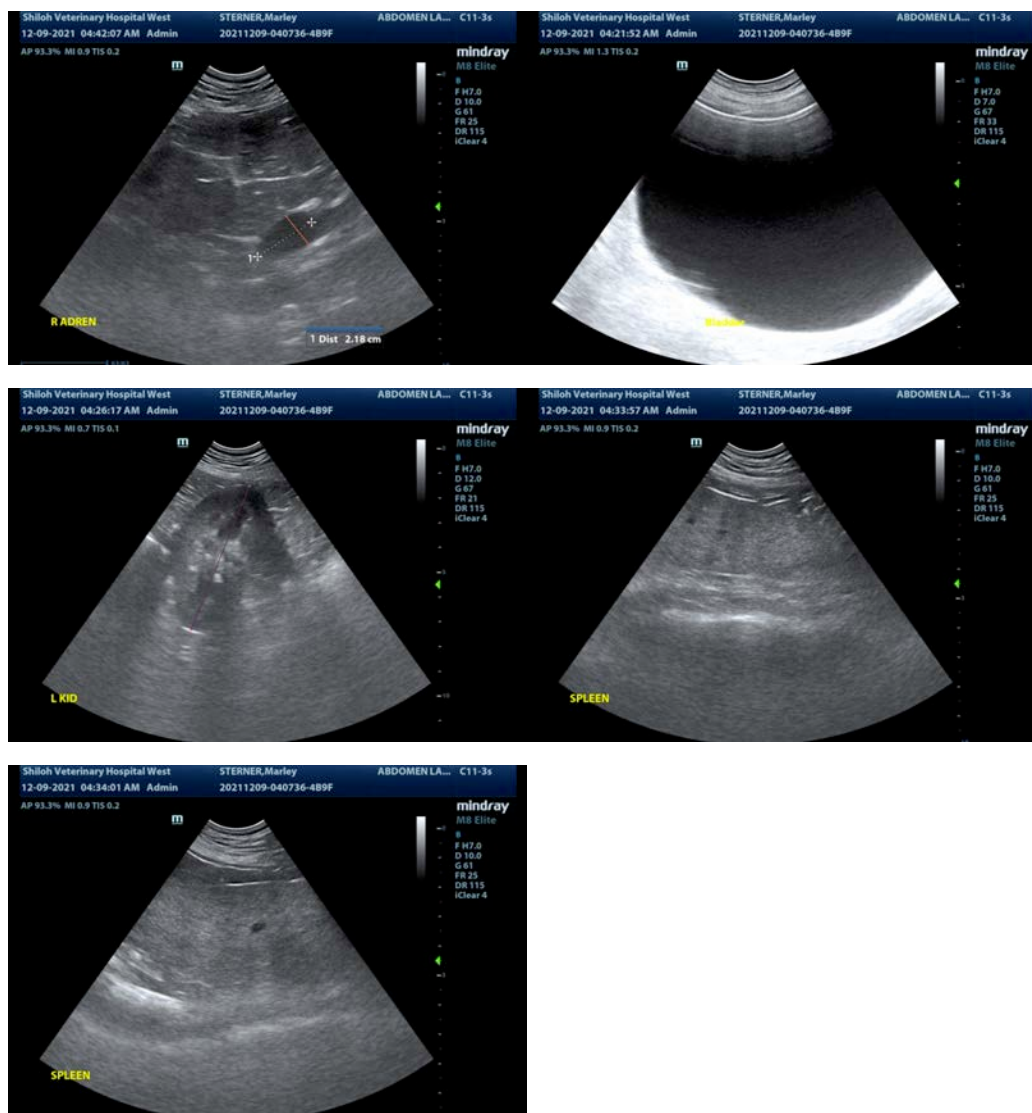
Dr. Tiffany Brady

**INVOICE**

33358

**DATE**

12/8/21



The information and recommendations provided are based on the images presented by the referring veterinarian. No evaluation can be communicated regarding pathology that was not visible in the image/video clips provided.

Thank you for this referral. If the clinical or image interpretation does not parallel your findings or if I can be of any further assistance please contact me.

Kathleen Sennello DVM,MS, Diplomate ACVIM (Small animal Internal Medicine)  
kathleen.sennello@sonopath.com