



PATIENT

Sandy Keller

SPECIES

Canine

BREED

Shetland Sheepdog

SEX

Spayed Female

AGE

4 ½ years

WEIGHT

34.4 lbs

INTERPRETED BY

Kathleen Sennello
DVM, MS, Diplomate
ACVIM (Small Animal
Internal Medicine)

IMAGING PERFORMED BY

Dr. Mengine

HOSPITAL NAME

Stoney Creek VH

REFERRING VET

Dr. Mengine

INVOICE

94353

DATE

12/7/21

PRESENTING CLINICAL SIGNS

History: Elevated ALP on wellness labs in 8/21 (ALP = 572), all else normal. Recheck values in 9/21 - ALP = 763. Recheck in 11/21 - ALP 964, and now ALT slightly elevated at 144 (had been 73 in 8/21). Normal wellness CBC / Chem in 2019 and 2020. Patient started galliprant in 6/21, and adequate in 10/21, for hip dysplasia

ULTRASONOGRAPHIC EXAMINATION OF THE ABDOMEN

Urinary System

The urinary bladder is moderately distended with anechoic urine. The Bladder wall, trigone, ureteral papillae and visible urethra (to a depth of 2cm) appear normal with no evidence of wall thickening, mucosal irregularities, masses or cystic calculi.

The left kidney has a normal shape and size (4.75 cm). Overall echogenicity is normal with adequate corticomedullary distinction and a typical 1:3 cortex:medulla ratio. There is no evidence of perinephric inflammation or effusion. There is no evidence of pyelectasia, nephroliths, infarcts or hydronephrosis. Renal vasculature is normal.

The right kidney has a normal shape and size (5.01 cm). Overall echogenicity is normal with adequate corticomedullary distinction and a typical 1:3 cortex:medulla ratio. There is no evidence of perinephric inflammation or effusion. There is no evidence of pyelectasia, nephroliths, infarcts or hydronephrosis. Renal vasculature is normal.

Adrenal Glands

The left adrenal gland is normal in size measuring 0.52 cm at the caudal pole It is observed in its normal position cranial to the left renal artery. It is normal in appearance (uniformly hypoechoic) and shape with no evidence of a mass effect.

The right adrenal gland is normal in size measuring 0.49 cm at the caudal pole It is observed in its normal position between the cranial aspect of the right kidney and the caudal vena cava. It is normal in appearance (uniformly hypoechoic) and shape with no evidence of a mass effect.

Spleen

The spleen is subjectively normal in size, echotexture is homogenous, and the splenic capsule is smooth with no irregularities. The blood flow through the hilus and splenic parenchyma appears normal. No focal parenchymal abnormalities are visualized.

Liver

The liver is large in size, and echogenicity with smooth peripheral margins. The parenchyma is heterogenous in echotexture with subtle, indistinct focal mottling. The visible portions of the vasculature and biliary tract appear normal. No focal nodules or cystic lesions are observed. The gallbladder lumen is moderately distended. The wall of the gallbladder is not thickened and has a smooth mucosal surface. There is a moderate amount of non-organized echogenic debris. The cystic and common bile ducts are normal/not visible.



PATIENT *Gastrointestinal*

Sandy Keller The stomach contains minimal luminal contents. It measures at a normal thickness of <0.7cm with some variability due to the presence of rugal folds. The distinction of the gastric wall layers is adequate and there is no impression of reduced peristaltic activity. No masses or focal lesions were observed.

SPECIES

Canine

The visualized areas of duodenum, jejunum and ileum have a relatively uniform diameter with minimal fluid distension. Wall thickness is normal. Bowel loops follow a curvilinear path with distinct wall layering maintaining the typical 1:3 muscularis:mucosa layer ratio. The duodenum measured as normal (0.42 cm) and the jejunum measured as normal (0.32 cm). Visualized peristalsis appears appropriate. There were no focal lesions consistent with obstruction or a mass effect observed.

BREED

Shetland Sheepdog

The ileocecal junction was visualized and exhibited normal intact wall layering and is subjectively of normal thickness. The wall measured 0.12 cm. Sections of colon are visualized with formed fecal material and gas shadowing distally. There is no observed focal or generalized colon wall thickening or loss of layering.

SEX

Spayed Female

AGE

4 ½ years

Pancreas

The pancreas is normal and isoechoic to surrounding mesentery. There is no evidence of nodules or cystic lesions. There is no evidence of regional mesenteric inflammation or fluid.

WEIGHT

34.4 lbs

Free Abdomen

Evaluation of the peritoneal cavity did not reveal any evidence of effusion, or subjective lymphadenomegaly. The Medial iliac nodes appear normal and there was no evidence of a caudal aortic thrombus at the bifurcation. The omentum is of normal uniform echogenicity.

INTERPRETED BY

Kathleen Sennello
DVM, MS, Diplomate
ACVIM (Small Animal
Internal Medicine)

ULTRASONOGRAPHIC FINDINGS

PRIMARY FINDINGS:

- Large, hyperechoic heterogenous liver. The diffuse hepatic changes are non-specific and could be consistent with vacuolar hepatopathy, nodular hyperplasia, inflammatory/immune-mediated disease, fibrosis, extramedullary hematopoiesis, toxic hepatopathy (e.g., copper), infiltrative neoplasia (less likely) or other hepatopathy.

IMAGING PERFORMED BY

Dr. Mengine

HOSPITAL NAME

Stoney Creek VH

INTERPRETATION OF THE FINDINGS & FURTHER RECOMMENDATIONS

REFERRING VET

Dr. Mengine

No focal lesions were visualized associated with the liver and the gallbladder changes were very mild. The findings are most consistent with a vacuolar hepatopathy, but other differentials exist. These are my recommendations for a patient with primary ALP elevation.

INVOICE

94353

- Induction phenomena are the most common cause for elevation in ALP. These are systemic illnesses that 'turn on' the liver enzyme. Causes of this include Cushing's disease, dental disease, arthritis, and numerous others. In many cases the exact cause is unclear but as long as ultrasound and bile acids tests are normal most patients do not have progressive changes in their liver. While liver biopsy is not routinely performed, vacuolar hepatopathy, is noted on most biopsies. This is often non-progressive but in rare cases can be more severe and lead to liver failure.

DATE

12/7/21



PATIENT

Sandy Keller

- If signs of Cushing's disease are present recommend endocrine function testing to evaluate for Cushing's disease.

SPECIES

Canine

- Consider fine needle aspirate to rule out round cell neoplasia -if this is a concern.
- If a cause for the ALP elevation is not identified: I recommend recheck general blood work every 6 months, ultrasound once per year, and bile acids test every 1-2 years based on other results. If the ALP continues to climb a biopsy could be considered.

BREED

Shetland Sheepdog

- Consider long term use of Denamarin, and monitoring for the signs of Cushing's developing.

SEX

Spayed Female

- A primary vacuolar hepatopathy can be breed related and is seen in Scottish Terriers, Schnauzers, Cocker spaniels etc..

AGE

4 ½ years

WEIGHT

34.4 lbs

INTERPRETED BY

Kathleen Sennello
DVM, MS, Diplomate
ACVIM (Small Animal
Internal Medicine)

IMAGING PERFORMED BY

Dr. Mengine

HOSPITAL NAME

Stoney Creek VH

REFERRING VET

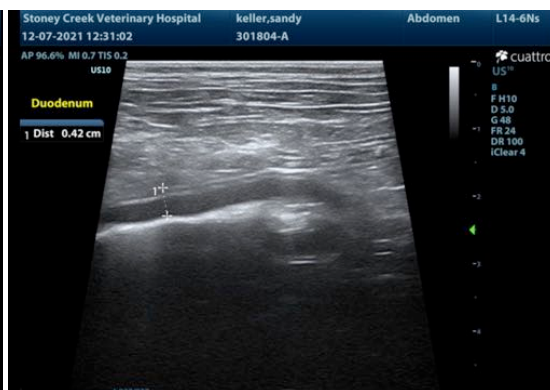
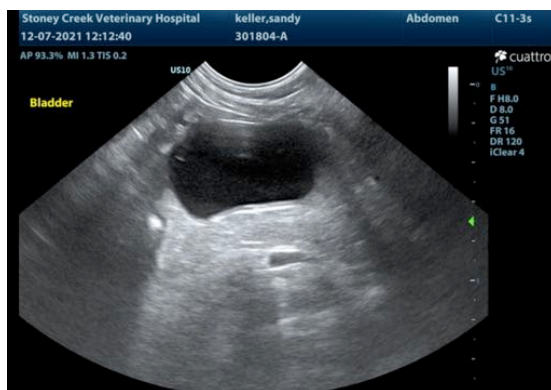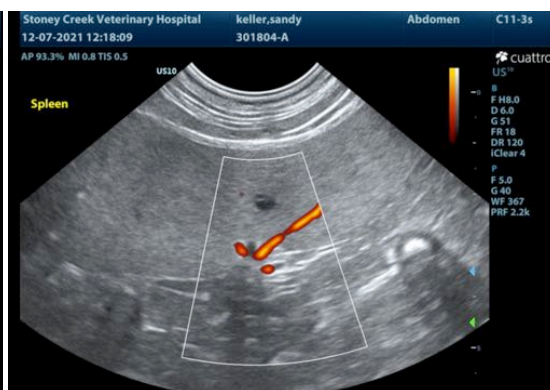
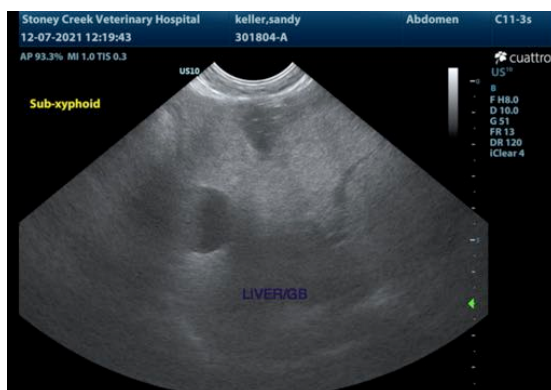Dr. Mengine

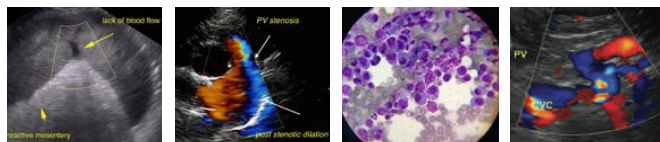
INVOICE

94353

DATE

12/7/21





PATIENT

Sandy Keller

SPECIES

Canine

BREED

Shetland Sheepdog

SEX

Spayed Female

AGE

4 ½ years

WEIGHT

34.4 lbs

INTERPRETED BY

Kathleen Sennello
DVM, MS, Diplomate
ACVIM (Small Animal
Internal Medicine)

IMAGING PERFORMED BY

Dr. Mengine

HOSPITAL NAME

Stoney Creek VH

REFERRING VET

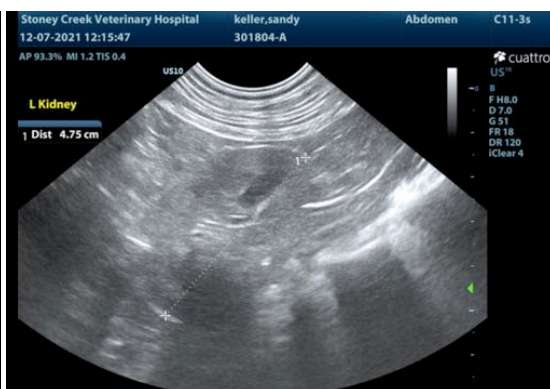
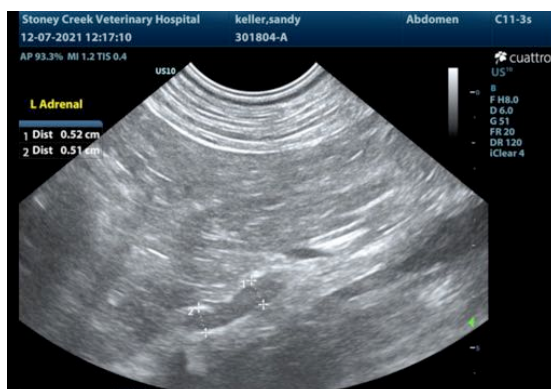
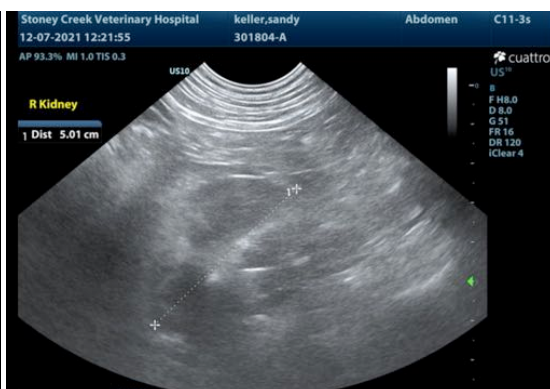
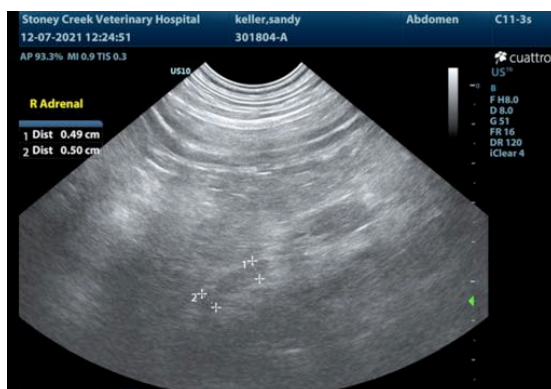
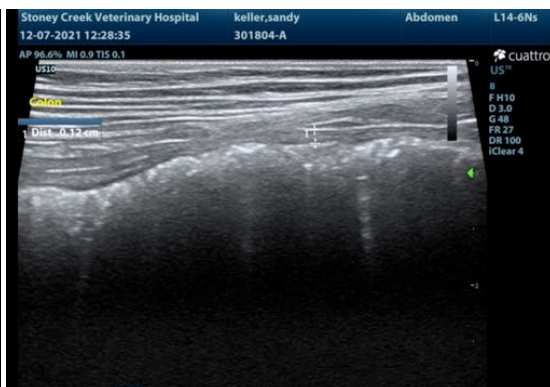
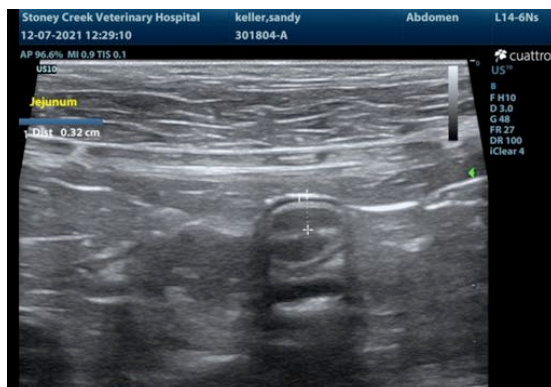Dr. Mengine

INVOICE

94353

DATE

12/7/21



The information and recommendations provided are based on the images presented by the referring veterinarian. No evaluation can be communicated regarding pathology that was not visible in the image/video clips provided.

Thank you for this referral. If the clinical or image interpretation does not parallel your findings or if I can be of any further assistance please contact me.

Kathleen Sennello DVM,MS, Diplomate ACVIM (Small animal Internal Medicine)
kathleen.sennello@sonopath.com