

**DATE PRESENTING CLINICAL SIGNS**

12/7/21 History: Acute history of ADR, lethargy, vomiting, not eating but drinking more, loose bowels. BW revealed hyperthyroidism as well as elevated liver enzymes and bilirubin suggestive of hepatobiliary disease.

PATIENT

Sadie Countess Current Medications: Methimazole 5mg/0.05ml - 0.05mL (2 full pen rotations) to inside of ear flap TWICE daily.

SPECIES

Feline

Lab Results: BW revealed hyperthyroidism as well as elevated liver enzymes and bilirubin suggestive of hepatobiliary disease. Attached separately.

Date of Previous IntraPet Ultrasound: No previous IntraPet scans.

Sedation: Patient sedated with Telazole.

Stat Report: Not requested.

BREED

DSH

ULTRASONOGRAPHIC EXAMINATION OF THE ABDOMEN**SEX**

Spayed Female

Urinary System

The urinary bladder is moderately distended with anechoic urine. The Bladder wall, trigone, ureteral papillae and visible urethra (to a depth of 2cm) appear normal with no evidence of wall thickening, mucosal irregularities, masses or cystic calculi.

AGE

4/1/08

The left kidney has a normal shape and size (3.95 cm). Overall echogenicity is normal with adequate corticomedullary distinction and a typical 1:3 cortex:medulla ratio. There is no evidence of perinephric inflammation or effusion. There is no evidence of pyelectasia, nephroliths, infarcts or hydroureter. Renal vasculature is normal.

WEIGHT

10.2 Pounds

The right kidney has a normal shape and size (3.97 cm). Overall echogenicity is normal with adequate corticomedullary distinction and a typical 1:3 cortex:medulla ratio. There is no evidence of perinephric inflammation or effusion. There is no evidence of pyelectasia, nephroliths, infarcts or hydroureter. Renal vasculature is normal.

INTERPRETED BY

Kathleen Sennello DVM,
MS, Diplomate ACVIM
(Small Animal Internal
Medicine)

Adrenal Glands

The left adrenal gland is normal in size measuring 0.46 cm at the caudal pole. It is observed in its normal position cranial to the left renal artery. It is normal in appearance (uniformly hypoechoic) and shape with no evidence of a mass effect.

IMAGING PERFORMED BY

Andi Parkinson RDMS

The right adrenal gland is normal in size measuring 0.43 cm at the caudal pole. It is observed in its normal position between the cranial aspect of the right kidney and the caudal vena cava. It is normal in appearance (uniformly hypoechoic) and shape with no evidence of a mass effect.

HOSPITAL NAME

Creswell Vet Hospital

Spleen

The spleen is subjectively normal in size, echotexture is homogenous, and the splenic capsule is smooth with no irregularities. The blood flow through the hilus and splenic parenchyma appears normal. No focal parenchymal abnormalities are visualized.

REFERRING VET

Dr. Cullum

Liver

The liver is subjectively normal in size, and echogenicity with smooth peripheral margins. The parenchyma is heterogenous in echotexture with subtle, indistinct focal mottling. The visible portions of the vasculature and biliary tract appear normal. No focal nodules or cystic lesions are observed.

INVOICE

33318

The gallbladder lumen is moderately distended. The wall of the gall bladder is not thickened and has a smooth mucosal surface. Luminal contents are primarily anechoic. The cystic and common bile ducts are normal/not visible.

Gastrointestinal

The stomach contains minimal luminal contents. It measures at a normal thickness of <0.36cm with some variability due to the presence of rugal folds. The distinction of the gastric wall layers is adequate and there is no impression of reduced peristaltic activity. No masses or focal lesions were observed.

The visualized areas of duodenum, jejunum and ileum have a relatively uniform diameter with minimal fluid distension. Wall thickness is normal. Bowel loops follow a curvilinear path with distinct wall layering maintaining the typical 1:3 muscularis:mucosa layer ratio. Jejunum wall measured 0.23 cm. Visualized peristalsis appears appropriate. There were no focal lesions consistent with obstruction or a mass effect observed.

The ileocecal junction was visualized and exhibited normal intact wall layering and is subjectively of normal thickness. Sections of colon are visualized with formed fecal material and gas shadowing distally. There is no observed focal or generalized colon wall thickening or loss of layering.

Pancreas

The pancreas is prominent and mottled compared to the surrounding isoechoic mesentery. There is no evidence of nodules or cystic lesions. There is no evidence of regional mesenteric inflammation or fluid.

Free Abdomen

Evaluation of the peritoneal cavity did not reveal any evidence of effusion, or subjective lymphadenomegaly. The Medial iliac nodes appear normal and there was no evidence of a caudal aortic thrombus at the bifurcation. The omentum is of increased echogenicity around the liver.

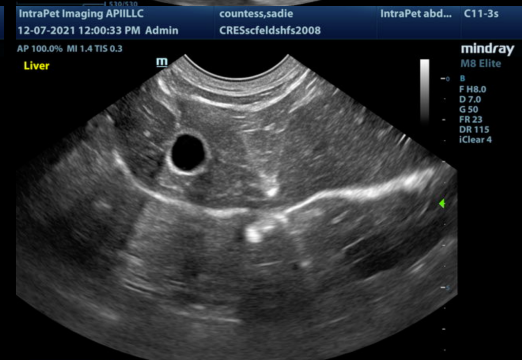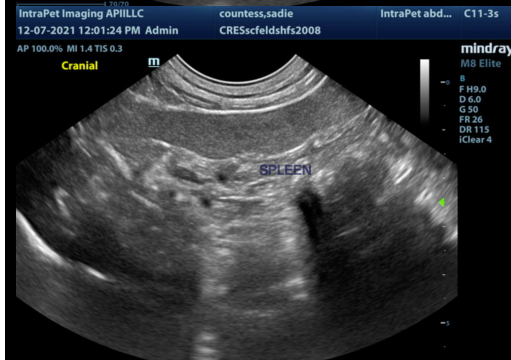
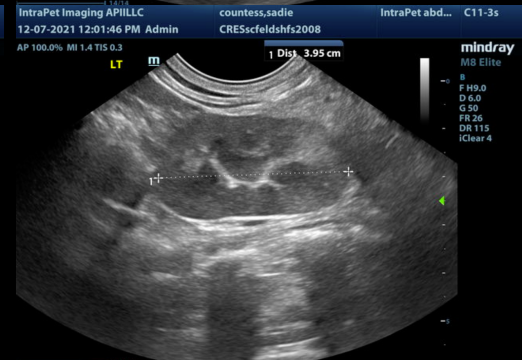
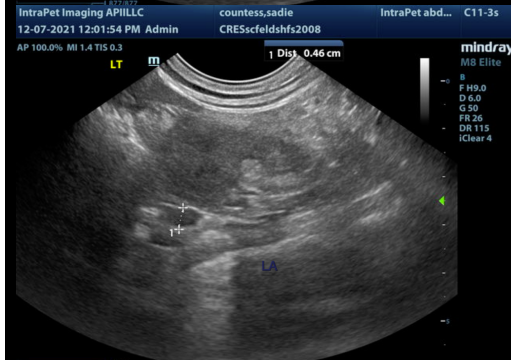
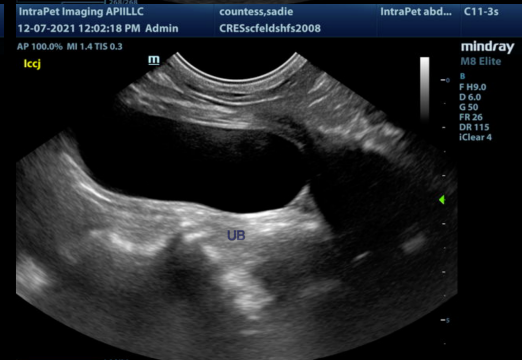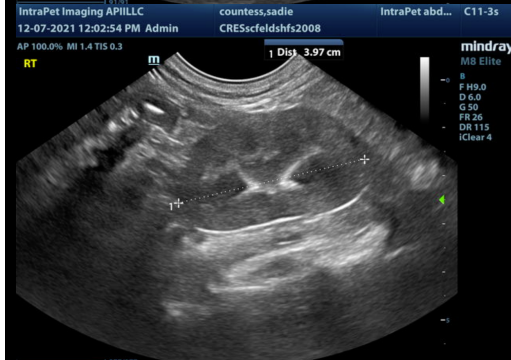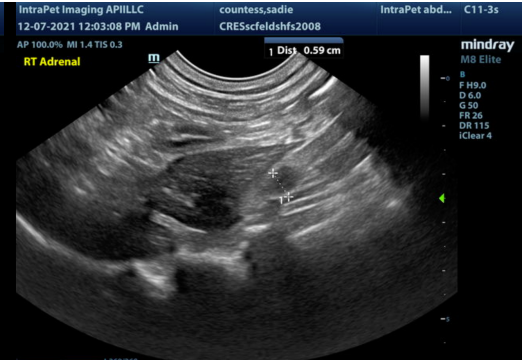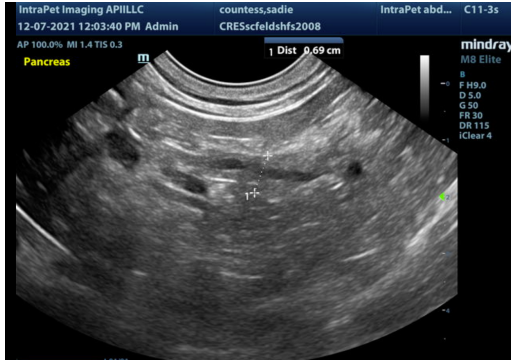ULTRASONOGRAPHIC FINDINGS

- Heterogeneous liver with surrounding hyperechoic mesentery – The diffuse hepatic changes are non-specific and could be consistent with vacuolar hepatopathy, nodular hyperplasia, inflammatory/immune-mediated disease, fibrosis, extramedullary hematopoiesis, toxic hepatopathy (e.g., copper), infiltrative neoplasia (less likely) or other hepatopathy.
- Prominent, mottled pancreas – The pancreatic changes are most consistent with age-related parenchymal remodeling, potentially secondary to a prior inflammatory episode, early fibrosis or chronic pancreatitis.

INTERPRETATION OF THE FINDINGS & FURTHER RECOMMENDATIONS

The ultrasonographic lesions visualized were relatively mild, non-specific, and subjective. Lab work is consistent with a hepatobiliary disease, and the ultrasound is supportive of primary hepatic disease, as the biliary tract appears relatively normal. No focal lesions were visualized associated with the liver. Additionally, systemic causes such as hyperthyroidism, toxicity, FIP, etc. should be considered.

- Consider close evaluation of history for possible toxic changes examine medications, diet, dietary indiscretion etc..
- Recommend thyroid evaluation (if not already done)
- If not already done consider pre and post prandial bile acids to evaluate liver function
- Consider fine needle aspirate if round cell neoplasia is on your differential list (25 g needle, normal coags)
- If cytology is not helpful and there is no response to therapy, consider liver biopsy with samples obtained for histopathology and culture.
- If triaditis is suspected consider therapy for cholangiohepatitis (fluids, antibiotics , +/- ursodiol,+/- steroids), testing for pancreatitis and evaluation for IBD (GI panel to Texas A&M GI lab)
- Consider a feeding tube if patient is not eating for a prolonged period of time



The information and recommendations provided are based on the images presented by the referring veterinarian. No evaluation can be communicated regarding pathology that was not visible in the image/video clips provided.

Thank you for this referral. If the clinical or image interpretation does not parallel your findings or if I can be of any further assistance please contact me.

Kathleen Sennello DVM,MS, Diplomate ACVIM (Small animal Internal Medicine)
kathleen.sennello@sonopath.com