



**PATIENT PRESENTING CLINICAL SIGNS**

**PATIENT**  
Nestle Kelley

**SPECIES**  
Canine

Dog is doing well and having no problems but noted elevated SDMA on routine bloodwork. Follow up bloodwork 1 mo later showed SDMA increasing. O wanted to be proactive and so elected to do abdominal ultrasound. Concerned about congenital renal disease specifically polycystic kidney disease. Dog is non-clinical at this time. BCS is 4/9 but dog is very active.  
Abnormal PE/Chem/CBC/UA Results: SDMA 16 then 1 mo later was 22. Crea and BUN are normal. UA normal with 1.048 sg and trace protein, sediment inactive.

**BREED ULTRASONOGRAPHIC EXAMINATION OF THE ABDOMEN**

**BREED**  
German Shepherd

**Urinary System**

**SEX**  
Spayed Female

The urinary bladder is moderately distended with anechoic urine. The Bladder wall, trigone, ureteral papillae and visible urethra (to a depth of 2cm) appear normal with no evidence of wall thickening, mucosal irregularities, masses or cystic calculi.

**AGE**  
2 Years

The left kidney has a normal shape and size (8.4 cm) and a 2.6 cm x 2.75 cm cystic lesion in the caudal pole. Overall echogenicity is slightly hyperechoic with mildly reduced corticomedullary distinction and a typical 1:3 cortex:medulla ratio. There is no evidence of perinephric inflammation or effusion. There is no evidence of pyelectasia, nephroliths, infarcts or hydroureter. Renal vasculature is normal.

**WEIGHT**  
67 Pounds

The right kidney has a normal shape and size (8.5 cm). Overall echogenicity is slightly hyperechoic with mildly reduced corticomedullary distinction and a typical 1:3 cortex:medulla ratio. There is no evidence of perinephric inflammation or effusion. There is no evidence of pyelectasia, nephroliths, infarcts or hydroureter. Renal vasculature is normal.

**Adrenal Glands**

**INTERPRETED BY**  
Kathleen Sennello DVM, MS, Diplomate ACVIM (Small Animal Internal Medicine)

The region of left adrenal (Cranial to left renal artery) is unremarkable but the adrenal is not distinctly visualized. No evidence of a mass effect.

The region of the right adrenal (between right cranial kidney and vena cava) is unremarkable, but the adrenal is not distinctly visualized. No evidence of a mass effect.

**IMAGING PERFORMED BY**  
Dr. Daniel Finch

**Spleen**

The spleen is subjectively normal in size, echotexture is homogenous, and the splenic capsule is smooth with no irregularities. The blood flow through the hilus and splenic parenchyma appears normal. No focal parenchymal abnormalities are visualized.

**HOSPITAL NAME**  
Neighborhood Pet Health Center

**Liver**

The liver is subjectively normal in size, and echogenicity with smooth peripheral margins. The parenchyma is homogenous echotexture. The visible portions of the vasculature and biliary tract appear normal. No focal nodules or cystic lesions are observed.

**REFERRING VET**  
Dr. Russell Johnson

The gallbladder lumen is moderately distended. The wall of the gall bladder is not thickened and has a smooth mucosal surface. Luminal contents are primarily anechoic. The cystic and common bile ducts are normal/not visible.

**INVOICE**  
33331

**Gastrointestinal**

The stomach contains minimal luminal contents. It measures at a normal thickness of <0.7cm with some variability due to the presence of rugal folds. The distinction of the gastric wall layers is adequate and there is no impression of reduced peristaltic activity. No masses or focal lesions were observed.

**DATE**  
12/7/21



**PATIENT**

Nestle Kelley

The visualized areas of duodenum, jejunum and ileum have a relatively uniform diameter with minimal fluid distension. Wall thickness is normal. Bowel loops follow a curvilinear path with distinct wall layering maintaining the typical 1:3 muscularis:mucosa layer ratio. The duodenum measured as normal (between 0.3-0.5cm in wall thickness) and the jejunum measured as normal (between 0.2-0.47cm.)

**SPECIES**

Canine

Visualized peristalsis appears appropriate. There were no focal lesions consistent with obstruction or a mass effect observed.

**BREED**

German Shepherd

The ileocecal junction was visualized and exhibited normal intact wall layering and is subjectively of normal thickness. Sections of colon are visualized with formed fecal material and gas shadowing distally. There is no observed focal or generalized colon wall thickening or loss of layering.

**Pancreas**

**SEX**

Spayed Female

The pancreas is normal and isoechoic to surrounding mesentery. There is no evidence of nodules or cystic lesions. There is no evidence of regional mesenteric inflammation or fluid.

**Free Abdomen**

**AGE**

2 Years

Evaluation of the peritoneal cavity did not reveal any evidence of effusion, or subjective lymphadenomegaly. The Medial iliac nodes appear normal and there was no evidence of a caudal aortic thrombus at the bifurcation. The omentum is of normal uniform echogenicity.

**ULTRASONOGRAPHIC FINDINGS**

**WEIGHT**

67 Pounds

- Mild/questionable decrease in corticomedullary distinction in both kidneys with a left-sided cortical cyst in the caudal pole – most consistent with mildly dysplastic kidneys due to age of the patient.

**INTERPRETATION OF THE FINDINGS & FURTHER RECOMMENDATIONS**

**INTERPRETED BY**

Kathleen Sennello DVM,  
MS, Diplomate ACVIM  
(Small Animal Internal  
Medicine)

These kidneys appear relatively normal aside from the left-sided cyst. Subjectively, I feel the architecture is slightly less crisp than you should see in this young of a dog, so there could be some mild changes. There is a cystic lesion in the caudal pole of the left kidney. This is somewhat ill-defined, and is most likely consistent with a renal cyst, which can be seen with renal dysplasia in young dogs. Other differentials include cystadenoma/adenocarcinoma, which is seen in German Shepherd dogs along with nodular dermatitis. This seems less likely as this is a very young dog for renal cancer. Lastly, an abscess could be a differential, but seems unlikely. If nodular skin lesions are present, then my concern for a renal cystadenocarcinoma would be greatly increased. I believe there is a genetic test for this possibility, which will be added at the end of this report.

**IMAGING PERFORMED BY**

Dr. Daniel Finch

**HOSPITAL NAME**

Neighborhood Pet  
Health Center

If not already done, recommend urinalysis and culture. Recommend continued monitoring of the renal cyst and renal values. Consider screening for Leptospirosis, and recommend screening for Addison's disease due to the eosinophilia reported.

**REFERRING VET**

Dr. Russell Johnson

**Genetic Test:** A genetic test for the mutation on the FLCN gene is available from [AnimaLabs](#), [VetGen](#), [PawPrint Genetics](#), and [UC Davis Veterinary Genetics Laboratory](#) in the USA, and from [LABOKLIN](#) in the UK. (information from VIN 2019 so may have changed)

**INVOICE**

33331

**DATE**

12/7/21



**PATIENT**

Nestle Kelley

**SPECIES**

Canine

**BREED**

German Shepherd

**SEX**

Spayed Female

**AGE**

2 Years

**WEIGHT**

67 Pounds

**INTERPRETED BY**

Kathleen Sennello DVM,  
MS, Diplomate ACVIM  
(Small Animal Internal  
Medicine)

**IMAGING  
PERFORMED BY**

Dr. Daniel Finch

**HOSPITAL NAME**

Neighborhood Pet  
Health Center

**REFERRING VET**

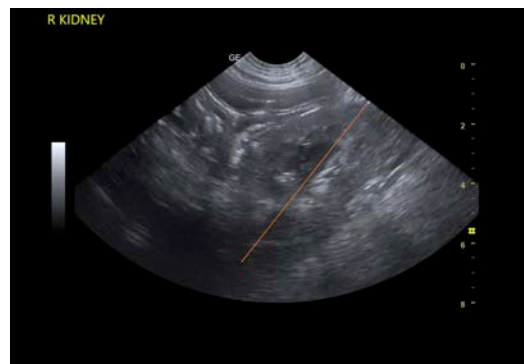
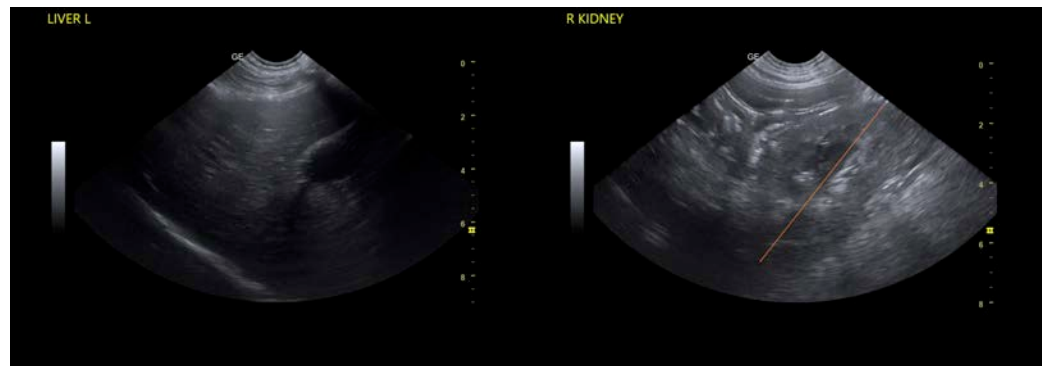
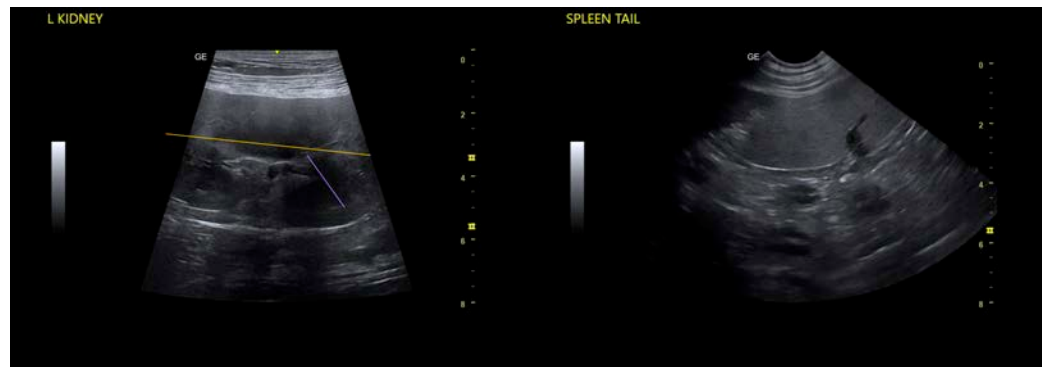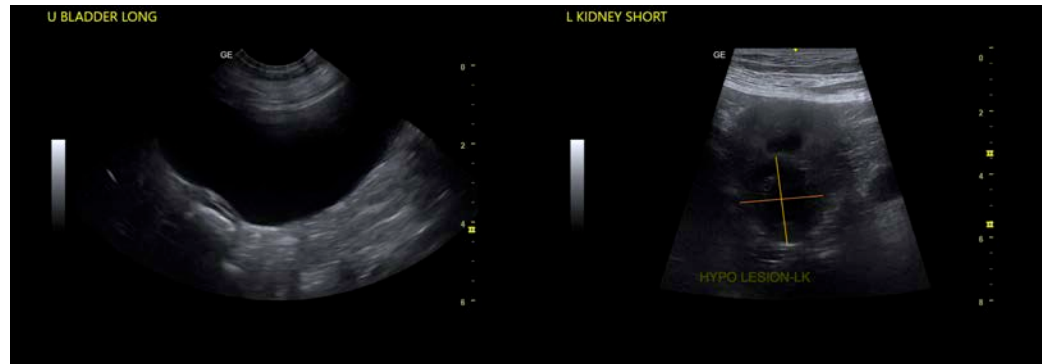Dr. Russell Johnson

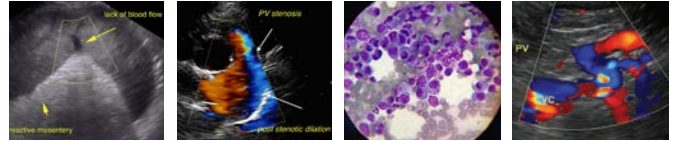
**INVOICE**

33331

**DATE**

12/7/21





**PATIENT**

Nestle Kelley

The information and recommendations provided are based on the images presented by the referring veterinarian. No evaluation can be communicated regarding pathology that was not visible in the image/video clips provided.

**SPECIES**

Canine

Thank you for this referral. If the clinical or image interpretation does not parallel your findings or if I can be of any further assistance please contact me.

**BREED**

German Shepherd

Kathleen Sennello DVM,MS, Diplomate ACVIM (Small animal Internal Medicine)  
kathleen.sennello@sonopath.com

**SEX**

Spayed Female

**AGE**

2 Years

**WEIGHT**

67 Pounds

**INTERPRETED BY**

Kathleen Sennello DVM,  
MS, Diplomate ACVIM  
(Small Animal Internal  
Medicine)

**IMAGING  
PERFORMED BY**

Dr. Daniel Finch

**HOSPITAL NAME**

Neighborhood Pet  
Health Center

**REFERRING VET**

Dr. Russell Johnson

**INVOICE**

33331

**DATE**

12/7/21