

**DATE PRESENTING CLINICAL SIGNS**

12/7/21 History: Nate has been having episodes of hematuria, stranguria and pollakiuria. The previous ultrasound showed some possible small stones in the bladder and some non-obstructive nephroliths. The question is whether he seems to be passing the nephroliths or are the stones in the bladder increasing in size/number.

PATIENT

Nate Armstrong Current Medications: 25 mg Gabapentin BID, 100mls fluids SID, 1/4 tablet of Cerenia SID, 1/4 Pepcid sid, 1mg Budesonide SID, Potassium powder 2mEq sid-BID.

SPECIES

Feline

Lab Results: A urine culture was negative.
Date of Previous IntraPet Ultrasound: 10-5-2021.
Sedation: Not required to complete full diagnostic ultrasound.
Stat Report: Not requested.

BREED

DSH

ULTRASONOGRAPHIC EXAMINATION OF THE ABDOMEN**SEX**

Neutered Male

Urinary System

The urinary bladder is moderately distended with anechoic urine. The Bladder wall, trigone, ureteral papillae and visible urethra (to a depth of 2cm) appear normal with no evidence of wall thickening, mucosal irregularities, or masses. There is a small band of sandy debris in the dependent portion of the urinary bladder. This similar to previous scan 10/5/21. There is no associated evidence of cystitis.

AGE

3/17/05

The left kidney has a normal shape and size (3.52 cm) with apparent non-obstructive nephroliths, one measuring 0.25 cm. There is pyelectasia at 0.42 cm (previous pyelectasia was measured at 0.45 cm, this appears stable). Overall echogenicity is slightly hyperechoic with poor corticomedullary distinction and a typical 1:3 cortex:medulla ratio. There is no evidence of perinephric inflammation or effusion. There is no evidence of infarcts or hydroureter. Renal vasculature is normal.

WEIGHT

6 Pounds

The right kidney has a normal shape and size (3.7 cm) with non-obstructive nephroliths visualized in addition to small nephroliths visualized within the renal pelvis. Pyelectasia noted at 0.48 cm (right-sided renal pelvic dilation appears more severe than previous scan measurement on 10/5/21, which was between 0.25 and 0.17 cm. Overall echogenicity is slightly hyperechoic with poor corticomedullary distinction and a typical 1:3 cortex:medulla ratio. There is no evidence of perinephric inflammation or effusion. There is no evidence of infarcts or hydroureter. Renal vasculature is normal.

INTERPRETED BY

Kathleen Sennello DVM,
MS, Diplomate ACVIM
(Small Animal Internal
Medicine)

Adrenal Glands

The region of left adrenal (Cranial to left renal artery) is unremarkable but the adrenal is not distinctly visualized. No evidence of a mass effect.

IMAGING PERFORMED BY

Rachel Brillhart RDMS

The region of the right adrenal (between right cranial kidney and vena cava) is unremarkable, but the adrenal is not distinctly visualized. No evidence of a mass effect.

HOSPITAL NAME

Cat Sense Feline AH

Spleen

The spleen is subjectively normal in size, echotexture is homogenous, and the splenic capsule is smooth with no irregularities. The blood flow through the hilus and splenic parenchyma appears normal. No focal parenchymal abnormalities are visualized.

REFERRING VET

Dr. Sinclair

Liver

The liver is subjectively normal in size, and echogenicity with smooth peripheral margins. The parenchyma is homogenous echotexture. The visible portions of the vasculature and biliary tract appear normal. No focal nodules or cystic lesions are observed.

INVOICE

33315

The gallbladder lumen is moderately distended. The wall of the gall bladder is not thickened and has a smooth mucosal surface. Luminal contents are primarily anechoic. A diffusely dilated common bile duct is visualized measuring 0.46 cm. This is stable from the last scan on 10/5/21.

Gastrointestinal

The stomach contains minimal luminal contents. It measures at a normal thickness of <0.36cm with some variability due to the presence of rugal folds. The distinction of the gastric wall layers is adequate and there is no impression of reduced peristaltic activity. No masses or focal lesions were observed.

The visualized areas of duodenum, jejunum and ileum have a uniform diameter with minimal fluid distension. Wall thickness is normal to slightly increased. Bowel loops follow a typical curvilinear path with distinct wall layering, but some areas display a prominent muscularis layer which does not display the typical 1:3 muscularis:mucosa layer ratio. Jejunum wall measured 0.25, 0.28 cm. Visualized peristalsis appears appropriate. There were no focal lesions consistent with obstruction or a mass effect observed.

The ileocecal junction was visualized and exhibited normal intact wall layering and is subjectively of normal thickness. Sections of colon are visualized with formed fecal material and gas shadowing distally. There is no observed focal or generalized colon wall thickening or loss of layering.

Pancreas

The pancreas is large, prominent and hypoechoic as compared to the surrounding isoechoic mesentery. There is no evidence of nodules or cystic lesions. There is no evidence of regional mesenteric inflammation or fluid. The pancreatic duct is severely dilated, measuring 0.51 cm. This appearance is stable with possible very mild questionable progression of the pancreatic duct dilation.

Free Abdomen

Scant anechoic free fluid is present. Prominent mesenteric lymph nodes are visualized with one measuring 0.48 cm x 1.28 cm in the caudal abdomen. The omentum is generally of normal echogenicity.

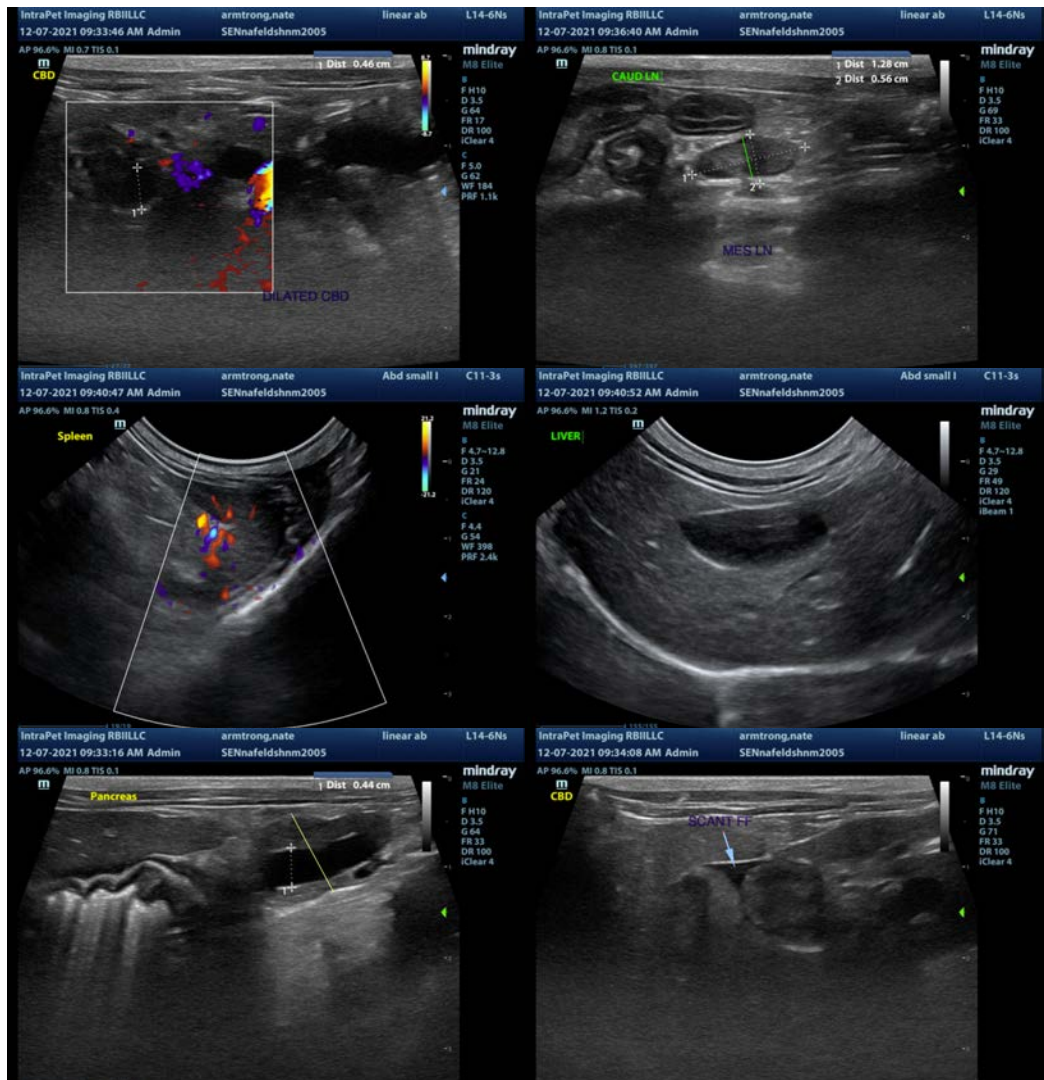
ULTRASONOGRAPHIC FINDINGS

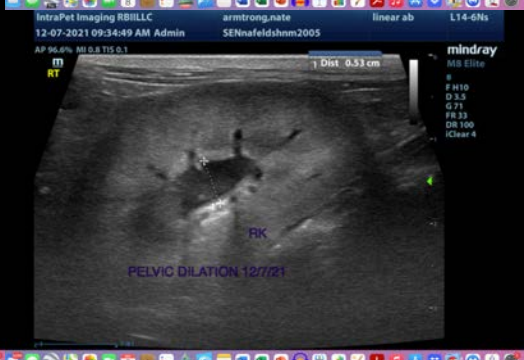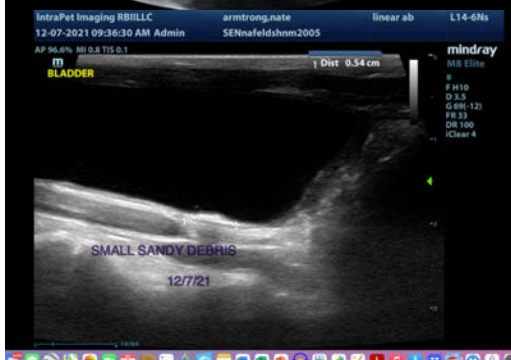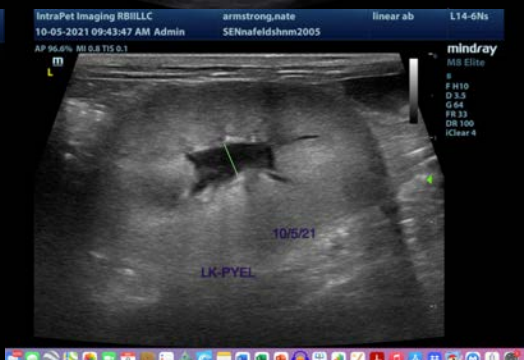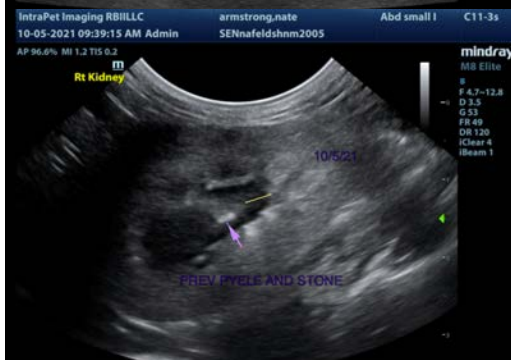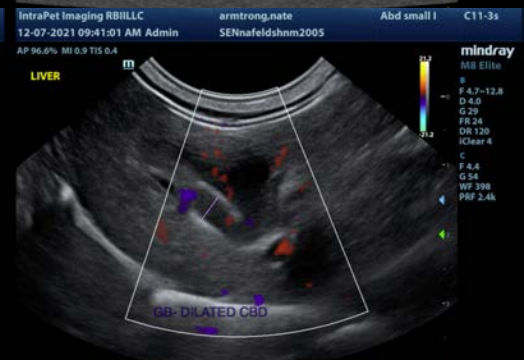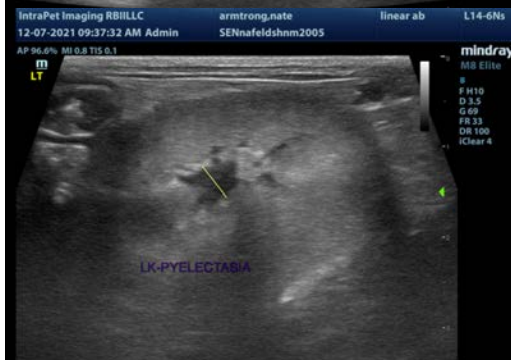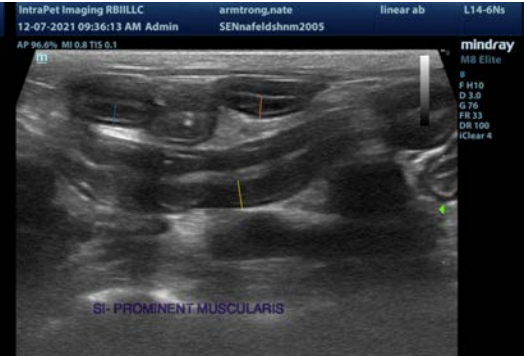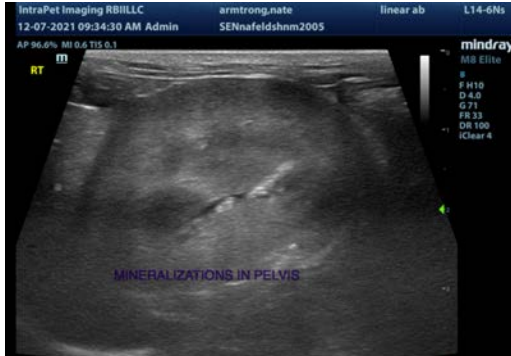- Sandy debris in the dependent portion of the urinary bladder – This is mild with no apparent cystitis and is stable from the last scan.
- Decreased corticomedullary distinction in both kidneys with bilateral pyelectasia and non-obstructive nephroliths. There is no obvious pinpoint obstruction visualized in either kidney, and no obvious ureteral dilation. There are some stones visualized in the pelvis of the right kidney with evidence of progressive dilation, so this may be consistent with a partial obstruction. Also consider pyelonephritis as a differential.
- Prominent, hypoechoic pancreas with severely dilated pancreatic duct – This is stable from the last scan. Recommend quantitative fPLI through Texas A&M University as a GI panel to follow levels and assess for inflammation. No obvious obstruction noted.
- Mildly prominent muscularis layer to the small intestine – The small intestinal wall changes are most consistent with an inflammatory process (i.e., inflammatory bowel disease) with a low possibility of emerging lymphoma.
- Scant anechoic free fluid visualized – This is a new finding.
- Prominent mesenteric lymph nodes – Subjectively these lymph nodes appear larger than the last scan.

INTERPRETATION OF THE FINDINGS & FURTHER RECOMMENDATIONS

The urinary tract findings are relatively stable on today's scan. There is mild progression of the right-sided pyelectasia, and some stones within the renal pelvis, so this could be contributing, and is difficult to assess how much the sandy debris in the urinary bladder is causing an issue, but it appears relatively benign. You could consider a contrast CT scan, as this will better assess true obstruction by the stones present. Recommend urinalysis and culture.

The changes associated with the pancreas, common bile duct and small intestine are relatively stable. If this patient is losing weight, then refer back to previous recommendations including a GI panel, possible fine needle aspirate of the pancreas. The lymph nodes appear somewhat more prominent. Therefore, an aspirate of a caudal mesenteric lymph node might be possible at this point. Consider obtaining GI biopsies.





The information and recommendations provided are based on the images presented by the referring veterinarian. No evaluation can be communicated regarding pathology that was not visible in the image/video clips provided.

Thank you for this referral. If the clinical or image interpretation does not parallel your findings or if I can be of any further assistance please contact me.

Kathleen Sennello DVM,MS, Diplomate ACVIM (Small animal Internal Medicine)
kathleen.sennello@sonopath.com