



**PATIENT**

Moose Corbett

**SPECIES**

Canine

**BREED**

German Shepherd

**SEX**

Neutered Male

**AGE**

3.5 Years

**WEIGHT**

45.1 kg

**INTERPRETED BY**

Kathleen Sennello DVM,  
MS, Diplomate ACVIM  
(Small Animal Internal  
Medicine)

**IMAGING  
PERFORMED BY**

Dr. Trudeau

**HOSPITAL NAME**

Pet Works VH

**REFERRING VET**

Dr. Trudeau

**INVOICE**

33311

**DATE**

12/7/21

**PRESENTING CLINICAL SIGNS**

urinating in his sleep, looking for polyp, ectopic ureters - - the ureteral opening was visible on u/s and the injection of urine was noted but I could not time it properly with the video  
Abnormal PE/Chem/CBC/UA Results: U/A with culture - pending CBC/Chem - WNL except the Crea level is high normal at 158 (44 -159umol/L)

**LIMITED ULTRASONOGRAPHIC EXAMINATION**

The urinary bladder is moderately distended with anechoic urine. The Bladder wall, trigone, ureteral papillae and visible urethra (to a depth of 2cm) appear normal with no evidence of wall thickening, mucosal irregularities, masses or cystic calculi.

The prostate is normal in size (1.24 cm) and shape for this neutered male dog. The parenchyma is homogenous and the external margins are smooth. The prostatic urethra appears normal with no evidence of irregularity, invasion, mass effect or calculi.

The left kidney has a normal shape and size (6.16 cm). Overall echogenicity is normal with adequate corticomedullary distinction and a typical 1:3 cortex:medulla ratio. There is no evidence of perinephric inflammation or effusion. There is no evidence of pyelectasia, nephroliths, infarcts or hydroureter. Renal vasculature is normal.

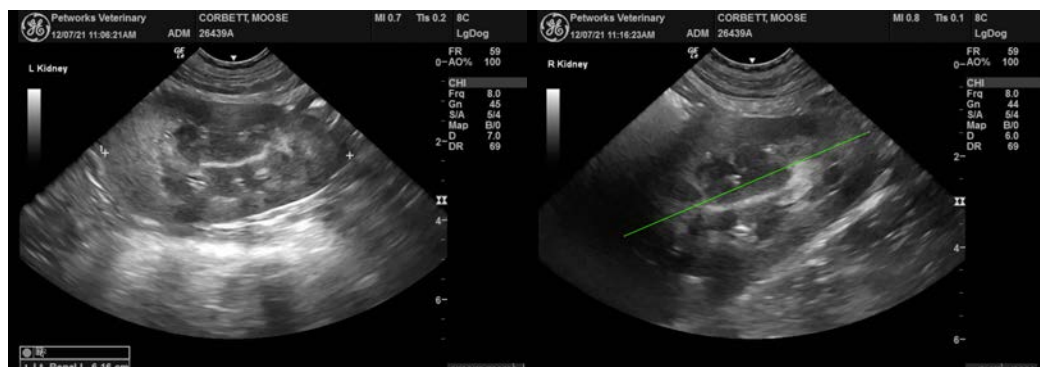
The right kidney has a normal shape and size (5.79 cm). Overall echogenicity is normal with adequate corticomedullary distinction and a typical 1:3 cortex:medulla ratio. There is no evidence of perinephric inflammation or effusion. There is no evidence of pyelectasia, nephroliths, infarcts or hydroureter. Renal vasculature is normal.

**ULTRASONOGRAPHIC FINDINGS**

- No abnormalities noted within the urinary tract

**INTERPRETATION OF THE FINDINGS & FURTHER RECOMMENDATIONS**

Many of the common features of an ectopic ureter such as pyelectasia, hydroureter, etc. are not noted on today's scan. Additionally, there is the suggestion of a ureteral jet at the level of the trigone. These findings make a large ectopic ureter unlikely, but unfortunately for smaller ectopic ureters or ureters with multiple openings, contrast CT would likely be necessary to rule out this possibility. Additionally, high resolution ultrasound with the use of color flow can pick up some of these finer abnormalities. A urinalysis and culture is an excellent plan. If incontinence persists, consider contrast CT scan.





## PATIENT

Moose Corbett

## SPECIES

Canine

## BREED

German Shepherd

## SEX

Neutered Male

## AGE

3.5 Years

## WEIGHT

45.1 kg

## INTERPRETED BY

Kathleen Sennello DVM,  
MS, Diplomate ACVIM  
(Small Animal Internal  
Medicine)

## IMAGING PERFORMED BY

Dr. Trudeau

## HOSPITAL NAME

Pet Works VH

## REFERRING VET

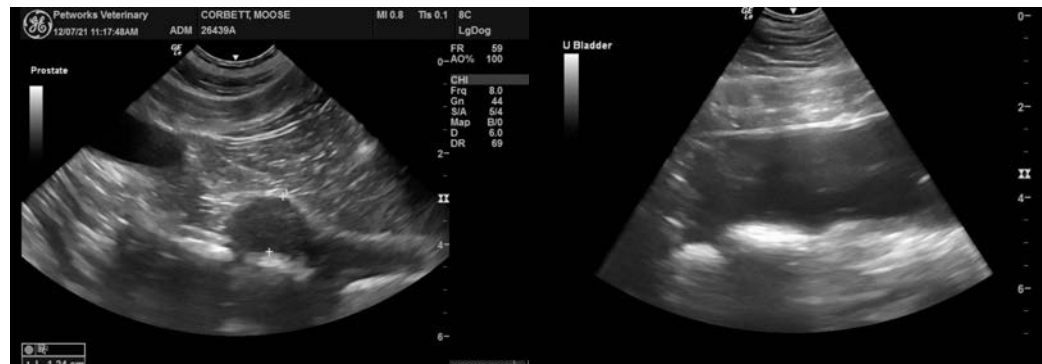
Dr. Trudeau

## INVOICE

33311

## DATE

12/7/21



The information and recommendations provided are based on the images presented by the referring veterinarian. No evaluation can be communicated regarding pathology that was not visible in the image/video clips provided.

Thank you for this referral. If the clinical or image interpretation does not parallel your findings or if I can be of any further assistance please contact me.

Kathleen Sennello DVM,MS, Diplomate ACVIM (Small animal Internal Medicine)  
kathleen.sennello@sonopath.com