

**DATE PRESENTING CLINICAL SIGNS**

12/6/22

Owner presented cat for annual examination and vaccination but raised concerns about the weight loss the cat has exhibited in face of normal appetite and no history of PU/PD, vomiting, etc. Physical examination: weight loss of 3.8 lbs over the past 16 months without any weight loss program. Minor dental disease but no obvious oral pain.

PATIENT

Murphy Cole

SPECIES

Feline

Current Medications: None listed.

Lab Results: Normal thyroid (T4) level, ALT 228 (27-158)U/L, AST 99 (16-67)U/L, Monocytes 868 (40-530)/ul

BREED

DSH

Date of Previous IntraPet Ultrasound: No previous.

Sedation: Not required to complete full diagnostic ultrasound.

Stat Report: Not requested.

SEX

Spayed Female

AGE

1/11/12

WEIGHT

9.8 Pounds

INTERPRETED BY

Kathleen Sennello DVM,
MS, Diplomate ACVIM
(Small Animal Internal
Medicine)

ULTRASONOGRAPHIC EXAMINATION OF THE ABDOMEN**Urinary System**

The urinary bladder is moderately distended with mild primarily suspended echogenic debris present. The Bladder wall, trigone, ureteral papillae and visible urethra (to a depth of 2cm) appear normal with no evidence of wall thickening, mucosal irregularities, masses or calculi. Echogenic debris of this type can be associated with small crystals, cellular debris and proteinaceous debris.

The left kidney has a normal shape and size (3.42 cm). Overall echogenicity is normal with adequate corticomedullary distinction and a typical 1:3 cortex:medulla ratio. There is no evidence of focal perinephric inflammation or effusion. There is no evidence of pyelectasia, nephroliths, infarcts or hydroureter. Renal vasculature is normal.

The right kidney has a normal shape and size (3.92 cm). Overall echogenicity is normal with adequate corticomedullary distinction and a typical 1:3 cortex:medulla ratio. There is no evidence of focal perinephric inflammation or effusion. There is no evidence of pyelectasia, nephroliths, infarcts or hydroureter. Renal vasculature is normal.

Adrenal Glands

The left adrenal gland is normal in size measuring 0.41 cm at the caudal pole. It is observed in its normal position cranial to the left renal artery. It is normal in appearance (uniformly hypoechoic) and shape with no evidence of a mass effect.

The right adrenal gland is normal in size measuring 0.37 cm at the caudal pole. It is observed in its normal position between the cranial aspect of the right kidney and the caudal vena cava. It is normal in appearance (uniformly hypoechoic) and shape with no evidence of a mass effect.

Spleen

The spleen is subjectively normal in size (0.86 cm in width at the level of the hilus), echotexture is homogenous, and the splenic capsule is smooth with no irregularities. The blood flow through the hilus and splenic parenchyma appears normal. No focal parenchymal abnormalities are visualized.

Liver

The liver is subjectively normal in size, and echogenicity with smooth peripheral margins. The parenchyma is homogenous echotexture. The visible portions of the vasculature and biliary tract appear normal. No focal nodules or cystic lesions are observed.

IMAGING PERFORMED BY

Stephanie Warga
RDMS, RVT

HOSPITAL NAME

Fork Vet Hospital

REFERRING VET

Dr. Doherty

INVOICE

43226

The gallbladder lumen is moderately distended. The wall of the gall bladder is not thickened and has a smooth mucosal surface. Luminal contents are mild and primarily anechoic. The cystic and common bile ducts are normal/not visible.

Gastrointestinal

The stomach contains minimal luminal contents. It measures at a normal thickness of <0.36cm with some variability due to the presence of rugal folds. The distinction of the gastric wall layers is adequate and there is no impression of reduced peristaltic activity. No masses or focal lesions were observed.

The visualized areas of duodenum, jejunum and ileum have a uniform diameter with minimal fluid distension. Wall thickness is normal to slightly increased. Bowel loops follow a typical curvilinear path with distinct wall layering, but some areas display a prominent muscularis layer which does not display the typical 1:3 muscularis:mucosa layer ratio. Duodenum wall measures 0.30 cm. Jejunum wall measures 0.29 cm. Visualized peristalsis appears appropriate. There is a focal section of bowel in the mid abdomen that appears thickened, irregular/asymmetrical, with a complete loss of layering. In this region, the abnormal bowel wall measures at 0.64 cm. In some areas this irregularity forms a mass-like structure measuring 1.1 cm x 1.48 cm. The abnormal bowel extends for >4.0 cm of small intestine and is surrounded by hyperechoic mesentery and abnormal lymph nodes.

The ileocecal junction was visualized and exhibited normal intact wall layering and is subjectively of normal thickness. Sections of colon are visualized with formed fecal material and gas shadowing distally. There is no observed focal or generalized colon wall thickening or loss of layering.

Pancreas

The pancreas is normal and isoechoic to surrounding mesentery. There is no evidence of nodules or cystic lesions. There is no evidence of regional mesenteric inflammation or fluid.

Free Abdomen

Evaluation of the peritoneal cavity did not reveal any evidence of effusion. There is a significant mesenteric lymphadenopathy with mesenteric lymph nodes measuring 0.68 cm and 0.93 cm, particularly surrounding the abnormal bowel. The omentum is hyperechoic around the lymph nodes and abnormal bowel.

ULTRASONOGRAPHIC FINDINGS

- Focal area of small intestine with irregular wall thickening and complete loss of layering, creating a mass effect in some areas – Findings are very concerning for possible round cell neoplasia, although other differentials exist.
- Echogenic debris in the urinary bladder – The echogenic debris in the bladder lumen could be consistent with cells, crystals, and/or mucus.
- Significant lymphadenopathy in the region around the abnormal bowel at the mid abdomen – Differentials include neoplasia, inflammation, and infection.

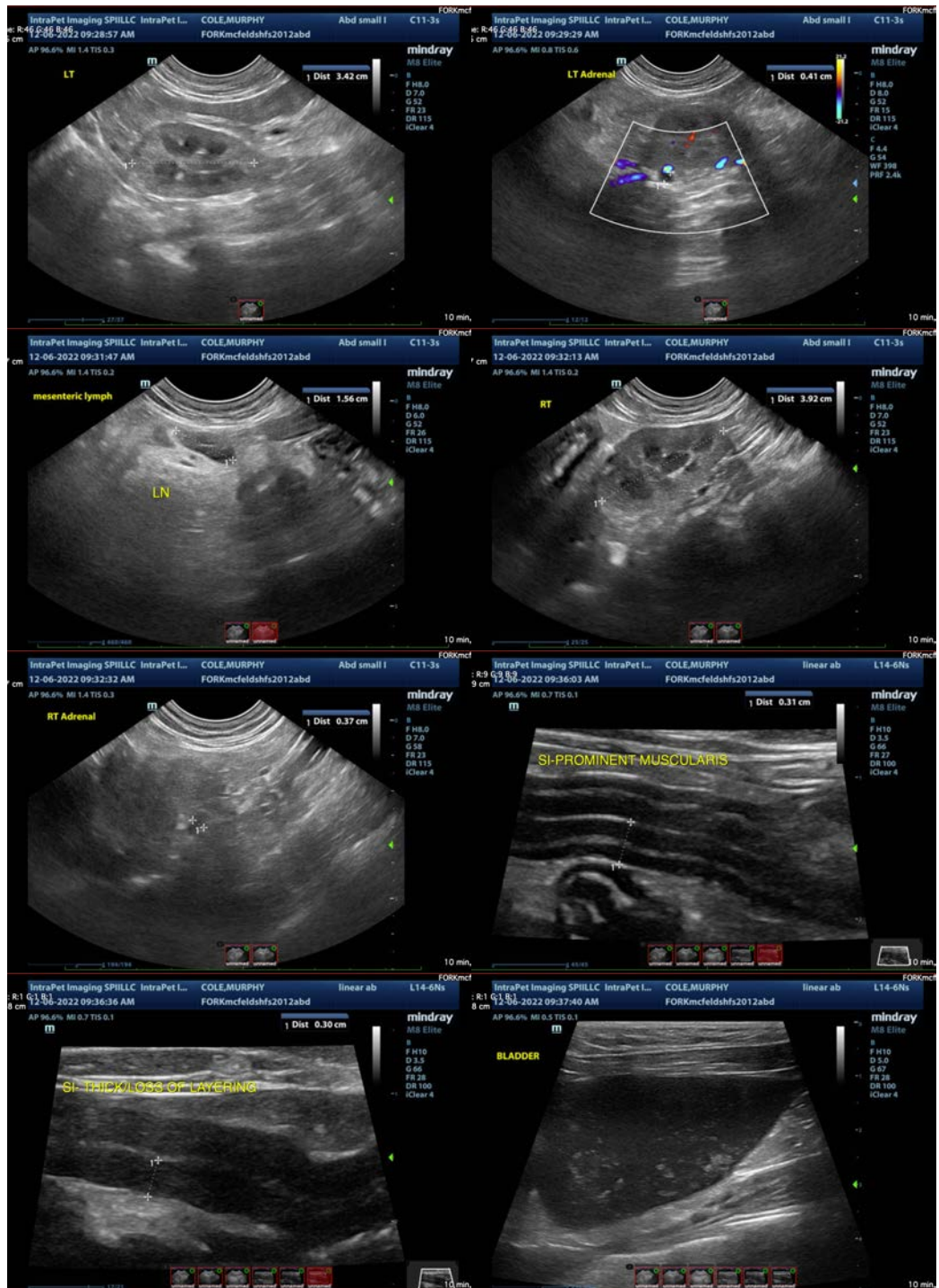
INTERPRETATION OF THE FINDINGS & FURTHER RECOMMENDATIONS

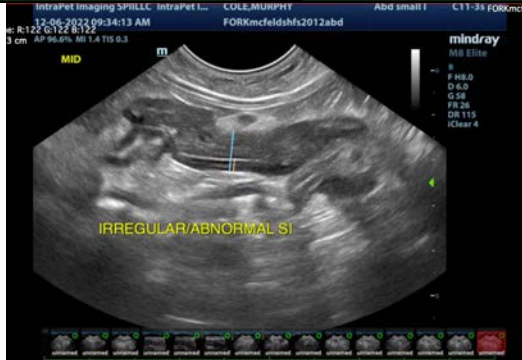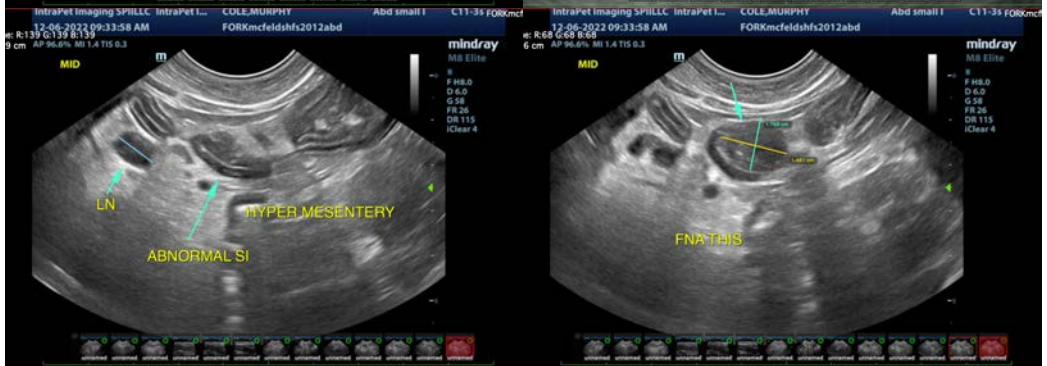
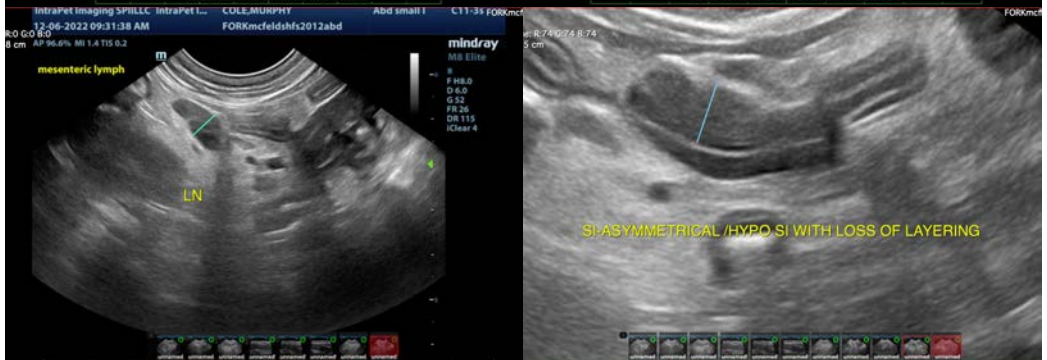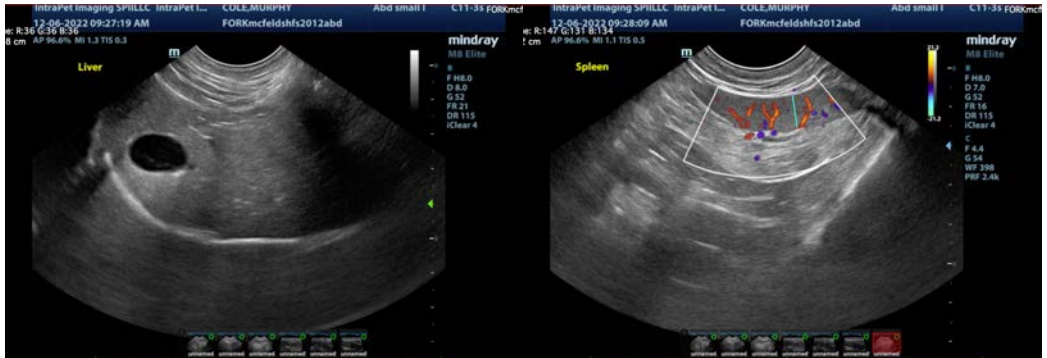
There is an extensive section of small bowel in the mid abdomen that appears thickened and irregular with hypoechoic wall and complete loss of layering. This thickening creates mass lesions in some areas. These findings are very concerning for possible round cell neoplasia in this abnormal section of bowel surrounded by enlarged, hypoechoic, rounded lymph nodes and hyperechoic mesentery.

Recommend a fine needle aspirate of the abnormal bowel wall (see images) and a mesenteric lymph node. Additionally, recommend 3-view thoracic radiographs. If a cytologic diagnosis cannot be obtained based on

cytologic analysis, recommend surgical biopsies.

Additionally, I would consider a GI panel to Texas A&M for a qualitative fPLI, TLI, cobalamin and folate, as many of these patients have concurrent cobalamin deficiencies, dysbiosis, etc.





The information and recommendations provided are based on the images presented by the referring veterinarian/sonographer. No evaluation can be communicated regarding pathology that was not visible in the image/video clips provided.

Thank you for this referral. If the clinical or image interpretation does not parallel your findings or if I can be of any further assistance please contact me.

Kathleen Sennello DVM,MS, Diplomate ACVIM (Small animal Internal Medicine)
kathleen.sennello@sonopath.com