



## PATIENT

Lacy Bittner

## SPECIES

Canine

## BREED

Golden Retriever

## SEX

FA

## AGE

9 years

## WEIGHT

32.3 kg

## INTERPRETED BY

Kathleen Sennello DVM,  
MS, Diplomate ACVIM  
(Small Animal Internal  
Medicine)

## IMAGING PERFORMED BY

Dr. Sarah Barthelemy

## HOSPITAL NAME

Britannia Kingsland Vet  
Clinic

## REFERRING VET

Dr. Matheson

## INVOICE

10860

## DATE

12/4/2025

## PRESENTING CLINICAL SIGNS

Presenting with lethargy and hyporexia. Jaundice on exam.

Abnormal PE/Chem/CBC/UA Results: Marked elevated ALT (1500), ALP 2000, mild GGT elevation, mild lipase elevation. Tbili not reading.

## ULTRASONOGRAPHIC EXAMINATION OF THE ABDOMEN

### Urinary System

The urinary bladder is moderately distended with anechoic urine. The Bladder wall, trigone, ureteral papillae and visible urethra (to a depth of 2cm) appear normal with no evidence of wall thickening, mucosal irregularities, masses or cystic calculi.

The left kidney has a normal shape and size (7.04 cm). Overall echogenicity is normal with adequate corticomedullary distinction and a typical 1:3 cortex:medulla ratio. There is no evidence of focal perinephric inflammation or effusion. There is no evidence of pyelectasia, nephroliths, infarcts or hydroureter. Renal vasculature is normal.

The right kidney has a normal shape and size (7.39 cm). Overall echogenicity is normal with adequate corticomedullary distinction and a typical 1:3 cortex:medulla ratio. There is no evidence of focal perinephric inflammation or effusion. There is no evidence of pyelectasia, nephroliths, infarcts or hydroureter. Renal vasculature is normal.

### Adrenal Glands

The left adrenal gland is normal in size measuring 0.42 cm at the cranial pole and 0.66 cm at the caudal pole. It is observed in its normal position cranial to the left renal artery. It is normal in appearance (uniformly hypoechoic) and shape with no evidence of a mass effect.

The right adrenal gland is normal in size measuring 0.39 cm at the cranial pole and 0.51 cm at the caudal pole. It is observed in its normal position between the cranial aspect of the right kidney and the caudal vena cava. It is normal in appearance (uniformly hypoechoic) and shape with no evidence of a mass effect.

### Spleen

The spleen is subjectively normal in size (3.17 cm) and the echotexture is homogenous. The splenic capsule is smooth with no visible irregularities. The blood flow through the hilus and splenic parenchyma appears normal. No focal parenchymal abnormalities are visualized.

### Liver

The liver is subjectively normal in size, and echogenicity with smooth peripheral margins. The parenchyma is homogenous echotexture. The visible portions of the vasculature and biliary tract appear normal. No focal nodules or cystic lesions are observed.

The gall bladder lumen is significantly distended with anechoic material. The bile duct is not clearly visualized. On some views the wall appears mildly thickened at .36cm.

### Gastrointestinal



## PATIENT

Lacy Bittner

## SPECIES

Canine

## BREED

Golden Retriever

## SEX

FA

## AGE

9 years

## WEIGHT

32.3 kg

## INTERPRETED BY

Kathleen Sennello DVM,  
MS, Diplomate ACVIM  
(Small Animal Internal  
Medicine)

## IMAGING PERFORMED BY

Dr. Sarah Barthelemy

## HOSPITAL NAME

Britannia Kingsland Vet  
Clinic

## REFERRING VET

Dr. Matheson

## INVOICE

10860

## DATE

12/4/2025

The stomach contains moderate fluid. It measures at a normal thickness of <0.7cm with some variability due to the presence of rugal folds. The distinction of the gastric wall layers is adequate and there is no impression of reduced peristaltic activity. No masses or focal lesions were observed.

The visualized areas of duodenum, jejunum and ileum have a relatively uniform diameter with minimal fluid distension. Wall thickness is normal. Bowel loops follow a curvilinear path with distinct wall layering maintaining the typical 1:3 muscularis:mucosa layer ratio. The duodenum measured as normal (0.43 cm in wall thickness) and the jejunum measured as normal (0.34 cm.) Visualized peristalsis appears appropriate. There's mild mucosal speckling visualized associated with some sections of small intestine, and the duodenum is fluid distended.

Sections of colon are visualized with formed fecal material and gas shadowing distally. There is no observed focal or generalized colon wall thickening or loss of layering.

### **Pancreas**

The pancreas is visible/mildly mottled in the right limb. There is no evidence of nodules or cystic lesions. There is no evidence of regional mesenteric inflammation or fluid.

### **Free Abdomen**

Evaluation of the peritoneal cavity did not reveal any evidence of effusion, or subjective lymphadenomegaly. The Medial iliac nodes appear normal and there was no evidence of a caudal aortic thrombus at the bifurcation. The omentum is of normal uniform echogenicity.

## ULTRASONOGRAPHIC FINDINGS

- Pancreatic changes consistent with chronic pancreatic remodeling.
- Mild/moderate fluid distension of the stomach and duodenum. Correlate with the feeding history. This could represent ileus or a non-fasted patient.
- Mild mucosal speckling visualized associated with the small intestine. Bright mucosal speckling has been postulated to represent dilated lacteals or focal accumulations of mucus, cellular debris, etc.. in the mucosal crypts.
- Distended gall bladder with a mildly prominent wall-findings could be seen with mild cholecystitis.

## INTERPRETATION OF THE FINDINGS & FURTHER RECOMMENDATIONS

The liver appears relatively normal. No focal lesions are observed. The gallbladder is moderately distended with a slightly prominent wall. The bile duct is not clearly visualized. This can be normal in some individuals, although, I cannot rule out an obstructive process. If the bilirubin continues to rise, consider repeat evaluation looking for progressive distension. Mild wall thickening could be due to mild cholecystitis.

At this time a primary hepatopathy would be most likely. Differentials such as toxic ingestion, infectious disease, etc., can have minimal changes. Recommend treatment for acute liver injury with ursodiol, denamarin, and antibiotics, and screening for leptospirosis (this would also address cholecystitis). If liver values continue to rise, consider repeat imaging (bile duct, liver, gb) as a biopsy of the liver with samples for histopathology, culture, and copper levels may be warranted.



**PATIENT**

Lacy Bittner

**SPECIES**

Canine

**BREED**

Golden Retriever

**SEX**

FA

**AGE**

9 years

**WEIGHT**

32.3 kg

**INTERPRETED BY**

Kathleen Sennello DVM,  
MS, Diplomate ACVIM  
(Small Animal Internal  
Medicine)

**IMAGING  
PERFORMED BY**

Dr. Sarah Barthelemy

**HOSPITAL NAME**

Britannia Kingsland Vet  
Clinic

**REFERRING VET**

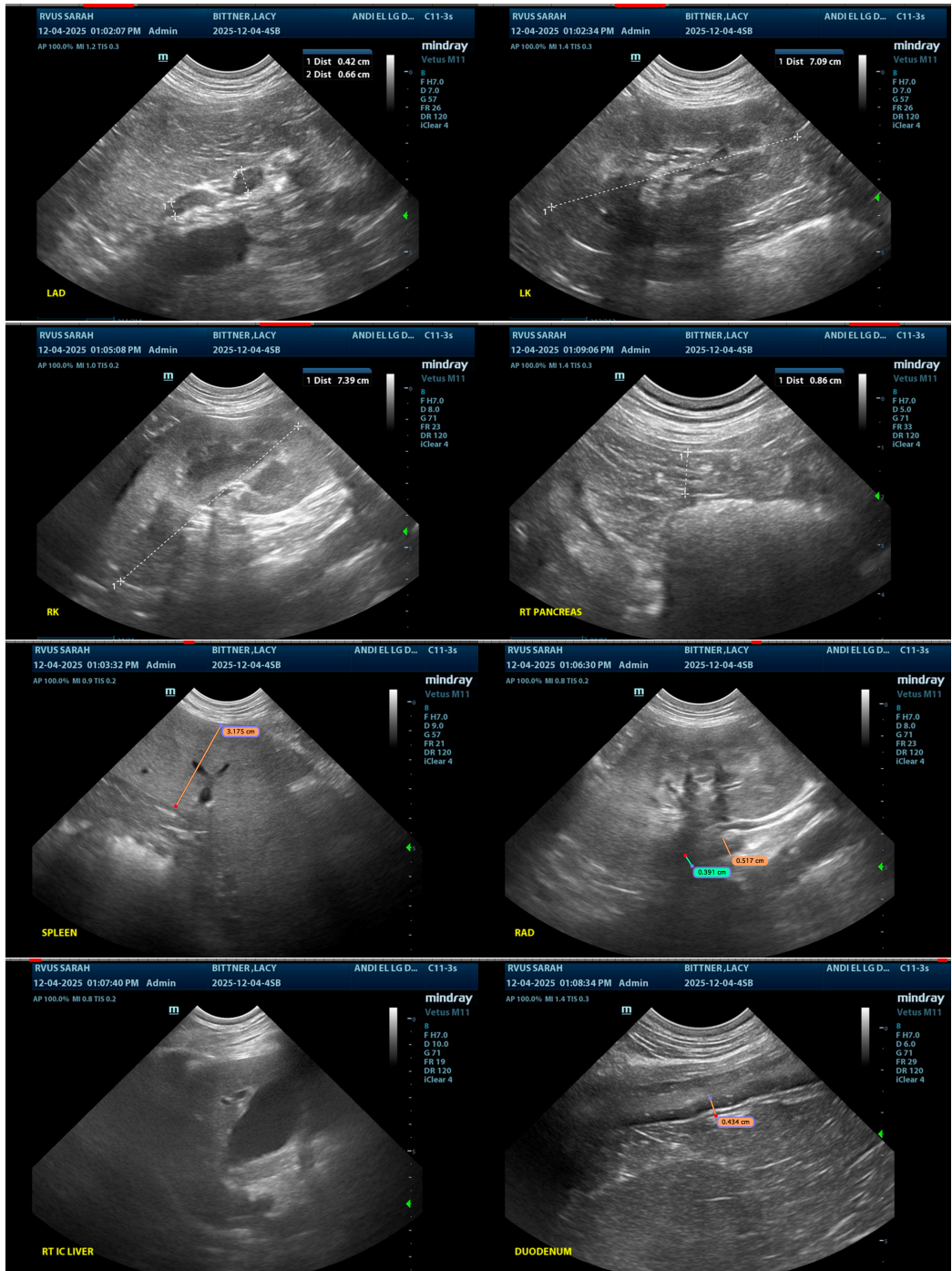
Dr. Matheson

**INVOICE**

10860

**DATE**

12/4/2025





#### PATIENT

Lacy Bittner

#### SPECIES

Canine

#### BREED

Golden Retriever

#### SEX

FA

#### AGE

9 years

#### WEIGHT

32.3 kg

#### INTERPRETED BY

Kathleen Sennello DVM,  
MS, Diplomate ACVIM  
(Small Animal Internal  
Medicine)

#### IMAGING PERFORMED BY

Dr. Sarah Barthelemy

#### HOSPITAL NAME

Britannia Kingsland Vet  
Clinic

#### REFERRING VET

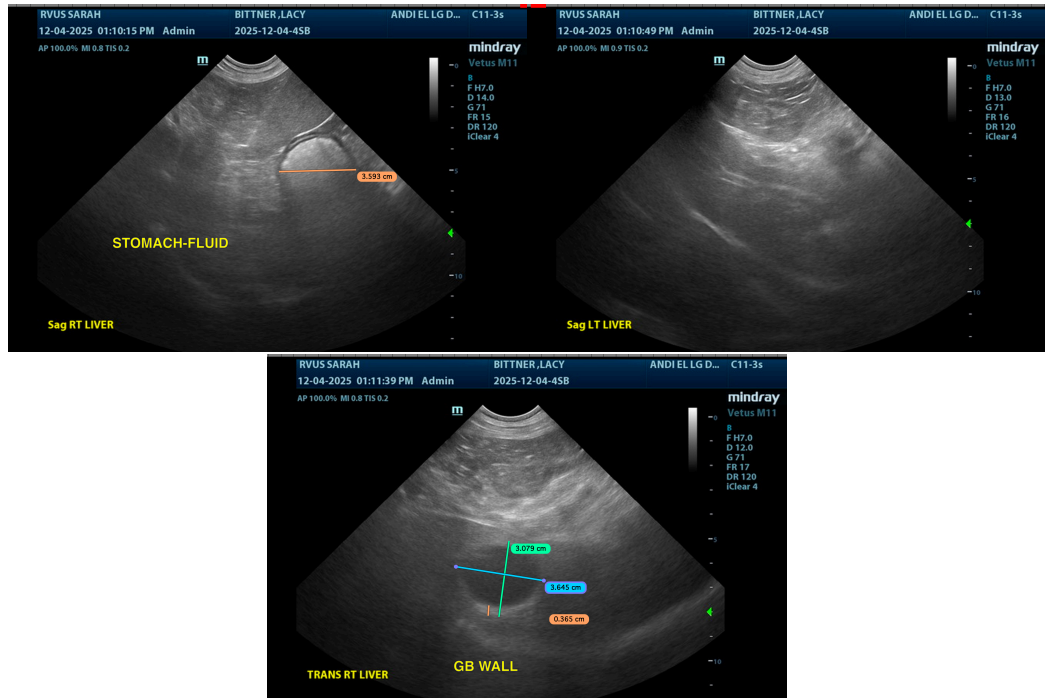
Dr. Matheson

#### INVOICE

10860

#### DATE

12/4/2025



The information and recommendations provided are based on the images presented by the referring veterinarian/sonographer. No evaluation can be communicated regarding pathology that was not visible in the image/video clips provided.

Thank you for this referral. If the clinical or image interpretation does not parallel your findings or if I can be of any further assistance please contact me.

Kathleen Sennello DVM,MS, Diplomate ACVIM (Small animal Internal Medicine)

[info@sonopath.com](mailto:info@sonopath.com)